

Case Report

Giant Placental Chorangioma- a Rare Entity

Namrata Rao, Suman K

Assistant Professor, Department of Pathology, Melaka Manipal Medical College, Manipal Academy of Higher Education, Manipal

Corresponding Author: Suman K

ABSTRACT

A 33 year old second gravida presented with decreased fetal movements and pain abdomen. The placenta was sent for histopathological examination, following a spontaneous vaginal delivery. Placenta showed a grey brown nodule which on microscopy showed a complex network of vascular channels favouring a diagnosis of chorangioma. Chorangiomas are rare tumours associated with adverse fetal outcomes; hence they are important entities to diagnose.

Keywords: chorangioma, giant, vascular, placenta

INTRODUCTION

Chorangiomas are non trophoblastic tumours of the placenta which account for 1% of the tumours. ⁽¹⁾ These are rare tumours which are usually associated with increase in maternal age, diabetes and hypertension. ⁽²⁾ Giant chorangiomas, greater than 5cms in diameter can cause adverse fetal outcomes.

CASE REPORT

A 33 year old pregnant lady, second gravida presented at 39 weeks of gestation with decreased fetal movements and pain abdomen. She was on thyroxine for hypothyroidism. She underwent spontaneous vaginal delivery and a healthy baby was delivered. The placenta was sent for histopathological examination. The placenta with umbilical cord weighed 551 grams and measured 17x16x10cms. Cut section showed a well circumscribed grey brown nodule measuring 5.5x4x3.5 cms. Sections were submitted from the nodule, normal areas of placenta, membranes and

umbilical cord. Microscopy from the grey brown nodule showed a complex network of numerous capillary sized blood vessels supported by loose stroma favouring a diagnosis of chorangioma (Fig 1 and Fig 2). There was no mitosis, pleomorphism or necrosis. Sections from the normal areas of placenta, membrane and cord showed normal histology.

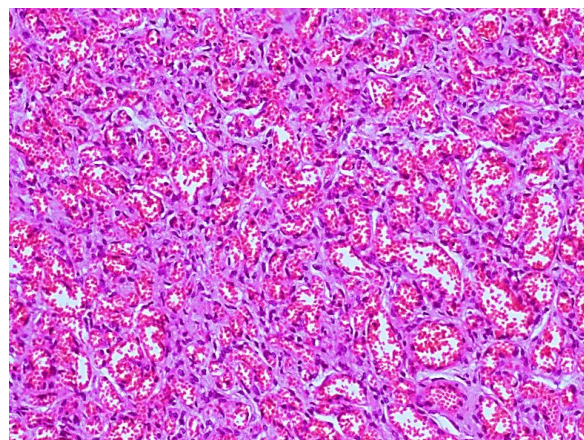


Fig 1: Image showing complex network of vascular channels (H&E, 10x)

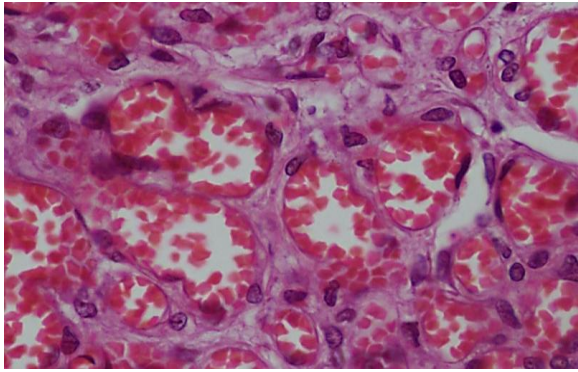


Fig 2: Image showing capillary sized blood vessels (H&E, 40x)

DISCUSSION

The placenta is one of the few organs which is not sent for routine histopathological examination. The importance of studying the placenta cannot be overemphasized. Careful examination of the placenta can provide answers to various fetal and maternal complications encountered in the antenatal period. Chorangiomas are tumours which are incidentally detected during histopathological examination of the placenta or in placentas sent for histopathology as a result of complications caused during pregnancy. Chorangiomas are also called as placental haemangiomas which arise from primitive chorionic mesenchyme. ⁽³⁾ These are due to malformations of the vascular channels in the placenta. Small ones are asymptomatic and may be missed on routine histopathological examination. Diagnosis required close sectioning of placenta to avoid missing out on small lesions. Larger ones can be associated with complications in pregnancy and adverse fetal outcomes like growth restriction, polyhydramnios, hydrops and fetal death. ⁽⁴⁾ Chorangiomas are benign tumours which are non capsulated but well circumscribed. Ultrasonography aids in diagnosis in the antenatal period. Chorangiomas are haemorrhagic due to the presence of

vascular channels. On microscopy three types have been identified namely cellular, angiomatous and degenerate out of which the angiomatous is most common as in our case. Chorangiomas and chorangiosis are the differential diagnosis for chorangioma, however these present with diffuse or focal proliferation of villous angioblastema. The angiomatous type has plenty of blood vessels, the cellular type has immature and cellular elements and the degenerate type is associated with degenerative changes such as necrosis, calcification. ⁽⁵⁾

In the above case a 33 year old lady presented with decreased fetal movements and examination of the placenta following vaginal delivery revealed a giant chorangioma.

CONCLUSION

Chorangiomas are rare tumours which can be associated with maternal and fetal complications hence identifying these tumours are of utmost importance.

REFERENCES

1. Wallenburg HCS. Chorangioma of the placenta: thirteen new cases and a review of the literature from 1939 to 1970 with special reference to clinical complications. *Obstet and Gynecol Survey*. 1971;26:411–25.
2. Lež C, Fures R, Hrgovic Z, Belina S, Fajdic J, Münstedt K. Chorangioma placentae. *Rare Tumors*. 2010;2(4):e67
3. Kataria N, Singh A, Bedi PK. Giant Placental Chorangioma: A Rare Case Report. *J Clin Diagn Res*. 2016;10(4):ED03–ED4.
4. Lifschitz-Mercer B, Fogel M, Kushnir I, Czernobilsky B. Chorangioma. A cytoskeletal profile. *Int J Gynecol Pathol*. 1989;8:349–56.,
5. Marchetti AA. A consideration of certain types of benign tumors of the placenta. *Surg Gynecol Obstet* 1939;68:733-43

How to cite this article: Rao N, Suman K. Giant placental chorangioma- a rare entity. *Int J Health Sci Res*. 2019; 9(9):240-241.
