

Efficacy of Magnetic Resonance Imaging over Ultrasound in the Diagnosis of Placental Invasion

Dr. Chetana R. Ratnaparkhi¹, Dr. Sidharth Sharma², Dr. Avinash P. Dhok³,
Dr. Madhuri S. Gawande⁴, Dr. Shital A. Kurve⁵, Dr. Sarika H. Kohar⁵

¹Associate Professor, ²Post-graduate Resident, ³Professor and Head of Department, ⁵Senior Resident,
Department of Radio-diagnosis, NKP Salve Institute of Medical Sciences and Lata Mangeshkar Hospital,
Digidoh Hills, Nagpur, Maharashtra, India.

⁴Consultant Gynecologist, American Oncology Institute, Nagpur, Maharashtra, India.

Corresponding Author: Dr. Sidharth Sharma

ABSTRACT

Incidence of placental invasion is on rise due to increasing number of caesarean sections. Identification of placental invasion is important to reduce maternal morbidity and mortality. For preoperative assessment of placental invasion, ultrasonography (USG) is the primary imaging modality. Due to its excellent soft tissue resolution and multiplanar imaging, magnetic resonance imaging (MRI) is becoming the modality of choice in placental invasion, particularly where sonographic findings are indistinct. In the current study, we evaluate the usefulness of USG and MRI in diagnosis of placental invasion.

Materials and Methods -Eleven patients of suspected placental invasion were included in the study. Out of eleven, nine were antenatal and two were in postnatal period with retained placenta. All patients were multigravida with previous history of uterine interventions (maximum with previous caesarean section n=9). They were subjected to USG and MRI pelvis examination after acquiring proper written consent. On the basis of imaging placental invasion was classified into placenta accreta, placenta increta and placenta percreta.

Results- On USG, eight patients were labelled as having placenta accreta, one as placenta increta and two as placenta percreta; however the patients diagnosed as placenta percreta on USG turned out to be placenta increta which was confirmed on intraoperative findings. On MRI, placenta accreta was seen in eight patients. This is likely to be attributed to better soft tissue resolution of MRI.

Conclusion- For placental invasion USG is the primary imaging modality, however MRI plays important role in accurately classifying invasion thus helps in management.

Keywords- Placental Invasion, Ultrasonography, Magnetic Resonance Imaging

INTRODUCTION

Placenta plays an important role throughout the pregnancy. During routine obstetric scanning, site, thickness and morphology of the placenta is commented. Many pathologic conditions affect placenta viz. placenta previa, abruptio- placentae, gestational trophoblastic disease, benign cystic lesions, placental invasion, non-

trophoblastic placental tumours and metastasis. ⁽¹⁾

Of these, placental invasion is one of the dreaded conditions resulting in significant mortality and morbidity. Incidence of placenta Accreta has increased many times in past 30 years. ⁽²⁾ Most of them attribute this to increasing number of caesarean sections. ^(3,4) Proper assessment and documentation of these abnormalities is

crucial as it affects the management and final outcome. For this, imaging plays a vital role. Imaging criteria for placental invasion includes placenta previa, placental lacunae, loss of the retroplacental clear space, and myometrial thinning, irregular bladder wallet. (5,6)

For placental invasion, ultrasonography (USG) acts as a primary screening technique as it is easily available and routinely done in obstetric patients. During obstetric scanning if low-lying placenta or placenta previa has been encountered in female with previous cesarean delivery, a meticulous evaluation of placenta for probable invasion should be done and interval follow-up is mandatory for confirmation or ruling out of placental invasion. (7)

Magnetic resonance Imaging (MRI) for placental evaluation is done frequently in cases of doubtful USG findings and it can act as problem solving in most of the situations. MRI helps in localization of site of invasion and categorizing it into placenta accreta, placenta incerta and placenta percreta. This is very useful from patient management point of view. In this article we try to evaluate the MRI and USG criteria for diagnosing placental invasion and usefulness of these imaging techniques in preoperative assessment of patient with suspected placental invasion.

MATERIALS AND METHODS

Informed consent was obtained from all patients who were part of this study. Form F (mandatory to fill according to Preconception and Pre natal diagnostic act i.e. PC/PNDT) was filled in all antenatal patients. The study was approved by the Institutional ethics committee.

The cases were prospectively reviewed from our MRI database that underwent pelvic MRI at our institution between January 2016 to December 2018 for suspected placental invasion. Total 11 patients were identified.

The age of patients who underwent imaging ranged from 21 to 33 years with mean age of 28 years.

All these patients were multigravida. Gestational age range between 21wks to 35wks in antenatal patients (n=9) with mean gestational age 24 wks. Two patients were in postnatal status with retained placenta for four and two days. All females gave history of previous operative intervention in the form of lower segment caesarean section (LSCS)(n=9) or medical termination of pregnancy(n=2).

The chief complaints with which these patients presented were pain in lower abdomen (n=11) and bleeding per vaginum (n=9). Five patients were diagnosed with Grade IV placenta previa during the routine antenatal scan in third trimester. All these patients were suspected of having abnormal placental invasion.

USG was done in all patients using MyLab 50 Esaote and Samsung RS 80 machines with curvilinear (3.5-5 MHz) array transducer. Color Doppler was done wherever needed.

Antenatal ultrasound was not done in two patients.

Ultrasound criteria used for diagnosing adherent placenta includes-

1. Loss of the normal retroplacental clear space.
2. Significant thinning/interruption of the hyperechoic uterine wall to bladder interface.
3. Intraplacental lacunae.

MRI was performed on 1.5 HD XT 16 channel 1.5T GE MRI machine using body coil. Urinary bladder was partly full during the study.

Scan was done in supine position and patients tolerated this position well. They were instructed to inform any discomfort during the scan.

Dedicated pelvic MRI sequences were done using following sequences:

T1WI (TR -634, TE-10); (T-5mm, L-70.6mm), T2WI(TR-5225, TE-89.3); (T-3mm, L 56.4mm), STIR (TR-7400, TE-49);

(T-7, L- 52.4), AXIAL 2D FIESTA FS BH (TR-3.9, TE-1.7) ; (T-9, L-107), COR 2D FS FIESTA (TR-4.1, TE- 1.8);(T-6, L-42.4) . Respiratory gating was done to avoid breathing artefact.

Images are acquired in all the three planes viz. axial, coronal and sagittal with respect to uterus with special emphasis on myometrial –placental interface.

Scan time ranges between 20 to 30 minutes. MRI contrast study was not done in any of the patients. All the patients cooperated well for MRI study.

MRI criteria for placental invasion includes-

1. Focal uterine bulge
2. Heterogeneous signal intensity within the placenta
3. Dark intraplacental bands on T2-weighted images
4. Focal defect/gap in the myometrium
5. Urinary bladder tenting

Laboratory investigations of these patients which included hormonal assay (beta HCG, TSH) and electrolyte assessment were within normal limit. All these patients were hemodynamically stable.

RESULTS

USG and MRI pelvis of all the 11 patients were evaluated.

Ultrasound findings are enumerated in table no. 1

Table No 1.

USG Findings	Number of patients
Bulky uterus	11
Placenta previa(grade IV)	5
Retained placenta	2
Free fluid in pelvis	9
Significant thinning of myometrium	11
Placenta Accreta	8
Placenta Increta	1
Intrauterine Fetal demise	1
Oligohydramnios	1

All patients showed bulky uterus. Grade IV placenta previa was seen in five patients, out of which two were suspected of having placenta Accreta, two having Placenta Percreta with probable bladder invasion and one with placenta Increta (Figure 1).

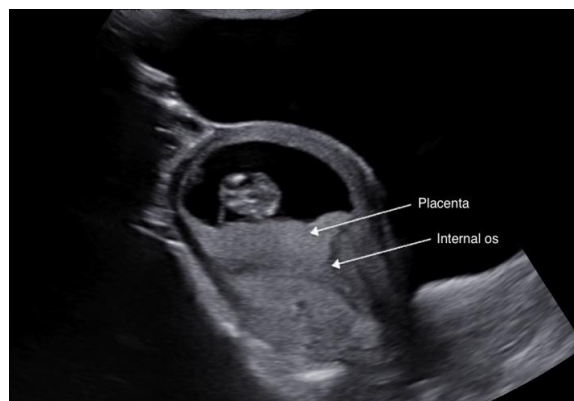


Figure 1- USG shows Grade IV Placenta Previa. Placenta is completely covering the internal os.

Reduction in myometrial thickness is seen in all the patients. Loss of retroplacental clear space was seen in six patients. Large placental lacunae were seen in three patients on antenatal ultrasound scan.

Two patients came with h/o retained placenta and on USG showed placental tissue with probable myometrial invasion.

On USG, eight patients were suspected of placenta Accreta, two having Placenta Percreta with probable bladder invasion and one with placenta Increta.

Other ultrasound findings includes- Intrauterine fetal demise with fetal ascites and pleural effusion in one patient, free fluid in pelvis in nine patients and oligohydramnios in one patient, Bilobed/succenturiate lobe in one patient. The various MRI findings are as detailed in Table 2.

Table No 2.

MRI pelvis findings	Number of patients
Placenta previa	5
Placenta Accreta	8
Placenta Increta	3
Retained placenta	2
Multiple fibroids	1
Ectopic caesarean scar	1
Bulky uterus	11
Oligohydramnios	1

Bulky uterus was seen in all patients as seen in on USG. Placenta previa grade IV was seen in 5 patients. Retained placenta was seen in 2 patients. Ectopic caesarean scar with hemorrhagic collection in placenta was noted in one patient. Large placental lacunae were seen in one patient.

On MRI, placental invasion was seen in all the 11 patients. Out of 11 patients, 8 had placenta Accreta and 3 had placenta Increta. Patients those were suspected of having placenta Percreta on USG were labelled as placenta Increta.

Table 3: shows MRI criteria for placental invasion

MRI features of invasion	No. of patients	Sensitivity
Uterine bulge/placental lump	10	90%
Abnormal signal in placenta	5	45%
Dark intraplacental bands on T2 image	4	36%
Thinning of myometrium	10	90%
Myometrial disruption	9	81%

Uterine bulge/ placental lump and thinning of myometrium were seen in maximum patients i.e. 10 out of 11 patients followed by Myometrial disruption seen in 9 out of 11 patients (Figure 2).

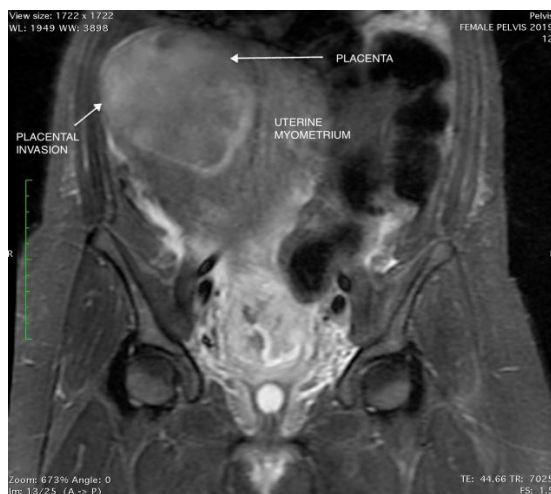

Figure 2- Coronal T2 image shows a well-defined, hyper intense lesion the fundal and right lateral region of uterus communicating with the endometrial cavity. There is loss of normal myometrial signal at fundus and along the right lateral wall between placenta and myometrium with focal bulge which suggests placental invasion.

Other signs viz. abnormal signal in placenta and dark intraplacental bands on

T2 weighted (Figure 3) images were seen in 5 and 4 patients respectively. Signs like uterine bulge /placental lump, thinning of placenta and Myometrial disruption seem to be more sensitive for labelling placental invasion on MRI. Bladder tenting (one of the sign of placental invasion i.e. placenta percreta) was not seen in any patient. None of the patient showed invasion of adjacent organ viz. bladder or rectum.

Operative interventions were done in all these patients and intraoperative findings were consistent with MRI findings.

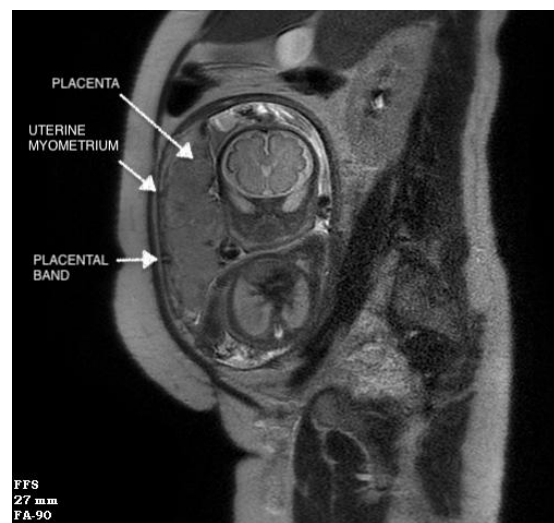


Figure 3. Sagittal T2 image shows a linear hypointense placental band along the anterior surface at myometrial placental interface. Placenta appears homogenous with no focal interruption in the myometrial wall.

Table 4 shows comparison between ultrasound findings and MRI findings of placental invasion.

TYPE OF INVASION	USG	MRI	POST-OP
PLACENTAACCRETA	8	8	8
PLACENTAINCRETA	1	3	3
PLACENTAPERCRETA	2	0	0
TOTAL	11	11	11

Statistical Analysis was done using Open Epi, Version 3.03, 2014.

Table 5 shows MRI of placenta Accreta SINGLE TABLE ANALYSIS:-

PARAMETER	ESTIMATE	LOWER-UPPER 95% CIs	METHOD
SENSITIVITY	100%	(67.56, 100 ¹)	WILSON SCORE
SPECIFICITY	100%	(43.85, 100 ¹)	WILSON SCORE
POSITIVE PREDICTIVE VALUE	100%	(67.56, 100 ¹)	WILSON SCORE
NEGATIVE PREDICTIVE VALUE	100%	(43.85, 100 ¹)	WILSON SCORE
DIAGNOSTIC ACCURACY	100%	(74.12, 100 ¹)	WILSON SCORE
P VALUE	1		

CI- confidence interval

Table 6 shows MRI of placenta Increta SINGLE TABLE ANALYSIS:

PARAMETER	ESTIMATE	LOWER-UPPER 95% CIs	METHOD
SENSITIVITY	100%	(43.85, 100 ¹)	WILSON SCORE
SPECIFICITY	100%	(67.56, 100 ¹)	WILSON SCORE
POSITIVE PREDICTIVE VALUE	100%	(43.85, 100 ¹)	WILSON SCORE
NEGATIVE PREDICTIVE VALUE	100%	(67.56, 100 ¹)	WILSON SCORE
DIAGNOSTIC ACCURACY	100%	(74.12, 100 ¹)	WILSON SCORE
P VALUE	1		

CI- confidence interval

Table 7 shows MRI of placenta Percreta SINGLE TABLE ANALYSIS:

PARAMETER	ESTIMATE	LOWER-UPPER 95% CIs	METHOD
SENSITIVITY	-	-	WILSON SCORE
SPECIFICITY	81.82%	(52.3, 94.86 ¹)	WILSON SCORE
POSITIVE PREDICTIVE VALUE	0 %	(0.0, 65.76 ¹)	WILSON SCORE
NEGATIVE PREDICTIVE VALUE	100%	(70.08, 100 ¹)	WILSON SCORE
DIAGNOSTIC ACCURACY	81.82%	(52.3, 94.86 ¹)	WILSON SCORE
P VALUE	0.1573		

CI- confidence interval

This shows that MRI has good sensitivity and specificity.

DISCUSSION

During fertilization, blastocyst adheres to the endometrium. The outer trophoctoderm differentiates into syncytiotrophoblasts and cytotrophoblasts. (8,9) Syncytiotrophoblasts invade into endometrium forming lacunar networks, which later on forms the primordia of the intervillous spaces of the placenta. (8) Cytotrophoblasts will form a stem cell column for villous development. (8) As the chorionic sac grows; the villi will increase in number, forming chorion frondosum, which will form the placenta. (9)

USG is the primary imaging modality of choice for placental evaluation. The placenta is seen as a distinct structure only by 10-12 weeks of gestation on USG. However complete formation of placenta is seen only after 15 weeks. (10)

On USG placenta appears as uniform intermediate echogenicity with rounded margins. Few hypochoic linear areas are noted at the interface between myometrium and basilar decidual layer. (1) It may show intraplacental focal anechoic areas with slow flow, called as venous lakes. (10) The retroplacental clear space which is 1-2 cm thick hypochoic area located behind the placenta, composed of decidua, myometrium and uterine vessels. This gets obliterated in cases of placental invasion.

Doppler techniques help in evaluation of placental vascularity, both

utero-placental and feto-placental circulation can be well evaluated. 3/4 dimensional USG has limited role in evaluation of placental invasion.

Placental evaluation by MRI is newly emerging technique. MRI due to its high soft-tissue contrast resolution, increased field of view and multiplanar imaging is becoming modality of choice in many placental pathologies. It not only gives the information about the placental pathology but also associated pelvic abnormalities can be very well evaluated. MRI has lower spatial resolution as compared with USG, so most clinician reserve MRI as complementary imaging for equivocal findings at US and/or if additional information is required. (10)

For MRI of the placenta, 1.5-T or higher magnetic field strength system with a multichannel phased array surface coil is preferred. We had done our study on 1.5T machine using body coil. The MRI sequences for placental evaluation are single-shot fast spin-echo/turbo spin-echo (SSFSE/SSTSE), half-Fourier acquisition single-shot turbo spin-echo (HASTE) T2-weighted, and balanced steady-state free-precession (true FISP [fast imaging with steady-state precession] or FIESTA [fast imaging employing steady-state acquisition]). (11) These sequences are preferred because of short timing, less artifact due to maternal breathing and fetal movement. (11) Similarly, in our study also

we used the sequences with less time and increased signal to noise ratio.

On MRI, initially the normal placenta appears homogeneously increased signal intensity on T2 weighted images and relatively low signal intensity on T1 weighted images. As the pregnancy advances, placenta appears lobulated with multiple septa and appears slightly heterogeneous. (11)

The normal myometrium appears as three layered on T2-weighted images, showing hyperintense middle layer sandwiched between hypointense layers on either side. (11) As pregnancy advances, these three layers become indistinct.

The maternal surface of the placenta shows outpouchings of placental tissue surrounded by clefts and septa called as placental lobules or cotyledons. (2) They appear as thin bands of increased signal intensity on T2-weighted images. (12)

It is easy to identify interface between placenta and myometrium on MRI where placenta appears hyperintense to the myometrium. (13) It helps in evaluation of placental invasion. (14)

No adverse effect of MRI over developing fetus has been reported in both clinical and laboratory investigations. (15) Though MRI does not use ionizing radiation, effect due to radiofrequency waves leading to tissue heating and acoustic injury to the fetus when exposed to sound of external magnetic field could not be completely ignored. (16) No fetal damage is reported with scanning at 1.5 T. The use of intravenous gadolinium in antenatal patient is controversial. (17,18) In our study, intravenous contrast was not administered to any of the patient.

Invasion of placenta into myometrium will lead to failure of separation of placenta at the time of delivery and may result in intrapartum hemorrhage thus increasing morbidity and mortality.

The abnormal placentation has been recognized due to defective decidualization and abnormal penetration of chorionic villi into the uterine wall. (19,20)

The common risk factors for the placental invasion are prior cesarean section, placenta previa, uterine interventions (e.g. medical termination of pregnancy) and techniques performed in assisted reproduction. (21) Of these most common is prior cesarean section. With each section the risk of placental invasion increases. As in our study, all the patients were multigravida of which nine had history of lower segment caesarean section and two had medical termination of pregnancy previously. In our study five patients had placenta previa. Other less attributable factors include previous myomectomy, Asherman syndrome and increased maternal age. (10)

Placental invasion (morbidly adherent placenta) is classified according to the depth of invasion into placenta accreta, increta, and percreta).

1. Placenta accreta which is the most common form (approximately 75% of the cases)- placenta is in direct contact with the myometrium.
2. Placenta increta - placenta invades deep into the myometrium.
3. Placenta percreta-placental invasion extends beyond the uterine serosa and involves other pelvic organs. (6,7)

USG is considered as a primary modality to evaluate patient with suspected placental invasion. It has sensitivity and specificity of 82.4%-100% and 71%-100%, respectively. (11) Sonographic features of placental invasion includes loss of retroplacental clear space, placental lacunae, high-velocity flow in the placenta separate from the fetal surface of the placenta, abnormal uterine serosa- bladder interface. (17,22) One study showed that the presence of prominent placental lacunae has the highest positive predictive value. (23) While other concluded that abnormal uterine serosa-bladder interface has highest positive predictive value. (24, 25)

In our study loss of retroplacental clear space was seen in six patients and large lacunae were seen in three patients.

Most considered MRI as complimentary to USG and reserve it for unequivocal sonographic findings. But MRI placenta, done for placental invasion is problem solving in many situations.

Ideal time for MRI imaging for placental invasion is 24-30 weeks, during this period placenta is mature with homogeneous signal intensity.⁽²⁾ For placental MRI, both gradient echo and spin-echo sequences are used.

MRI features of placental invasion are lumpy contour of placenta, uterine bulge, associated placenta previa, heterogeneous placental signal intensity and dark intraplacental bands on T2weighted images.⁽⁵⁾ Association of adherent placenta with placenta previa is mostly seen and hypothesis is that placental tethering restricts the normal migration of the placenta during pregnancy.⁽²⁾

MRI has advantage of multiplanar imaging and excellent soft tissue resolution. Thus, making it modality of choice in diagnosing cases of placental invasion. It can very well differentiate between the different types of placental invasion with precision and thus help in patient management. The main purpose of doing MRI in placental invasion is to determine the depth of invasion. As the treatment strategy for placenta accreta and placenta increta is same, surgeons are not interested in their differentiation.⁽²⁾ But in case of placenta percreta, invasion into adjacent pelvic organs like urinary bladder, rectum, parametrium and pelvic muscles, changes the management and surgeons should know this before hand and in this situation MRI plays an important role. For confirmatory diagnosis of placenta percreta MRI features, like full thickness defect in the myometrium, loss of fat planes between the placenta and adjacent pelvic organs and placenta reaching the adjacent organs with loss of normal hypointense line of urinary bladder, rectum, adjacent bowel and pelvic muscles.⁽²⁶⁻²⁸⁾

In our study, we found eight cases of placenta accreta on USG and MRI and they

are confirmed on operative findings. On USG, one case of placenta accreta and two cases of placenta percreta were suspected. However on MRI total three cases of placenta increta were found. The two which were labelled as placenta percreta on USG, turned out be placenta increta on MRI which were confirmed on operative findings. So on MRI, no case of placenta percreta was found. However the main limitation in our study is less sample size.

Few studies found that MRI is more sensitive and specific modality in diagnosing placental invasion.⁽²⁹⁾ We also found that MRI is more specific than USG and better modality to differentiate between types of placental invasion. This is very important in terms of deciding exact management of the patient thus reducing morbidity and mortality.

While reporting a case of placental invasion, fetal position, exact location of placenta, site of placental invasion with respect to uterus, depth of invasion, placenta previa if present and its grading, cervix length and status of internal os, status of adjacent organs, whether placenta is invading into the adjacent pelvic organs or not should be mentioned.⁽²⁾

The main problem in MRI for placental invasion is increased number of false positive patients and it can be minimized with correlation with USG and clinical findings.

CONCLUSION

Incidence of placental invasion has been increasing due to increasing number of cesarean delivery and uterine interventions. For diagnosing them USG is the primary imaging modality due to its accessibility. However, MRI plays an important role in diagnosis of invasive placentation where USG findings are equivocal and it also accurately classifies them according to depth which in terms helps in deciding the treatment, thus reducing maternal morbidity and mortality.

REFERENCES

1. Elsayes KM, Trout AT, Friedkin AM, et al. Imaging of the placenta: a multimodality pictorial review. *RadioGraphics* 2009;29(5):1371–1391.
2. Sisodia RC, Gervais DA, Lee SI. MRI of Placenta Accreta, Placenta Increta, and Placenta Percreta: Pearls and Pitfalls. 2017;(January):214–21.
3. Silver RM, Landon MB, Rouse DJ, et al. Maternal morbidity associated with multiple repeat cesarean deliveries. *ObstetGynecol* 2006; 107:1226–1232
4. Hosler AS, Godley K, Rowland DH. An initiative to improve diabetes care standards in healthcare organizations serving minorities. *Diabetes Educ.*2002; 28:581–589.
5. Baughman WC, Corteville JE, Shah RR. Placenta accreta: spectrum of US and MR imaging findings. *RadioGraphics* 2008; 28:1905–1916
6. Comstock CH. Antenatal diagnosis of placenta accreta: a review. *Ultrasound ObstetGynecol* 2005; 26:89–96
7. Dashe JS, McIntire DD, Ramus RM, Santos-Ramos R, Twickler DM. Persistence of placenta previa according to gestational age at ultrasound detection. *ObstetGynecol* 2002; 99:692–697
8. Pinar H. The human placenta: normal developmental biology. Warwick, RI: Core Curriculum Publishers, 2009; 41–203.
9. Moore KL. The developing human: clinically oriented embryology. 8th ed. Philadelphia, Pa: Saunders/Elsevier, 2008; 55–135.
10. Findings P, Moshiri M, Fligner CL, Katz DS. Placental Imaging: Normal Appearance with Review of. 2017;979–98
11. Allen BC, Leyendecker JR. Placental evaluation with magnetic resonance. *RadiolClin North Am* 2013;51(6):955–966.12.
12. Huppertz B. The anatomy of the normal placenta. *JClinPathol* 2008; 61:1296–1302
13. Blaicher W, Brugger PC, Mittermayer C, et al. Magnetic resonance imaging of the normal placenta. *Eur J Radiol* 2006; 57(2):256–260.
14. Rahaim NS, Whitby EH. The MRI features of placental adhesion disorder and their diagnostic significance: systematic review. *ClinRadiol* 2015; 70(9):917–925.
15. Shellock FG, Crues JV. MR procedures: biologic effects, safety, and patient care. *Radiology* 2004;232:635–652
16. De Wilde JP, Rivers AW, Price DL. A review of the current use of magnetic resonance imaging in pregnancy and safety implications for the fetus. *ProgBiophysMolBiol* 2005; 87:335–353
17. Mazouni C, Gorincour G, Juhan V, Bretelle F. Placenta accreta: a review of current advances in prenatal diagnosis. *Placenta* 2007;28(7):599–603.
18. Warshak CR, Eskander R, Hull AD, et al. Accuracy of ultrasonography and magnetic resonance imaging in the diagnosis of placenta accreta. *Obstet Gynecol* 2006;108(3 pt 1):573–581.
19. Tantbirojn P, Crum CP, Parast MM. Pathophysiology of placenta accreta: the role of decidua and extravillous trophoblast. *Placenta* 2008;29(7):639–645.
20. Strickland S, Richards WG. Invasion of the trophoblasts. *Cell* 1992;71(3):355–357.
21. Collins SL, Ashcroft A, Braun T, et al. Proposal for standardized ultrasound descriptors of abnormally invasive placenta (AIP). *Ultrasound Obstet Gynecol* 2016;47(3):271–275.
22. Dwyer BK, Belogolovkin V, Tran L, et al. Prenatal diagnosis of placenta accreta: sonography or magnetic resonance imaging? *J Ultrasound Med* 2008;27(9):1275–1281.
23. Comstock CH, Love JJ Jr, Bronsteen RA, et al. Sonographic detection of placenta accreta in the second and third trimesters of pregnancy. *Am J Obstet Gynecol* 2004;190(4):1135–1140.

24. Calì G, Giambanco L, Puccio G, Forlani F. Morbidly adherent placenta: evaluation of ultrasound diagnostic criteria and differentiation of placenta accreta from percreta. *Ultrasound ObstetGynecol* 2013;41(4):406–412.
25. Wong HS, Cheung YK, Zuccollo J, Tait J, Pringle KC. Evaluation of sonographic diagnostic criteria for placenta accreta. *J Clin Ultrasound* 2008; 36(9):551–55.
26. Leyendecker JR, DuBose M, Hosseinzadeh K, et al. MRI of pregnancy-related issues: abnormal placentation. *AJR* 2012; 198:311–320
27. Masselli G, Brunelli R, Casciani E, et al. Magnetic resonance imaging in the evaluation of placental adhesive disorders: correlation with color Doppler ultrasound. *EurRadiol* 2008; 18:1292–1299
28. Levine D, Obstetric MRI. *Journal of magnetic resonance imaging. J MagnReson Imaging* 2006;24:1–15
29. Bour L, Placé V, Bendavid S, et al. Suspected invasive placenta: evaluation with magnetic resonance imaging. *EurRadiol* 2014; 24:3150–31

How to cite this article: Ratnaparkhi CR, Sharma S, Dhok AP et.al. Efficacy of magnetic resonance imaging over ultrasound in the diagnosis of placental invasion. *Int J Health Sci Res.* 2019; 9(8):51-59.
