

Case Report

# Ayurvedic Management of Macular Pucker - A Case Report

Sreekala N. P<sup>1</sup>, Aravind Kumar<sup>2</sup>, Krishnendu Sukumaran<sup>2</sup>, Neethu K. V<sup>3</sup>

<sup>1</sup>Deputy Chief Physician and Vice President, <sup>2</sup>Research Coordinator, <sup>3</sup>Junior Medical Officer, Sreedhareeyam Ayurvedic Research and Development Institute, Nelliakkatu Mana, Koothattukulam, Ernakulam District-686662, Kerala, India

Corresponding Author: Krishnendu Sukumaran

## ABSTRACT

Macular pucker, otherwise known as epiretinal membrane or cellophane maculopathy, is divided into two varieties, viz., idiopathic and secondary. Idiopathic macular pucker is not associated with any condition, while the secondary variety is associated with inflammatory, vascular, and traumatic retinal disease. Symptoms include metamorphopsia and blurred central vision. The general line of management in such conditions is surgical. The case of a 49-year-old female who was confirmed to have macular pucker and who underwent *Ayurvedic* management at Sreedhareeyam Ayurvedic Eye Hospital and Research Center is presented here. She underwent a course of inpatient treatment that included internal medicine, *Panchakarma* (cleansing) therapy, and external therapy for the head and eye. Improvement was observed in both distant and near visual acuity and OCT scanning. As the *Ayurvedic* management involves reconfiguration of the gut treating the ocular condition, and enhancing vision, it can be considered as an option to standard surgical management.

**Keywords:** *Timira, Nasya, epiretinal membrane, Tarpana*

## INTRODUCTION

Epiretinal membrane (ERM) is divided into macular pucker and cellophane maculopathy. It develops at the vitreo-retinal interface and consists of retinal glial cells that proliferate and gain access to the interface through breaks in the internal limiting membrane (ILM).<sup>[1]</sup> Macular pucker is caused by contraction and thickening of the epiretinal membrane. Blurring of vision and metamorphopsia are the main presenting symptoms, although some cases may be asymptomatic. Visual acuity (VA) is variable based on severity. Fundus examination in the initial stages shows an irregular translucent sheen, while more advanced cases show blood vessel distortion, retinal wrinkling, and obscured underlying structures. Optical coherence tomography (OCT) shows a highly

reflective surface layer associated with a thickening. Observation is indicated in mild conditions. Surgical removal (peeling) of the membrane by vitrectomy improves or eliminates distortion, with an improvement of vision up to 2 lines of VA.<sup>[2]</sup>

Macular pucker *per se* is not described in the *Ayurvedic* canon; however, it may be correlated with *Vataja Timira* (blurring of vision caused by *Vata Dosha*), a *Drshatigata Roga* (disease of vision). Perception of objects as revolving, dirty, crooked, and reddish are the symptoms of *Vataja Timira* according to *Acarya Susruta*.<sup>[3]</sup> *Acarya Vagbhata* explains that the patient perceives objects as though covered by a thin cloth, sometimes dirty (or clean), unsteady, slightly red, and also perceives webs, hairs, mosquitoes, and rays of light.<sup>[4]</sup>

Vataja Timira is managed first by drinking *Ghrta* (ghee) prepared from *Dasamula Kvātha* (decoction of the roots of *Bilva*, *Agnimantha*, *Syonaka*, *Patala*, *Gambhari*, *Salaparni*, *Prsniparni*, *Brhati*, *Kanthakari*, and *Gokshura*), four parts of milk, and the paste of *Sreshtha* (*Triphala – Haritaki*, *Vibhitaki*, and *Amalaki*). Then, *Virecana* (purgation) is induced with the *Kvatha of Triphala* and *Pancamula* added with milk and *Eranda Taila* (castor oil).<sup>[5]</sup> *Tarpana* (retention of ghee in the eye) is indicated when the condition does not improve in spite of the above treatment.<sup>[6]</sup>

**CASE REPORT**

A 49-year-old female educator based in Edison, New Jersey, U.S.A., presented to the OPD of Sreedhareeyam Ayurvedic Eye Hospital and Research Center with a

complaint of defective distant vision in both eyes since she was 16 and defective near vision in both eyes since the age of 40.

She was diagnosed with astigmatism when she was 16 and has been using power glasses since then. A routine eye examination, done 6 years ago, gave her the diagnosis of macular pucker in her right eye. She first consulted Sreedhareeyam Hospital in February-March 2017 and underwent internal and external inpatient treatment.

Her past history is notable for eczema, pain all over her body, pain in the small joints of her lower limb, and throbbing pain in her knee. She has a family history of glaucoma. Her personal and social history is normal.

Her visual and fundus examinations are presented in Table 1.

Table 1: Visual and Fundus Examination at the Time of Admission

Parameter	Right Eye (OD)	Left Eye (OS)
Unaided Distant Visual Acuity	6/60	6/36
Aided Distant Visual Acuity	6/6	6/6
Near Visual Acuity	N10	N10
Fundus	Small optic disc, foveal reflex present	Small optic disc, foveal reflex present

An OCT scan showed a hyper-reflective area at the macular region with loss of the foveal contour and associated thickening of the retina (Figure 1).

Based on the investigations, the patient was diagnosed with macular pucker.

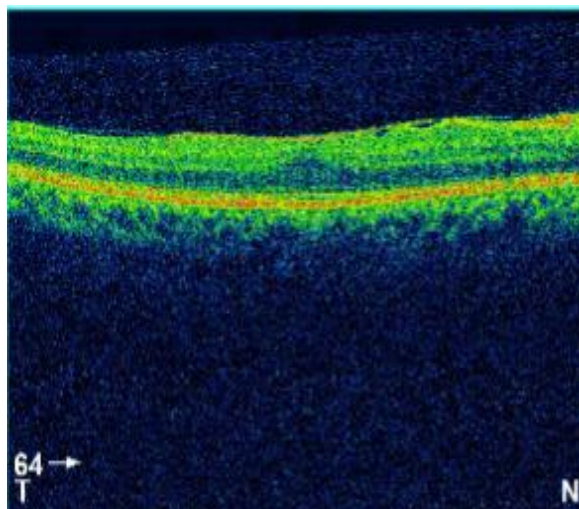


Figure 1: OCT at admission

**Intervention**

The patient was admitted in February 2018 for a course of oral medication, external therapies, and *Pancakarma* therapy.

The oral medicines consisted of *Cirivilvadi Kashaya* (60mL with lukewarm water at 6 am),<sup>[7]</sup> *Varanadi Kashaya* (60mL with lukewarm water at 6 pm),<sup>[8]</sup> and *Hinguvacadi Gutika* (2 tablets with *Jiraka* water (water prepared with *Cuminum cuminum* Linn.)).<sup>[9]</sup> Her external treatments are described in Table 2.

**Outcome Measures**

Distant and near VA and OCT were assessed for this patient. She was prescribed Eye Plus Eye Drops\* (1 drop in both eyes twice a day) upon discharge and was advised regular follow-ups.

Improvement was noted in both distant and near VA at discharge and at a subsequent follow-up (Table 3). An OCT scan taken on April 14<sup>th</sup>, 2019 showed

improvement in the hyper-reflective area and reappearance of the foveal contour. (Figure 2).

Table 2: External and Pancakarma Therapy

Therapy	Procedure	Duration	Manufacturer
Pratimarsa Nasya with Anutaila	The patient lay supine and two drops of the medicated oil were instilled into each nostril.	Days 1, 3, 5, 6, 7	Sreedhareeyam Ayurvedic Medicines Pvt. (Ltd)
Anjana with Netramrtam Eye Drops*	The patient lay supine and one drop of the medicine was instilled into each eye at the inner canthus.	Days 1, 2, 3, 5, 6	
Seka with Kasyapam Kvatha*	The patient lay supine and the medicine was poured in a thin, continuous stream over the eyelids.	Days 1, 2, 3, 5, 6	
Virecana with Triphala Kvatha and Trvrt Lehya	15mL of the decoction and 1 tea-spoon of the linctus were administered to the patient in the early morning. The urges were recorded.	Day 4	
Ascyotana and Bandhana with Jatavedha Ghrita*	The patient lay supine and one drop of ghee was instilled at the inner canthus. Afterwards, jasmine flowers were kept over the eyes and a bandage was applied.	Days 7, 8	
Tarpana with Jatavedha Ghrita*	The lukewarm ghee was poured into two circular fences made from gram flour placed over the patient's orbits. The patient was asked to continuously blink.	Days 7, 8, 9	

\*Patented medicines of Sreedhareeyam Ayurvedic Eye Hospital and Research Center.

Table 3: Visual acuity at discharge and at a follow-up

Parameter	At Discharge		Follow-Up	
	OD	OS	OD	OS
Unaided Distant Visual Acuity	6/36	6/36	6/36	6/24
Aided Distant Visual Acuity	6/6	6/6	6/6	6/6
Near Visual Acuity	N10	N10	N6	N6

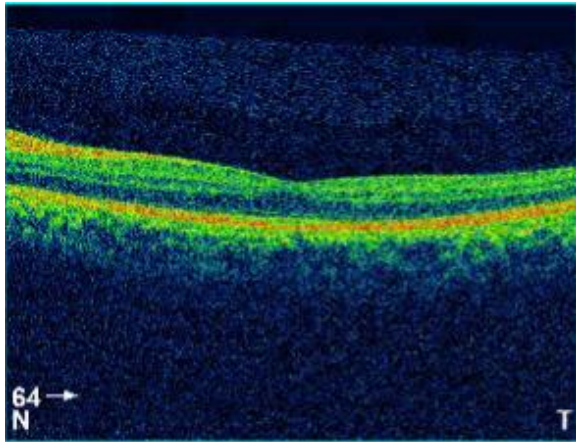


Figure 2: OCT at discharge

**DISCUSSION**

ERMs can be classified into 4 stages based on OCT findings: Stage I ERMs are thin and present with a foveal depression and clearly distinguishable retinal layers; Stage II ERMs lack foveal depression and present with distortion of retinal layers; Stage III ERMs denote emergence of ectopic foveal layers and observable retinal layers; and Stage IV ERMs are thick and present with a distorted macula, indistinguishable retinal layers, and continuous ectopic inner foveal layers. [10]

This staging determines the diameter of the randomly-oriented extracellular fibrils that characterize the structure of idiopathic ERMs. [11] The fibrils of macular pucker, which are composed largely of types I and II collagen, range from 18-56mm in diameter.

The concept of *Vataja Timira* was explored for this patient based on her symptoms of blurring of vision and metamorphopsia. Although vision is blurred, some details of the objects can still be perceived. Metamorphopsia or distorted image can be correlated to *Vyavidhha Pasyati* (crooked perception), as the image perceived is not straight. Pathologically increased *Kapha Dosha* was also explored because of the macular pucker being a solid membrane. This illustrates the fact that anything heavy and profound cannot manifest without *Kapha*. [12]

The internal medicines all perform one common action, that of enhancing the *Jatharagni* (digestive fire). *Varanadi Kashaya* not only enhances the *Agni*, but also by reducing *Kapha*, diminishes the membrane and improves vision.

Before administering *Virecana*, *Anjana* was initially applied to scrape away some of the increased *Kapha*. *Virecana* prevents *Urdhva-Prasrta* (upward movement) of *Doshas* (humors) to the *Siras* (head) by expelling them through the anal

canal. *Pratimarsa Nasya* scrapes away the morbid *Doṣās* from the *Uttamanga* (head) by reaching the *Srngataka* (a *Marma* or vital spot) and spreading around the brain by routes of the *Netra* (eye), *Srotra* (ear), *Kantha* (throat), and *Siramukha* (vessel openings). *Anutaila* is considered as an effective oil for *Nasya* in both healthy people and patients by its virtue of strengthening the sense organs. *Seka*, by its contact with the skin of the eyelids, stimulates nerve endings and enables mobilization, irrigation, and expulsion of obstructive toxins.

*Tarpana* was done after *Virecana* and *Pratimarsa Nasya*, as they are indicated after purifying both the body and the head. Instillation of ghee in liquid form and the repeated blinking of the eyes in *Tarpana* cause the corneal stroma to become lipophilic, thus enabling more absorption of lipids into the eye and to reach the deeper structures. By this method, the patient's vision improved and the pucker was reduced.

*Kasyapam Kvatha* is made from *Haritaki*, *Vibhitaki*, *Amalaki*, *Bala*, *Bhrngaraja*, and *Candana*, and is indicated in all eye diseases. *Netramrtam* is prepared from *Sphatika*, *Saindhava Lavana*, and distilled water, and is a good *Drshthiprasadana* (enhancer of vision). *Jatavedha Ghṛta* is prepared from *Katurohini*, *Haritaki*, *Vibhitaki*, *Amalaki*, and *Pippali*, and is useful for *Tarpana* in all eye diseases, especially for the posterior segment.

Generally, membrane peeling by pars plana vitrectomy is employed to treat macular pucker and epiretinal membrane. This case was managed using an *Ayurvedic* protocol that included oral medicines and both external and *Pancakarma* therapy. The first step was to enhance the *Jatharagni*, which was accomplished by the internal medicines. This enabled more efficient digestion and opened up the *Srotas* (channels), which were unable to supply nutrition to the eye. Some amount of increased *Kapha* was dislodged from the

eye by the application of *Anjana*. *Virecana* and *Nasya* expelled more *Kapha* and *Pitta* from the body and head. Ultimately, *Tarpana* provided nourishment to the eye and enhanced vision. Thus, the *Ayurvedic* protocol can be considered as an alternative to surgery, with its holistic approach to treating the condition and returning the body to its physiological state.

## CONCLUSION

The diagnosis of *Vataja Timira* was made based on the history and examination of the patient. Improved VA was observed after the *Ayurvedic* management, and further improvement was seen at a subsequent follow-up.

## REFERENCES

1. Kanski, J. J., *Clinical Ophthalmology: A Systematic Approach: 5<sup>th</sup> Edition*, Saunders, an imprint of Elsevier, Ltd., 2009, pg. 427
2. Kanski, J. J., and Bowling, B., *Clinical Ophthalmology: A Systematic Approach" 7<sup>th</sup> Edition*, Saunders, an imprint of Elsevier, Ltd., 2011, pg. 636
3. Sharma, P. V. *Susruta Samhita: Text with English Translation and Dalhana's Commentary alongwith Critical Notes, Vol. III: Kalpasthana and Uttarantra*, Chaukhamba Vishwabharati, Varanasi, 2010, pg. 141
4. Murthy, K. R. S., *Ashtangahrdaya of Vagbhata: Text, English Translation, Notes, Appendices, and Index, Vol. III: Uttara Sthana*, Krishnadas Academy, Varanasi, 1997, pg. 107
5. Murthy, K. R. S., *Ashtangahrdaya of Vagbhata: Text, English Translation, Notes, Appendices, and Index, Vol. III: Uttara Sthana*, Krishnadas Academy, Varanasi, 1997, pg. 121-122
6. Murthy, K. R. S., *Ashtangahrdaya of Vagbhata: Text, English Translation, Notes, Appendices, and Index, Vol. III: Uttara Sthana*, Krishnadas Academy, Varanasi, 1997, pg. 123
7. Nishteswar K., and Vidyanath, R., *Sahasrayogam: Text with English Translation*, Chowkhamba Sanskrit Series Office, Varanasi, 2014, pg. 25
8. Murthy, K. R. S., *Ashtangahrdaya of Vagbhata: Text, English Translation, Notes,*

- Appendices, and Index, Vol. I: Sutrasthana*, Krishnadas Academy, Varanasi, 1997, pg. 203
9. Nishteswar K., and Vidyanath, R., *Sahasrayogam: Text with English Translation*, Chowkhamba Sanskrit Series Office, Varanasi, 2014, pg. 191
  10. Govetto, A., Lalane, R. A., Sarraf, D., Figueroa, M. S., Hubschman, J. P., Insights into Epiretinal Membranes: Presence of Ectopic Inner Foveal Layers and a New Optical Coherence Tomography Staging Scheme, *American Journal of Ophthalmology*, March 2017, Volume 175, pgs. 99-113
  11. Kritzenberger M., et al., Different collagen types define two types of idiopathic epiretinal membranes, *Histopathology* 58.6, (2011): 953-965
  12. Murthy, K. R. S., *Madhava Nidanam of Madhavakara: Text with English Translation, Critical Introduction, and Appendix*, Chaukhambha Orientalia, Varanasi, 2001, pg. 135

How to cite this article: Sreekala NP, Kumar A, Sukumaran K et.al. Ayurvedic management of macular pucker - a case report. *Int J Health Sci Res.* 2019; 9(8):494-498.

\*\*\*\*\*