

Case Report

# Unilateral Auditory Neuropathy Spectrum Disorder: A Single Case Study

Ms. Darpadalini Mohanty<sup>1</sup>, Dr. Reeny Roy<sup>2</sup>, Ms. Preeti Sahu<sup>3</sup>,  
Ms. P. Melvin Prais<sup>1</sup>

<sup>1</sup>Master Student (MASLP), Naseema Institute of Speech and Hearing (NAISH), Bangalore

<sup>2</sup>Associate professor, Naseema Institute of Speech and Hearing (NAISH), Bangalore

<sup>3</sup>M.Sc. (Audiology), Audiologist-ICMR NTF HI project, Dept. of ENT& HNS, AIIMS Raipur.

Corresponding Author: Dr. Reeny Roy

## ABSTRACT

Auditory neuropathy spectrum disorder (ANSND) is a recently discovered hearing disorder. Across literature there are dearths of studies which documents for unilateral auditory neuropathy spectrum disorder (UANSD). The current study describes a 20 year old male presenting with a complaint of hearing difficulty since few years in adverse listening conditions. The subject had no family and medical history which can directly or indirectly have an impact on auditory system. Previous audiological evaluation reveals unilateral severe sensori-neural hearing loss. Radiological evaluation reveals no structural abnormalities. The objective of the current study is to reach the correct diagnose for the case observed with unique feature using test battery approach. Method of the current study involves an intensive diagnostic approach starting from case history, Otoscopic evaluation; Behavioral measures, physiological measures and electrophysiological measures. However the result of the current study is strongly indicating towards the classic condition of ANSD.

**Key Words:** Unilateral Auditory Neuropathy Spectrum Disorder (UANSD), Cochlear Nerve Deficiency (CND), Behavioral measures, physiological measures, Electrophysiological measures, Test battery approach

## INTRODUCTION

Auditory Neuropathy (AN) is a condition in which the transmission of the auditory signals from the inner ear to the auditory nerve and auditory brainstem is distorted. The classic description of auditory neuropathy is that patients display normal cochlear outer hair cell function and abnormal neural function of the most distal portion of the eighth nerve, possibly including cochlear inner hair cells, eighth nerve dendritic connections, and spiral ganglion. <sup>[1]</sup> Hallmark of AN is the vast inter and intra-subject variability which defines its patient population. This variability has lead to historically different

classifications or nomenclatures for AN. <sup>[2]</sup> Currently, the term “*Auditory Neuropathy Spectrum Disorder*” is used to draw attention to the fact that patients diagnosed with ANSD may each fall somewhere on a continuum that represents the possible combinations of functioning inner and outer hair cells, synaptic issues, and/or post-synaptic neural involvement. <sup>[3]</sup>

1 in 200 hearing impaired children exhibits an audiological picture that is consistent with the contemporary diagnosis of AN. <sup>[4]</sup> Literature reveals that approximately 10% of children seen with severe-to profound hearing loss may have neural site of origin than hair cell disorders.

[5] However, some current estimates indicate 61 of 21,236 hearing impaired patients were having AN out of which 75% had an onset below 10 years. [6] Similar results observed in another study of 59 participants with AN where the mean age of onset of the symptom was 9 years. There was a nearly equal distribution of male (55%) and female (45%). [7] A retrospective study consisted of 260 patients with ANSD reported by Berlin et al., 2010 where 85.76% of patients were below 12 years. Incidence and prevalence of AN had been studied by authors on 61 cases with AN where 59% cases were between the age of 14 to 24 years and female male ratio of 2:1. The authors estimated the prevalence of AN was around 1 in 183 (0.54%) in individual with sensorineural hearing loss. [8] Prevalence of AN was reported to be 0.94% within the group at risk for hearing loss, 8.44% among profoundly hearing-impaired children. [9] AN was typically reported to be bilateral in 96% of its population (Sininger, 2000). A study conducted on 340 AN cases in which 11 cases were diagnosed as unilateral AN. [10]

Possible underlying etiologies in AN may include genetic diseases such as Charcot-Marie-Tooth, Friedreich's ataxia and mitochondrial disease, [11,12] hyperbilirubinemia (Rance et al., 1999; Stein et al., 1996) and complicated perinatal periods with multiple factors that might result in central nervous system insult. [13] The greatest number of AN cases is reportedly due to genetic factors or are of idiopathic origin. A group of authors encountered 13 neonates with hyperbilirubinemia. However 6 out of 13 neonates had shown an audiological finding of acute ANSD. Out of 6 infants 2 of them were manifested clinical sign and symptoms of bilirubin encephalopathy. [14] 85 participants with unilateral profound sensorineural hearing loss who underwent hearing test out of which 10 children undergone for MRI examination. The neural responses from the cochlea of 8 patients were absent in MRI suggestive of unilateral auditory neuropathy

which may be caused by Cochlear Nerve Deficiency (CND). [15]

Audiological profile of ANSD showed heterogeneity among its test population. A single case study had done on a 5 year old boy where Pure Tone Audiometry (PTA) result revealed unilateral profound sensorineural hearing loss (SNHL) with presence of transient and distortion product Oto acoustic emission (TEOAE & DPOAE) and absence of auditory brainstem responses (ABR). [16] Similar results were listed for an 11 year old boy, which shown unilateral profound SNHL in PTA, normal outer hair cell function in OAE and absence of neural synchrony in ABR. Radiological finding for the respective case reveals normal auditory structure. [17] Wang et al., 2007 reported 11 patients with an average age of 20 year and period of disease was 3.1 year approximately. All 11 patients had a complaint of unilateral gradual hearing loss out of which 6 were having complaint of difficulty in discriminating speech correctly. PTA showed varying degree among the participants. ABR was absent for all the participants in the affected ear while it was preserved in the normal ear. DPOAE was present for all the participants with reduced amplitude. Contralateral suppression of DPOAE was suppressed in the unaffected ear while in the affected ears it was reduced or disappeared. An extensive behavioural and electrophysiological test battery was carried out on a 65 year old female who presented with a complaint of progressive unilateral hearing loss over past 2-3 years. And the results revealed unilateral notched hearing loss centered at 1 kHz with poor speech perception than would be predicted from the audiogram. Physiological examination showed absence of middle ear muscle reflex with stimulation presented on the affected ear and presence of bilateral OAE and cochlear microphonics (CM). Electrophysiological evaluation revealed absence of ABR in the affected ear and presence of middle latency response (MLR) and late latency response (LLR) bilaterally with a reduction in amplitude in the affected

ear. [18] Audiological findings of a 3 year old boy who diagnosed as ANSD coincides with the previous study. [19] A retrospective study had done on 14 patients with UANSD. Results of the study showed varying degree of hearing loss ranging from moderate to profound hearing loss with preserved OAE, CM and absence of ABR. [20] Cheng Liu, Xingkuan Bu, Feiyun Wu & Guangqian Xing, 2012 reported 85 patients with unilateral profound sensorineural hearing loss who underwent hearing tests and an MRI examination. None of the patients had medical and any family history which can substantially affect the hearing. Immittance results were varying among the participants. In all cases ABRs were absent. EOAE and CM were present in seven patients. The neural responses from the cochlea of the eight patients were absent in MRI which was significantly suggestive of unilateral auditory neuropathy may be caused by cochlear nerve deficiency. Audiological findings of an 18 month old case with absence of OAE, abnormal ABR waveform and abnormal middle ear muscle reflex. [21] Similar results were obtained on a 10 year old female who was diagnosed as UAN. [22]

## CASE REPORT

### History

A 20 year old male subject reported to the clinic with a complaint of reduced hearing sensitivity in right ear since 3-4 years in situations where competing stimuli are present (background noise, group discussion etc). There was no significant medical history as well as family history reported. The earlier evaluations included behavioural audiometry i.e. PTA and radiological evaluation (MRI). The result revealed profound SNHL in the Right Ear, where in the Left Ear was found to be within the normal limits of hearing sensitivity. Multiplanar Magnetic Resonance Images of the brain of T1 TIRM, T2 TSE and T2 TIRM dark fluid sequences and EP 2D diffusion 3 scan trace sequences reveals brain parenchyma to be normal with normal grey and white matter

differentiation. The ventricular system basal cisterns and cortical sulci are normal. No mass effect/midline shift present. Basal ganglia, thalamus, brainstem and cerebellum are normal in morphology and signal intensity, both seventh and eighth nerves complexes are normal. No CerebelloPontine (CP) angle lesion was reported. Bilateral orbits are normal in morphology and signal intensity. Ali Maeed AL-Shehri, 2015 conducted a single case study on a 10 year old female where the Audiological and Radiological findings revealed UANSD which coincides with the results of the current study.

## METHOD

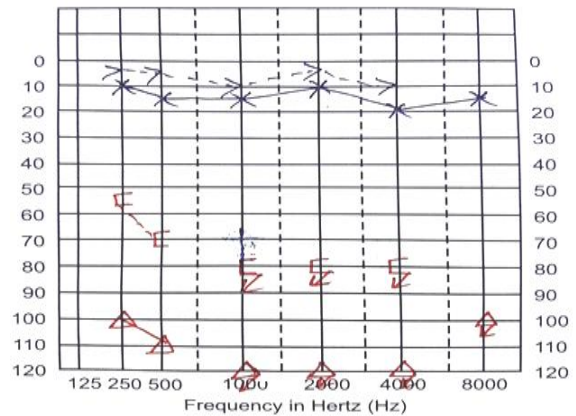
The procedure carried out in the study is in accordance to AIISH ethical guidelines for Bio-behavioural Research (2009). [23]

A detail case history was obtained followed by which Otoscopic evaluation to visualize the external auditory canal and tympanic membrane status. All the audiological evaluations were carried out in a sound treated room. Behavioral audiometric threshold (PTA) had been obtained using Hughson Westlake procedure (when patient responds to the sound reduce the presentation level by 10dB and when patient fails to respond increase by 5 db) using MAICO instrument. Speech Audiometry was performed to find the speech recognition threshold (SRT) as well as the speech identification scores (SIS). SRT was administered at 20 dB SL using spondee word list in Hindi and criteria for the threshold kept as 2 out of 3 spondees should be recognized. SIS was obtained at 40dBSL using phonetically balanced (PB) word list in Hindi. 20 PB words were presented and the patient was instructed to repeat back and each correct response was calculated as 5%. Tympanogram and Acoustic reflex thresholds were assessed using INTERACOUSTIC instrument. Tympanogram was measured using a 226 Hz probe tone, with sweep pressure starts point at -200 dapa to end point of +400 dapa. Ipsilateral and Contralateral acoustic

reflex were obtained using Puretone activator stimuli 500 Hz, 1 kHz, 2 kHz and 4 kHz at 90dBHL, 100dBHL and 110dBHL. The patient was instructed to sit quite and not to move during the procedure. Distortion product Otoacoustic emissions (DPOAEs) were recorded using NEUROSOFT instrument to check to outer hair cell (OHC) function. Tone pair was sequential, with an F2/F1 ratio of 1.2. Intensity of the tone pairs was 65 and 55 dB SPL for L1 and L2, respectively. Two separate runs per ear were collected for determining repeatability. Validity and reliability of normal outer hair cell function was determined by analyzing each distortion product frequency separately. Passing criteria for DPOAE was 6dB SNR. Contralateral suppression of DPOAE was measured bilaterally to check the functional integrity of efferent pathway. Broadband noise at 40dB SL was presented contralateral to the test ear to measure suppression of DPOAE. Auditory Brainstem Response (ABR) was undertaken using NEUROSOFT instrument. 1msec click-evoked ABR was recorded using a band pass filter from 30 Hz to 3000 Hz with 10ms time window. Rarefaction clicks were presented at the rate of 11.1 per second. Horizontal placement was used using surface electrodes and the electrode impedance was regularly monitored. Recording was obtained in a sound proof condition.

**RESULTS AND DISCUSSION**

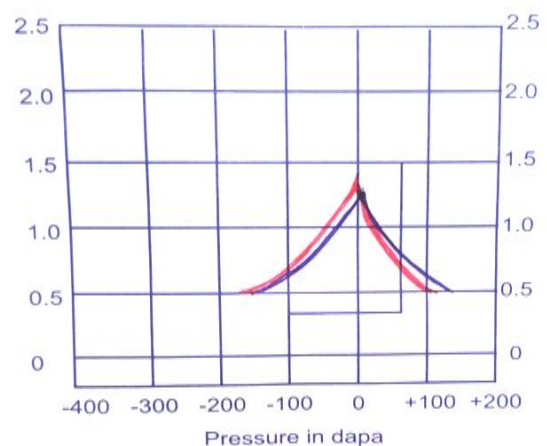
**Behavioural Evaluation:** Pure tone threshold was similar to that of previously obtained value i.e. Right Ear: Profound Sensorineural Hearing Loss, Left Ear: Hearing sensitivity within normal limits as shown in Figure 1.



**Fig.1 Pure Tone Audiometry Thresholds for Right and Left ears**

Speech audiometry could not be performed due to threshold limitation in the Right Ear, but for the left ear SRT and SIS had been obtained at 20 dBHL and 100% score respectively.

**Physiological Evaluation:** Tympanometry result revealed bilateral “A” type tympanogram which suggestive of normal middle ear functioning as shown in Figure 2. Reflexometry for the Right Ear revealed absence of ipsilateral and contralateral reflexes. Left Ear ipsilateral reflexes were preserved and contralateral reflexes were absent due to higher degree of hearing loss in probe ear. Physiological examination showed “A” type tympanogram with absence of middle ear muscle reflex with stimulation presented on the affected ear [24] which coincides with the current study.



**Fig. 2 Tympanometry Result for Right and Left Ear**

DPOAE test results at F2 indicate normal outer hair cell function at the 1500 Hz to

6000 Hz region of the cochlea for the right ear and the 1000 Hz to 6000 Hz region for the left ear. Bilateral presence of DPOAE's suggestive of normal OHC functioning as shown in figure 3. In accordance with the above mentioned result, a study consisted of 19 patients with ANSD reported to observe normal OAE. [25]

Contralateral suppression of DPOAE showed greater suppression in the left ear while in the right ear suppression was disappeared. In accordance to the current study a study carried out on patients with AN/AD which demonstrated significantly reduced suppression of TEOAEs for binaural, ipsilateral, and contralateral suppressor stimulus conditions. [26]

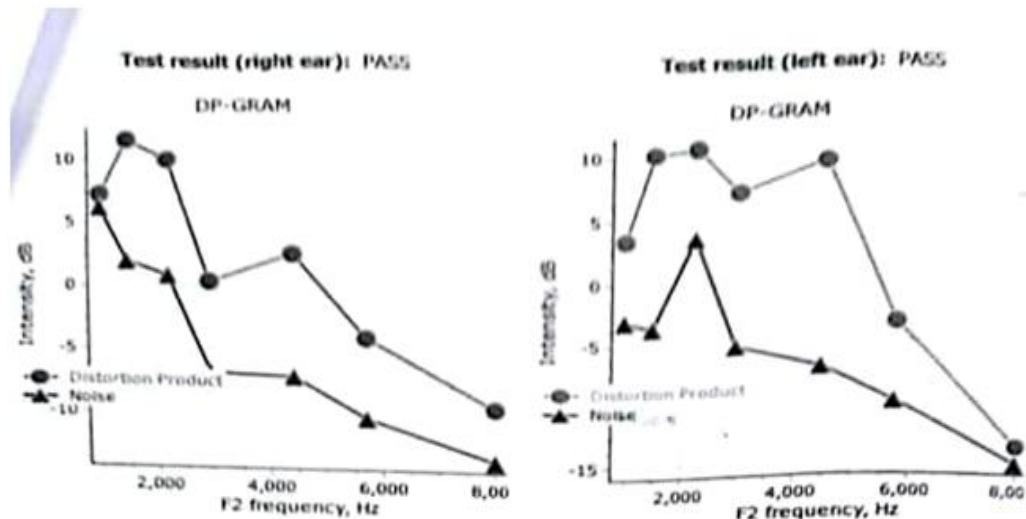


Fig. 3 DPOAE Results for Right and Left Ear

**Electrophysiological Evaluation:** ABR results revealed absence of wave I, III & V indicated right Profound hearing loss when stimulus given up to 100 dB nHL. Wave I, III & V obtained at 40 dBnHL with greater efficacy of morphology suggestive of normal hearing sensitivity in left ear as shown in Figure 4. Hence suggestive of normal auditory brainstem functioning at the level of CN, SOC and IC in left ear and vice versa for right ear. A study group included 112 hearing impaired children where all subjects were having no identifiable ABR wave in addition to that CM were detected in 15 patients, which in turns confirms the clinical criteria for ANSD. [27]

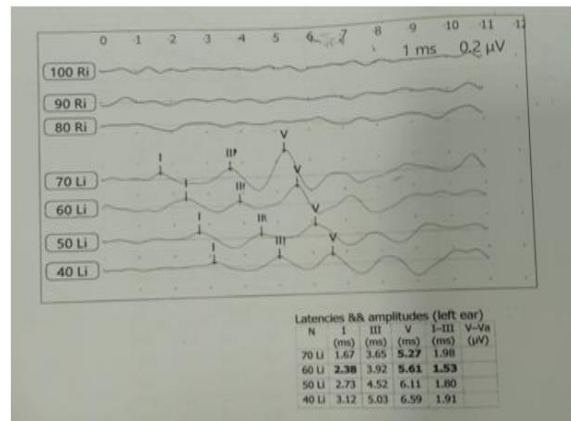


Fig 4 Auditory Brainstem Response for Right and Left Ear

## CONCLUSION

The patient presented in this case study had gone through multiple tests including Behavioural, Physiological, Electrophysiological and Radiological evaluation. The ENT looked for etiologies in order to explain the hearing deficit but there was no underlying etiology they could find which supports the fact that the present case is of idiopathic origin. Based on the results of all test performed a diagnosis was

made as UANSD. AN is often difficult to diagnose so timely attention is required to lead to a sooner intervention. Making a differential diagnosis is sometimes burdensome for the practitioner. ANSD sometime get misdiagnosed with other cochlear and retrocochlear pathologies due lack of clinical competency and clinical evidence. Audiologists need to have a thorough knowledge of the pathophysiology for the diagnosis of AN. Hence, using a test battery approach with a cross check principle is required by the practitioner in order to rule out biases while encountering underlying pathologies of hearing.

### ACKNOWLEDGEMENT

We would like to share our heartfelt thanks to Naseema Institute of Speech and Hearing for helping us in conducting the research. I would also like to show my gratitude to Dr. Reeny Roy (Associate professor, Naseema institute of speech and hearing) for sharing the pearls of wisdom during the course of this research. I would like to thank Ms. Preeti Sahu (Audiologist, ICMR-NTF HI Project, AIIMS) who provided insight and expertise that greatly assisted the research. I would like thank my colleague Ms. P. Melvin Prais (Master Student, Naseema Institute of Speech and Hearing) for her immense help and support in preparing the manuscript.

### REFERENCES

1. Manchaiah, V.K., Zhao, F., Danesh, A.A., Duprey, R. The genetic basis of auditory neuropathy spectrum disorder (ANSD). *Int J Pediatr Otorhinolaryngol.* 2011; 75: 151-158.
2. Rapin, I., Gravel, J.S. Auditory neuropathy: a biologically inappropriate label unless acoustic nerve involvement is documented. *J Am Acad Audiol.* 2006; 17:147.
3. Berlin, C.I., Hood, L.J., Morlet, T. Multi-site diagnosis and management of 260 patients with auditory neuropathy/dys-synchrony (auditory neuropathy spectrum disorder\*). *Int J Audiol.* 2010; 49: 30-43
4. Hirsh, D.S.K. A slow brain stem response for low-frequency audiometry. *Audiology.* 1979; 18: 445-446.
5. Rance, G., Beer, D.E., Cone-Wesson, B., Shepherd, R.K., Dowell R.C., King, A.M. et al. Clinical findings for a group of infants and young children with auditory neuropathy. *Ear Hear.* 1999; 20: 238-252.
6. Starr, A, Picton, T.W., Sininger, Y., Hood, L.J., Berlin, C.I. Auditory neuropathy. *Brain* 1996; 119: 741-753.
7. Sininger, Y., Oba, S. Patients with auditory neuropathy: who are they and what can they hear. *Auditory neuropathy: A new perspective on hearing disorders.* 2001:15-35.
8. Kumar, U.A., Jayaram, M.M. Prevalence and audiological characteristics in individuals with auditory neuropathy/auditory dys-synchrony. *Int J Audiol.* 2006; 45: 360-366.
9. Foerst, A., Beutner, D., Lang-Roth, R., Huttenbrink, K.B, Von, W.H., Walger, M. Prevalence of auditory neuropathy/synaptopathy in a population of children with profound hearing loss. *Int J Pediatr Otorhinolaryngol.* 2006; 70: 1415-1422.
10. Wang, J., Shi, L., Gao, L., Xie, J., Han, L. Audiological characteristics of unilateral auditory neuropathy: 11 case study. *J Clin Otolaryngol Head Neck Surg.* 2007; 21: 436-440.
11. Berlin, C.I., Hood, L.J., Hurley, A., Wen, H. Contralateral suppression of otoacoustic emissions: an index of the function of the medial olivocochlear system. *Otolaryngol Head and Neck Surg.* 1994; 110: 3-21.
12. Corley, V.M, Crabbe, L.S. Auditory neuropathy and a mitochondrial disorder in a child: case study. *J Am Acad Audiol.* 1999; 10: 484-488.
13. Paul, D., Mansbach, L.A., Bozet, C., Clercx, A., Hecox, K.E.. "Auditory neuropathy: a report on three cases with early onsets and major neonatal illnesses. *Electroencephalogr Clin Neurophysiol.* 1997; 104: 17-22.
14. Saluja, S., Agarwal, A., Kler, N., Amin, S. Auditory neuropathy spectrum disorder in late preterm and term infants with severe jaundice. *Int J Pediatr Otorhinolaryngol.* 2010; 74: 1292-1297
15. Liu, C., Bu, X., Wu, F., Xing, G. Unilateral auditory neuropathy caused by cochlear nerve deficiency. *Int J Otolaryngol.* 2012; 1-5.

16. Ohwatari, R., Fukuda, S., Chida, E. Preserved otoacoustic emission in a child with a profound unilateral sensorineural hearing loss. *Auris Nasus Larynx*. 2000; 28: 117-120
17. Podwall, A., Podwall, D., Gordon, T.G., Lamendola, P., Gold, A.P. Unilateral auditory neuropathy: case study. *J child neurol*. 2002; 17: 306-309
18. Stuart, A., Mills, K.N. Late-onset unilateral auditory neuropathy/dysynchrony: a case study. *J Am Acad Audiol*. 2009; 20: 172-179
19. Saito, Y., Suzuki, M., Sato, T. A case of unilateral auditory neuropathy. In *Neuropathies of the Auditory and Vestibular Eighth Cranial Nerves*. 2009: 135-141
20. Zhang, Q.J., Lan, L., Shi, W. Unilateral auditory neuropathy spectrum disorder. *Acta otolaryngol*. 2012; 132:72-79
21. Petty, C., Huffman, A. Auditory Neuropathy: A Case of Near Misdiagnosis. *Pediat Therapeut*. 2014; 4(2):1-2.
22. Al-Shehri, A.M. Unilateral auditory neuropathy: case report. *Pak J Surg*. 2015; 31(2):149-150.
23. Basavaraj, V. Ethical guidelines for bio-behavioural research. Mysore: All India Institute of Speech and Hearing. 2009.
24. Vignesh SS, Jaya V, Muraleedharan A. Prevalence and audiological characteristics of auditory neuropathy spectrum disorder in pediatric population: a retrospective study. *Indian J Otolaryngol Head Neck Surg*. 2016; 68(2):196-201.
25. Raveh E, Buller N, Badrana O, Attias J. Auditory neuropathy: clinical characteristics and therapeutic approach. *Am J Otolaryngol*. 2007; 28(5):302-308.
26. Hood LJ, Berlin CI, Bordelon J, Rose K. Patients with auditory neuropathy/dysynchrony lack efferent suppression of transient evoked otoacoustic emissions. *J Am Acad Audiol*. 2003; 14(6):302-313.
27. Talaat HS, Kabel AH, Samy H, Elbadry M. Prevalence of auditory neuropathy (AN) among infants and young children with severe to profound hearing loss. *Int J Pediatr Otorhinolaryngol*. 2009; 73(7):937-939.

How to cite this article: Mohanty D, Roy R, Sahu P et.al. Unilateral auditory neuropathy spectrum disorder: a single case study. *Int J Health Sci Res*. 2019; 9(6):412-418.

\*\*\*\*\*