

Case Report

## Usefulness of Extended Audiological Test Battery for Identifying Unsafe Type of CSOM in A Non Hospital Audiology Set Ups- Single Case Study on Secondary Acquired Cholesteatoma

Prajna Bhat. J<sup>1</sup>, Shivali Appaiah. K<sup>2</sup>, Suresh Thontadarya<sup>3</sup>

<sup>1</sup>Visiting Faculty, Samvaad Institute of Speech and Hearing, Bangalore;

<sup>2</sup>PhD Candidate, Mcquire University, Australia

<sup>3</sup>Associate Professor and Research Coordinator, Dr S. R. Chandrashekhara Institute of Speech and Hearing, Bangalore University, Bangalore, India;

Corresponding Author: Prajna Bhat. J

### ABSTRACT

**Background:** The present paper highlights a single case study where inclusion of additional Immittance procedures such as Multifrequency tympanometry (MFT), Multicomponent (MCT) tympanometry along with single frequency tympanometry, reflexometry and other tests in a test battery approach helped in identifying a cholesteatoma / CSOM during our regular outpatient audiological procedures of a teaching college of speech and hearing.

**Method:** Pure tone audiometry, Single probe tone frequency tympanometry, MFT, MCT, Reflexometry and Bone Conduction Auditory brainstem response (BC-ABR) were carried out.

**Result and conclusion:** The results of Pure-tone audiometry test indicated Normal hearing sensitivity in left ear and a Profound mixed hearing loss in right ear. The single probe tone tympanometry revealed an 'As' type and an 'A' type tympanogram in the right and left ear respectively. MFT revealed a mass dominated pathology in the right ear and a normal resonance in the left ear which in turn correlated with the results of MCT. The threshold of right BC- ABR was obtained at 40dBnHL, which indicated cochlear hearing to be affected to a smaller degree as to be expected in advanced CSOM conditions. Compilation of results of test battery assists the Audiologist to draw the attention of the treating ENT specialist towards appropriate diagnosis, designing a suitable intervention plan, effective counselling and appropriate referrals.

**Key Words:** Cholesteatoma, MFT, MCT, BC-ABR

### BACKGROUND

Middle ear assessment is a regular component of audiological investigation even in non hospital based audiology centers. In India, people may approach audiology services directly and therefore may not always have had all necessary investigations for their hearing problems or may not have attended regular follow ups recommended by earlier physicians.

Therefore it may be common to see a client who approach for a routine hearing check up or suggestion on amplification but would require proper medical/ surgical treatment for their middle ear condition. An Audiologist need to be aware of techniques which helps him to identify non threatening type of conductive hearing losses from that of conditions which need immediate medical attention. This would help him to

counsel the client on need of consulting the ENT surgeon expert in that particular area. Cholesteatoma is one such condition and prevalence of it in population which do not seek medical services on a regular basis is high. Cholesteatoma is a progressive and destructive disease that occurs in the middle ear cleft and has the capacity to destroy the soft and hard tissue surrounding it. Acquired cholesteatoma are commoner to be seen in an audiology practice of semi urban or tertiary care hospitals. Both Primary and Secondary Acquired Cholesteatoma may be asymptomatic for a longer period of times i.e without discharge or discomfort and therefore the client may have discontinued medical treatment or have neglected to go for a follow up. Hearing impairment may be the only troubling problem for him/her.

Cost effective methods of investigations are required for developing countries. CSOM is considered as a public health emergency in some countries by WHO (WHO, 2004).<sup>[1]</sup> Berman (1995)<sup>[2]</sup> and Bluestein (1983)<sup>[3]</sup> reported that CSOM is prevalent in developing countries. The incidence is more in lower socioeconomic conditions (Ologe & Nwawalo, 2003).<sup>[4]</sup> WHO (2004)<sup>[1]</sup> also documents that many prevalent socio economic conditions like poverty, malnutrition etc contributes to this prevalence. Though India does not come under WHO listed countries of CSOM as a public health emergency, the prevalence figures are still high. The figures vary regionally, 6% in South India (Rupa, Jacob & Joseph, 1999),<sup>[5]</sup> to 15.3% in Haryana (Verma, et. al., 1995).<sup>[6]</sup> CSOM is also a major part of work of an audiology department in INDIA. Ramesh (2016)<sup>[7]</sup> reported that CSOM constituted 12.9% of total cases seen in Audiology department of AIISH, Mysore for a period of August 2014 to May 2015.

Diagnosis of cholesteatoma is often not a requirement of audiologist's routine work. Cytology, Radiological Investigations (CT Scans) microscopic examination of ear and observation of clinical signs are the methods an ENT Specialist often relies on

to identify the disease. Observation of marginal perforation or attic perforation and / or keratosis is often enough to rise suspicion for an ENT specialist. They rely on audiological evaluation to know the degree of damage to middle ear the disease has caused and whether inner ear is affected by disease process. Here we are discussing a case wherein no such prior information on disease process was available to the audiologist and the patient was also not aware of the medical condition underlying his hearing impairment. The patient had failed to follow up with ENT for many years probably due to absence of ear discharge and approached audiology facility for concern on hearing loss. Therefore alertness on audiologist's part in deciding to investigate the conductive hearing loss in a detail manner is essential, in the background of this patient's presentation of clinical details or lack of it.

In a general clinical set up, routine audiological evaluation includes pure-tone and speech audiometry, single component tympanometry and reflexometry. The information obtained through these routine procedures may not be sensitive enough to provide a complete clinical picture of the client's condition and the extent to which the disease has progressed. We incorporated three additional tests i.e. Multifrequency tympanometry (MFT), Multicomponent tympanometry (MCT) and Bone conduction auditory brainstem response (BC-ABR) CSOM. The patient had not consulted ENT in past many years as there was no recurrence of ear discharge or any other symptoms in ear. Unlike 226 Hz probe tone immittance, MCT can be more informative on the status of middle ear status (mass or space occupying lesion in middle ear). MFT also provides information regarding the resonant frequency of the middle ear and any change in the resonance frequency caused by the pathology. While BC thresholds on pure tone are seen as evidence of whether or not cochlea is affected, often CSOM itself can affect BC thresholds. BC-ABR therefore can help to concur with the

results of pure tone audiometry regarding the cochlear reserve gain. It enables us to know whether the disease has progressed to the cochlear region and the extent of progression.

The aim of the current study is an attempt to emphasize the role of an experienced Audiologist in assessment of CSOM by use of an extended Audiological test battery. Our recommendation is to utilize MCT / MFT routinely in all cases who present with history of ear discharge and / or conductive hearing loss on PTA, even though he/ she may not have ear discharge currently or just have 'As' type tympanogram on routine immittance testing.

### CASE PRESENTATION

A 23 year old female visited our institute with the complaint of reduced hearing sensitivity in the right ear. She reported of normal hearing sensitivity in the left ear. The patient reported that the hearing loss was noticed since one year and it was gradually progressing. She gave a history of discharge in right ear 8 years ago and she is symptom free for last two years. The client consulted an ENT Specialist recently for a routine check up during which a posterior superior retraction pocket and keratosis flakes were observed in the right ear. The ENT evaluation recommended routine audiological investigation for CSOM. He had guarded his decision on CT scan until later. As patient had economical constraints audiological investigations were the first line of investigation requested by the ENT. On noticing the degree of conductive loss as well as key points on history like duration of hearing loss and ENT findings or retraction pockets, it was decided to extend the test protocol to MFT, MCT and BC-ABR apart from routine speech audiometry, single frequency immittance measure and reflexometry.

### RESULTS

#### A. Pure-tone Audiometry test And Speech Audiometry Results:

Tests revealed Normal hearing sensitivity in left ear and Profound mixed hearing loss in right ear (Fig 1). Speech reception thresholds and speech recognition scores in the left ear was 5dBHL and 90% respectively. Severity of hearing loss was a deterrent to carry out these tests in right ear. Therefore, only speech awareness level was attempted with contralateral masking. The speech awareness threshold was 95 dBHL. Speech recognition scores were obtained for BC presentation of speech stimulus with BC vibrator placed on right mastoid and contralateral masking noise applied to left ear via insert transducer. The results showed scores to be 82% at 60 dB HL with masking noise being at 40 dB HL.

#### B. Immittance Audiometry results;

Single probe tone tympanometry revealed an 'As' type in right ear and an 'A' type tympanogram in the left ear respectively. Ipsilateral reflexes were absent in the right side and present in left ear. Contralateral reflexes were absent for both ears.

**C. MFT and MCT results:** On MFT, Resonant frequency was 600Hz in the right ear and 1000 Hz in the left ear. The results of MCT are presented in table 1, 2 and 3. The tympanic curve changed from reduced single peak at 226 Hz probe tone to multi peaked at higher probe tone frequencies. Results showed 3B1G pattern at 668Hz and 3B3G at 1000Hz. And the difference between the two outer peak of multi peak graphs were less than 75 dapa at 668 Hz and less than 150 dapa at 1000Hz.

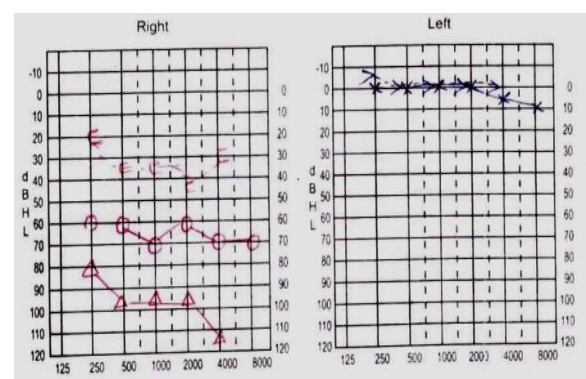


Figure1. Audiograms of right and left ear respectively

#### D. BC- ABR Results:

BC-ABR was carried out for the right ear using click stimuli at a repetition rate of 7.1 per sec using rarefaction polarity.

Contralateral masking noise was presented to left ear using insert transducer. Clear and replicable V<sup>th</sup> peak was obtained upto 40dBnHL (fig 2).

#### DISCUSSION

Routine Audiological tests showed that hearing was affected in right ear to a large degree and included both conductive and cochlear components. The degree of loss raised questions on cochlear reserve and extent of disease to have caused this degree of loss and progressive of the disease. Determining the extent to which hearing could be preserved with treatment and /or whether disease is potential enough to cause this level of loss was the clinical questions in need of answers.

The "As" type tympanogram on 226Hz immittance testing was not sufficient to explain the extent of hearing loss. As increase in stiffness alone cannot cause this degree of loss, further procedures in immittance audiometry were obviously be helpful in this scenario. BC ABR was included as a verification of thresholds, both BC and AC and specificity to validate the cochlear reserve to be as good as demonstrated on PTA. Middle ear pathology in some cases as in unsafe type of CSOM can affect BC threshold and therefore both BC ABR and BC speech recognition scores

would offer additional information on validity of AB gap seen on PTA.

MCT measures Susceptance and Conductance curves at three predefined probe frequencies and details the changes in admittance values for a range of ear canal pressures much like 226 Hz probe tone testing. The curves were correlated with different patterns described by Van Huysse's (1975). [8]

Generally an 'As' type tympanogram suggests increased stiffness of middle ear, a common findings in safe type of middle ear condition like otosclerosis, congestion of ear drum, ET dysfunction. In all these conditions MCT results would also continue to show increased stiffness of middle ear system, i.e. single peak curves for B, G and Y. However, in cases of CSOM of mass in middle ear space like in cholesteatoma, the MCT curves may change with probe frequencies. Our findings in the patient did support this view. The MCT curves showed 3B1G pattern at 660 Hz and 3B3G pattern at 1000Hz, both not expected in stiffness dominant middle ear. The results were suggestive of ossicular chain erosion which again correlated well with degree of hearing loss seen on PTA and the pattern of high frequencies more affected than low frequencies. The obvious misleading As type seen on 226Hz test may partly be due to cholesteatoma mass filling the ossicular chain space and therefore reducing the mobility of Tympanic membrane and ossicular chain. This was later confirmed by CT scan test.

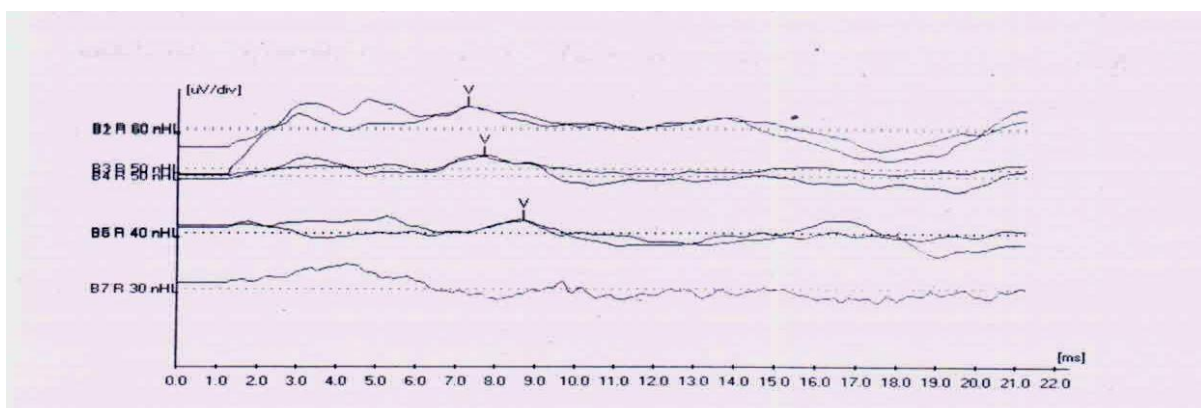


Figure 2. Masked BC-ABR of the right ear



**Table 1.MFT and MCT (Susceptance and Conductance components) results of Right ear**

MFT	MCT											
600 Hz	Probe tone freq	226Hz					678Hz			1000Hz		
	Pattern	1B1G		3B1G			3B1G			3B1G		
		B	G	B1	B2	B3	G	B1	B2	B3	G	
	Peak pressure (daPa)	-60	-60	-130	-70	5	-10	-256	-170	-95	-215	
Admittance (ml)	1.16	0.33	2.56	2.42	2.54	1.4	3.7	3.4	3.8	3.1		

**Table 2.MFT and MCT (Susceptance { B} and Conductance {G} components) results of Left ear**

MFT	MCT													
1000 Hz	Probe tone freq	226Hz					678Hz			1000Hz				
	Pattern	1B1G		3B1G			3B3G							
		B	G	B1	B2	B3	G	B1	B2	B3	G1	G2	G3	
	Peak pressure (daPa)	40	40	25	45	65	-5	-10	30	80	15	35	65	
Admittance (ml)	2.3	0.6	4.1	-0.3	3.9	1.2	3.9	0.8	4.6	5.4	3.2	5.7		

**Table 3. MCT values of Admittance (Y) components of both ears**

226 Hz	Right ear			Left ear		
	3Y			3Y		
	Y1	Y2	Y3	Y1	Y2	Y3
	-245	-160	-120	15	30	65
	4.8	4.4	4.4	6.4	3.3	5.7

The results of MCT did not fit a typical pattern of oscillator chain discontinuity as described by Van Huyse (1975). [8] He had proposed that the peak differences between the two outer peaks should be more than 100 dapa for 660 Hz and 150 dapa for 1000Hz. Therefore traumatic ossicular chain discontinuity was ruled out. The CT scan results of ossicular chain erosion and mass filling the cavity may partly explain the peculiar combination of findings on our tests of 226 hz and MCT. The G curve and compliance values of it were seen to rise above of compliance values of negative peak of B curve at higher frequencies. These results are confirmative of middle ear disease other than otosclerosis. (Conductance curves were higher than susceptance at middle ear peak pressure). Notching of admittance tympanogram (3Y) at 226 Hz in both ears strongly suggest the presence of a mass dominated middle ear.

MFT complemented these results as resonant frequency was reduced as one would expect in mass dominated middle ear. Table 1 & 2 shows the resonant frequency to be lower than normal range, in right ear alone.

In summary, the audiological tests showed evidence of unhealthy middle ear, the disease to have affected inner ear (reduced BC both on PTA and BC- ABR) and ossicular chain to be affected as in CSOM conditions. Therefore when all results are seen together, it correlates with progressive type of CSOM like that of cholesteatoma mass in middle ear. These results are less likely to be obtained in cases of OME or otosclerosis.

Erosion of ossicular chain due to the disease may have led to multipeaks on Y, B and G curve. The ossicular chain discontinuity alone would cause outer peaks of G and B curves to be differing from more than 75 dapa for 668Hz and 150 dapa for 1000 Hz

(Van Huyse, 1975). [8] Such was not the case in our results. This was probably due to cholesteatoma filling in for the ossicular chain and thereby adding some stiffness component as well. This also explains the “As” type seen on 226Hz probe tone. These findings were communicated to ENT and the patient underwent radiological testing. The results of CT Scan did confirm the initial suspicion raised by audiological investigation. There was evidence of erosion of ossicles and labyrinth. Also cholesteatoma shadow was evident in middle ear space.

Pure-tone audiometry is considered to be one of the most powerful test available to measure the hearing sensitivity in an individual. However, in the present case, it

conveyed information regarding the degree of hearing loss but not the cochlear reserve gain. Hence a BC-ABR was carried out. Presence of clear and replicable V<sup>th</sup> peak upto 40dBnHL indicated that cochlear response is affected to a certain extent but not totally absent. It confirmed the AB gap in this profound degree of hearing loss ear. BC-ABR results enable an Audiologist to inform the surgeon regarding presence of cochlear reserve gain. The surgeon can then operate in a way that further cochlear damage can be prevented while doing surgery for cholesteatoma.

### CONCLUSION

The present case report is expected to motivate all Audiologists as well as medical practitioners to utilize MCT, MFT tests in their test battery while investigating cases with CSOM. In semi urban set up a patient may seek audiological investigation directly e.g. needing hearing aid etc. CSOM can be asymptomatic for years and therefore they may not consult ENT specialist. Accurate identification of CSOM therefore may help direct these patients with unsafe type of CSOM or progressive type of CSOM to medical consultation. Though MFT and MCT are available for a long time now, there is reluctance to use them clinically. The present report shows that use of MFT and MCT was accurate in identifying mass lesion in middle ear. These tests can differentiate ordinary perforation from conditions of perforation with mass lesion in middle ear. Sometimes cases may not come to audiologists through ENT or the ENT may not have sophisticated equipment like microscopic observation of TM to identify risk factors of middle ear disease. Therefore audiologists should

explore possibility of ruling out middle ear disease in a more clearer way rather than limiting to “B” type or ear canal volume kind of observation. Also BC thresholds of puretone can be verified by BC ABR whenever required. Hopefully this study brings in some interest among fellow colleagues. Cholesteatoma is a serious middle ear condition which needs to be identified at the earliest and an experienced Audiologist can also raise suspicion of it due to availability of reliable assessment tools in the current scenario.

### REFERENCES

1. WHO (2004) Chronic Suppurative otitis media- Burden of Illness and Management Options. Geneva, Switzerland.
2. Berman S(1995) otitis media in developing countries . Pediatrics, 96(1), 126-31.
3. Bluestone C D & Kenna M A (1984): Chronic suppurative otitis media: antimicrobial therapy or surgery, pediatric annals, 13(5), 417-21
4. Ologe F E , & Nwawalo C C , (2002): prevalence of chronic suppurative otitis media (CSOM) in school children in rural community in Nigeria. The nigerian postgraduate medical journal, 9(2), 63 (6).
5. Rupa V, Jacob V, Joseph V (1999) : Chronic suppurative otitis media prevalence and practices in among rural south Indian children. International Journal of Pediatric otolaryngology 48 (3), 217-21.
6. Verma Ak et al (1995): Epidemiology of chronic suppurative otitis media and deafness in rural area and developing an intervention strategy. The Indian Journal of pediatrics 62(6), 725-29.
7. Ramesh, P L., (2016): Prevalence and Audiological characteristics of CSOM in individuals with conductive pathology reported to AIISH (2014-15). Unpublished Master's Dissertation, University of Mysore.
8. Vanhuysse V.J., Creten W.L., Camp K.J. (1975). On the W- Notching of tympanograms, *ScandAudiol.* 4, 45-50.

How to cite this article: Bhat JP, Appaiah. KS, Thontadarya S. Usefulness of extended audiological test battery for identifying unsafe type of CSOM in a non hospital audiology set ups- single case study on secondary acquired cholesteatoma. *Int J Health Sci Res.* 2019; 9(6):406-411.

\*\*\*\*\*