

Case Report

## **Traumatic Abdominal Wall Hernia with Bowel Perforation: A Rare Case Report**

Dr Tushar M. Gulbhile<sup>1</sup>, Dr Moses A. W. Ingt<sup>2</sup>, Dr Sunil B Magdum<sup>3</sup>

<sup>1</sup>Junior Resident (General Surgery), <sup>2</sup>Professor of Surgery, <sup>3</sup>Associate Professor of Surgery, Bharati Vidyapeeth (Deemed To Be) University Medical college and Hospital, Sangli.

Corresponding Author: Dr Tushar M. Gulbhile

### **ABSTRACT**

Traumatic abdominal wall hernia is resulting from direct trauma to the anterior abdominal wall. Such traumatic hernias are rare. We report a case of traumatic abdominal wall hernia with bowel perforation resulting from an injury sustained due to a bicycle handle, and discuss the management of such injuries. Here the patient had a high kinetic energy injury leading to traumatic abdominal wall hernia with intra abdominal complication.

**Keywords:** Traumatic abdominal wall hernia, , Handlebar hernia, Hernia repair

### **INTRODUCTION**

Abdominal wall hernias caused by direct blunt trauma objects like handlebar, fall from height, motor vehicle injuries etc and therefore called traumatic abdominal wall hernia, are a rare occurrence. We report a case of such hernia associated with significant intraabdominal injury. Some criteria have been proposed to identify traumatic hernias: absence of preexisting hernia in the same location, evidence of abdominal injury at presentation and immediate or delayed development of the hernia (usually close to the site of injury).<sup>[7]</sup> In our case, we had acute hernia with bowel perforation.

### **CASE REPORT**

An 11 yr male child presented to the casualty with complaints of severe pain in abdomen and one episode of vomiting. Patient had a history of blunt trauma to abdomen due to bicycle handle bar 2 hours prior. On examination patient was conscious, well oriented. Blood pressure

was 110/70mmHg, pulse was 102 per minute and respiratory rate was 20 per minute. Respiratory system, cardiovascular system and central nervous system were normal. Per Abdominal examination revealed Rt. lower abdominal swelling and a circular wound with central island of skin (Fig 2). Second abrasion was seen on right side below the umbilicus. There was localized tenderness and guarding. Abdominal examination showed on coughing increase in the swelling in the site of anterior abdominal wall injury. Our clinical diagnosis was Traumatic abdominal wall hernia. His haemoglobin 12 gm/dl, total counts: 6,400cumm. Blood urea: 17 mg%, Serum creatinine: 0.9 mg%. All other laboratory reports were within normal limits. Ultrasound of Abdomen and pelvis showed approx.17mm right paramedian rectus defect/tear (figure3) with herniation of omentum/bowel.

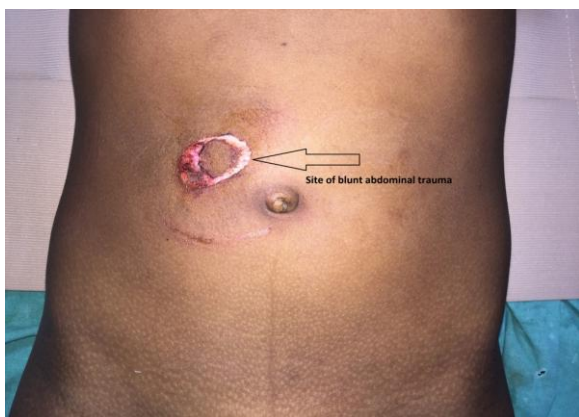

Figure 1 Site of blunt abdominal trauma (anterior view)

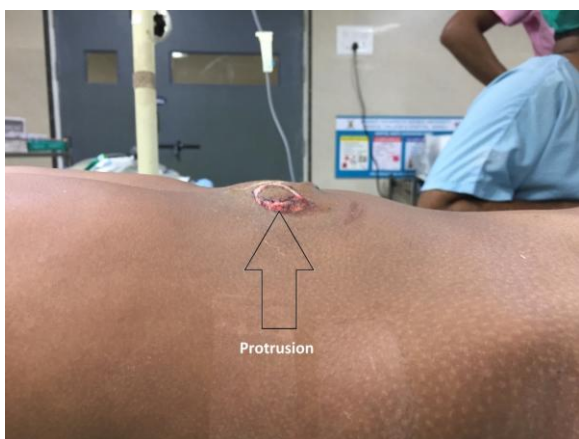

Figure 2: Showing lateral view of blunt abdominal trauma

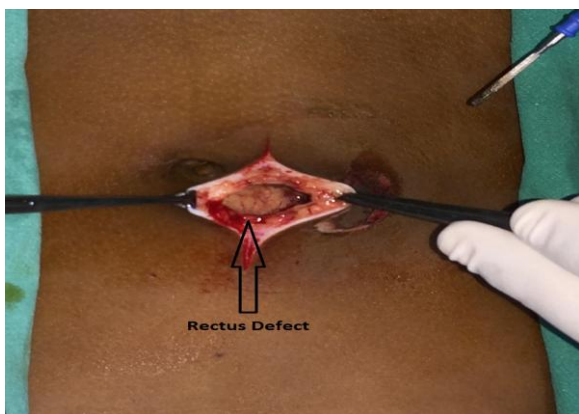


Figure 3 ; Showing rectus defect of size 3\*3 cm

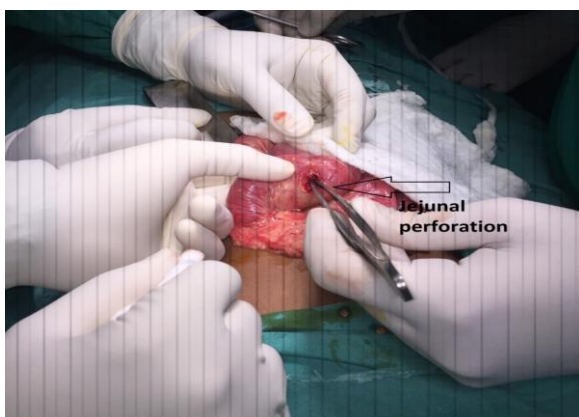


Figure 4 Showing 1\*1 jejunal perforation

In this case laparotomy. There was minimal hemorrhagic fluid in the abdomen. We found a 1cm of jejunal perforation (Fig 4). We did a primary closure of jejunal perforation and Mayo's repair of the hernial defect.

## DISCUSSION

Traumatic abdominal wall hernias are produced by the direct blunt trauma from an object that has insufficient force to penetrate the skin, yet able to disrupt the deeper tissues of muscles and fascia. This is possible because the skin is more elastic than the rest of the layers. [1] Woods classified TAWH in 3 major types. [2] Type 1 is high energy injuries due to motor vehicle, motorcycle accidents are associated with intra abdominal injuries are list common, Type 2 is Low energy injuries due to bicycle handle bar mostly without intraabdominal injuries are seen in young children and are more common. Type3 resulting from deceleration are seat belt injuries. Handlebar hernias are often under type I abdominal wall hernias and associated intra abdominal injuries are rare. [1,3,4]

The diagnosis is usually made on the basis of history and physical examination. However, ultrasonography and CT scans may be helpful in difficult cases. [5,6]

Some criteria have been proposed to identify traumatic hernias: absence of preexisting hernia in the same location, evidence of abdominal injury at presentation and immediate or delayed development of the hernia (usually close to the site of injury). [7] In our case, clinical picture and ultrasound findings confirmed the diagnosis.

With the exception of the rare case of thoracic handlebar hernia, [8] all other reported cases were related to the abdominal wall. The abdominal wall hernia is usually found at weak anatomical locations such as the region of the lower lateral abdomen to the rectus sheath. This explains that in the majority of the reported cases of handlebar hernia, including our case, the abdominal wall defect was in the lower abdomen. [3]

Only two cases were reported for the upper quadrant of the abdomen. [1] The abrupt increase in intraabdominal pressure is responsible for the poor correlation between the site of impact and the resultant defect.

The majority of the cases described with handlebar hernias were caused by low-energy mechanisms such as bicycle or motorcycle. Therefore, in most of the cases, there was no significant intraabdominal injury. [1,4,5] In few cases, including our case, the hernia was caused by high-energy mechanism such as motor-car accidents. [3,9] These cases have been reported with significant intraabdominal injury. The most commonly reported injuries were mesenteric and serosal tears. There are two possible mechanisms of blunt mesenteric injuries: (1) a crushing force applied to the bowel against the spine and (2) shearing forces of the bowel and mesentery along the lines of attachment. [3]

After dealing with all associated intraabdominal injuries, definitive treatment of these hernias mandates surgical exploration and prompt repair to prevent incarceration or strangulation. This repair can be performed with primary closure if the tissue allows or with prosthetic material if the defect is too large. [8,10] Debate exists regarding the local wound exploration vs. midline exploratory laparotomy to rule out the intraabdominal injuries. [11]

## CONCLUSION

Early clinical suspicion of traumatic abdominal wall hernia (handle bar) and confirmation with ultrasound or CECT abdomen is required. We should also think of associated intraabdominal injuries before planning for surgery.

## REFERENCES

1. Dimyan W, Robb J, MacKay C. Handlebar hernia. *J Trauma*. 1980;20:812–3. [PubMed]
2. Wood RJ, Ney AL, Bubrick MP. Traumatic abdominal hernia, a case report and review of literature. *Am Surg*. 1988;54:648-51.
3. Cheng S, Ko W, Liu C. Handlebar hernia: A misleading term. *Injury Extra*. 2005;36:309-11.
4. Chen HY, Sheu MH, Tseng LM. Bicycle-handlebar hernia: A rare traumatic abdominal wall hernia. *J Chin Med Assoc*. 2005;68:283-5. [PubMed]
5. Prada Arias M, Dargallo Carbonell T, Estevez Martinez E, Bautista Casanovas A, Varela Cives R. Handlebar hernia in children: Two cases and review of the literature. *Eur J Pediatr Surg*. 2004;14:133–6. [PubMed]
6. Mitchiner JC. Handlebar hernia: Diagnosis by abdominal computed tomography. *Ann Emerg Med*. 1990;19:812–3. [PubMed]
7. Sahdev P, Garramore RR, Jr, Desani B, Ferris V, Welch JP. Traumatic abdominal hernia: Report of three cases and review of the literature. *Am J Emerg Med*. 1992; 10:237–41. [PubMed]
8. Holmes JH, 4th, Hall RA, Schaller RT., Jr Thoracic handlebar hernia: Presentation and management. *J Trauma*. 2002;52:165–6. [PubMed]
9. Huang CW, Nee CH, Juan TK, Pan CK, Ker CG, Juan CC. Handlebar hernia with jejunal and duodenal injuries: A case report. *Kaohsiung J Med Sci*. 2004;20:461–4. [PubMed]
10. Jones BV, Sanchez JA, Vinh D. Acute traumatic abdominal wall hernia. *Am J Emerg Med*. 1989;7:667–8. [PubMed]
11. Perez VM, McDonald AD, Ghani A, Bleacher JH. Handlebar hernia: A rare traumatic abdominal wall hernia. *J Trauma*. 1998;44:568–70. [PubMed]

How to cite this article: Gulbhile TM, Ingty MAW, Magdum SB. Traumatic abdominal wall hernia with bowel perforation: a rare case report. *Int J Health Sci Res*. 2019; 9(5):459-461.

\*\*\*\*\*