

Case Report

## Job's Syndrome with Oral Manifestations- A Rare Case Report and Review of Literature

Dr Shalvi Vora<sup>1</sup>, Dr Freny Karjodkar<sup>2</sup>, Dr Kaustubh Sansare<sup>2</sup>,  
Dr Sunita Patankar<sup>2</sup>

<sup>1</sup>Post Graduate Student, <sup>2</sup>Prof. and Head,  
Department of Oral Medicine, Nair Hospital Dental College, Mumbai

Corresponding Author: Dr Shalvi Vora

### ABSTRACT

Job's Syndrome also known as hyperimmunoglobulin E syndrome (HIES), is a rare primary immunodeficiency characterized by eczema, recurrent skin and lung infections, elevated serum IgE, and connective tissue and skeletal abnormalities. It is a multisystem disease affecting dentition, skeleton, connective tissues. Patients suffering from this syndrome may show characteristic facial appearance and many oral manifestations like high arched palate, depapillated tongue, variations in oral gingiva and mucosa. Here we present a rare case of Job's syndrome in 12 year old boy having Characteristic Clinical features and rare Oral manifestations

**Key-words:** Job's Syndrome, Hyperimmunoglobulin E Syndrome, Ig E, Oral manifestations

**Key Messages:** As Job's syndrome patients may show Oral manifestations like severe gingivitis and periodontitis; early detection and treatment will help to prevent further progression of condition.

### INTRODUCTION

Job's Syndrome also known as Hyperimmunoglobulin E syndrome (HIES), is a rare primary immunodeficiency characterized by eczema, recurrent skin and lung infections, elevated serum IgE, and connective tissue and skeletal abnormalities. [1]

It is a multisystem disorder that affects the dentition, skeleton, connective tissues and immune system. [2]

Individuals with HIES (Job's syndrome) share a characteristic facial appearance and many oral manifestations like retained primary dentition, a high-arched palate, variations of the oral mucosa and gingiva, and recurrent oral candidiasis. [3]

As the disease is rare and the exact incidence is not known, only few reports are available in literature. [4] The HIES diagnosis is still based on the patient's

clinical and laboratory features, as no specific diagnostic test is available. [5-7]

Little is known about oral manifestations of this syndrome. The purpose of this report was to describe a case of 12 year old boy with suspected case of Hyperimmunoglobulin E syndrome having oral manifestations like severe gingivitis and periodontitis.

### CASE HISTORY

A 12year old patient reported to department of Oral medicine and radiology with chief complaint of pain and bleeding gums in upper and lower front teeth region. Patient gave history of recurrent skin infections and lung infection. Past medical history revealed repeated hospitalization due to pneumonia.

General physical examination revealed skin rashes, rough facial skin, scars due to repeated skin abscesses (Figure 2),

prominent forehead, angular cheilitis, broad nasal bridge with wide spaced eyes, wide fleshy nasal tip. Overall appearance of face was like “Old man appearance.” (Figure 1)

Intra oral examination revealed severe gingivitis with localized periodontitis with respect to four mandibular incisors. (Figure 3)

Depapillation of tongue, high arched palate, poor oral hygiene was noted

Caries noted with both the mandibular first molars.

Based on general physical examination and past medical history

provisional diagnosis was made as Hyperimmunoglobulin E syndrome. Patient was advised for Ig E levels and Panoramic Radiograph.

Panoramic Radiograph showed caries with respect to right maxillary first molar, right and left mandibular first molars. Interdental alveolar bone loss noted with respect to four mandibular incisors and all four first molars. (Figure 5)

Immunoglobulin E levels were increased by two and half folds. (Figure 4)

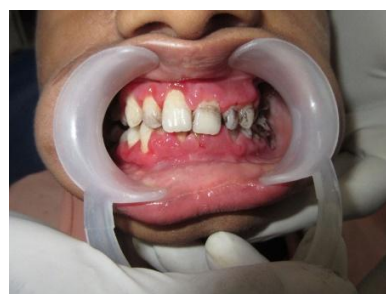
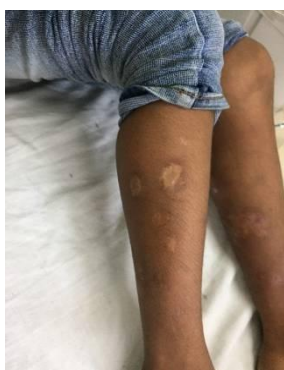
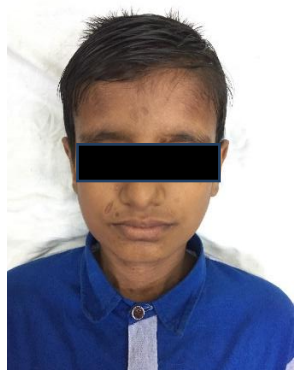Figure1- Extra Oral picture showing scars on facial skin, overall Old man appearance

Figure 2- Extra oral picture showing scars on legs

Figure 3-Intra oral picture showing gingivitis and periodontitis

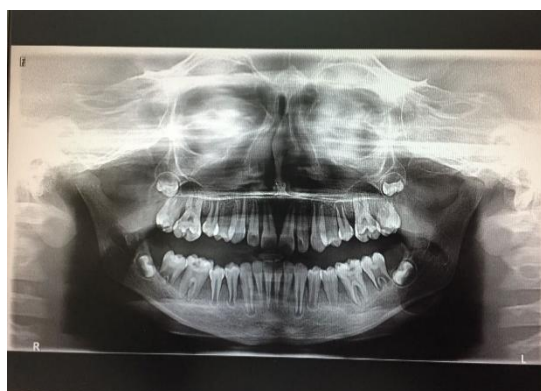


Figure 4- Increased immunoglobulin E levels by two and half folds

Figure 5- Panoramic Radiograph

## DISCUSSION

Job's syndrome was first described by Davis and colleagues (1966) in two sisters. He described a triad of eczematous dermatitis, recurrent sinopulmonary and

staphylococcal skin infections that distinctly lacked warmth, erythema and tenderness. [5]

In 1972, Buckley and colleagues further described this syndrome, reported distinctive facial features and an elevated

levels of IgE They termed the condition as Buckley's syndrome. [6,7]

Charon (1985) reported a higher incidence of thrush, gingivitis and plaque in a group of patients with Job's syndrome. [8] These findings are similar with our case as in this case patient had severe gingivitis and periodontitis. Remmer *et al.* (2004) reported that individuals with the autosomal dominant form of HIES have skeletal and dental abnormalities, and those with the recessive form do not have these findings. [3]

Until 2007, two distinctive clinical patterns of the disease as Autosomal Dominant (AD) and Autosomal Recessive (AR) and their definitive aetiological patterns, this syndrome was remaining as a major immune deficiency of unknown genetic aetiology which leads to the associated immune dysfunction. [4,6]

The cause of AD is missense or in-frame deletions resulting in one amino acid change or loss in Signal Transducer and Activator of Transcription 3 (STAT3) The occurrence of AR form is due to (Dedicator of Cytokinesis 8) DOC mutation. [6]

Although the high IgE levels is an initial presentation of the patients affected with AD pattern, eczema and recurrent skin and lung infections, other immunologic and non-immunologic manifestations follows in the later span of life. [6]

New born rash, eczema, boils, recurrent pneumonias, pneumatocoles, mucocutaneous candidiasis, peak serum IgE, eosinophilia and an increased risk of lymphoma these are various immunologic manifestations which can be seen in individuals suffering from HIES. Non-immunologic manifestations may include retention of primary tooth, coarse facial features, minimal trauma fractures, scoliosis (>10 degrees), hyper-extensibility, oral mucosal and gingival abnormalities, hyper-intensities on brain Magnetic Resonance Imaging (MRI), Chiari I malformations, craniosynostosis and arterial aneurysms

Facial asymmetry, a fleshy nasal tip, deep-set eyes, and a prominent forehead are the common features that can be seen in

these patients of HIES. These features are also noticed in the present case. Known oral manifestations associated with HIES are gingivitis periodontitis which were also seen in present case.

The most consistent laboratory abnormalities in HIES are high serum IgE. Normal range of Ig E for age 10 to 15 years is 200 IU/ml. In present case serum Ig E levels were elevated upto 546.9 IU/ml

No specific diagnostic test is available for HIES hence diagnosis is based on patients clinical and laboratory investigations. A HIES scoring system developed at the national institute of health to phenotype patients with Autosomal Dominant HIES is helpful. [9]

This child has clinical and laboratory features consistent with HIES. Having unaffected, consanguineous parents suggest the autosomal-recessive form of HIES in the present case

Control and resolutions of the rash typically occur with anti-staphylococcal antibiotics or topical therapies, such as bathing in diluted bleach or swimming in chlorinated pools. Other modes of management include local debridement, surgical incision and drainage of infectious lesion. [6]

## REFERENCES

1. Deepa D, Kumar KV, Joshi CS, Kumar S, Pandey A. Fungal infection of gingiva in a patient with hyperimmunoglobulin-E (Job's) syndrome. *J Indian Soc Periodontol.* 2012 Apr;16(2):256-60.
2. Sankar AS, Kumar MM, Samata Y, Reddy KS. Hyper IgE Disorder Associated with Multiple Fused Primary Teeth: A Rare Clinical Occurrence. *Int J Clin Pediatr Dent.* 2010 Sep-Dec;3(3):215-8
3. Remmer ED, Puck JM, Holland SM, Schmitt M, Weiss M, Frosch M, et al. Autosomal recessive hyperimmunoglobulin E syndrome. A distinct disease entity. *J Pediatr.* 2004;144:93-9
4. Holland SM, DeLeo FR, Elloumi HZ, Hsu AP, Uzel G, Brodsky N, et al. STAT3 mutations in the hyper-IgE syndrome. *N Engl J Med.* 2007;18:1608-19.

5. Davis SD, Schaller J, Wedgewood RJ. Job's syndrome. Recurrent, "cold", staphylococcal abscesses. *Lancet*. 1966;1: 1013–15
6. Freeman AF, Domingo DL, Holland SM. Hyper IgE (Job's) syndrome: A primary immune deficiency with oral manifestations. *Oral Diseases*. 2009;15:2–7.
7. Freeman AF, Holland SM. The hyper IgE syndrome. *Immunol Allergy Clin North Am*. 2008;28:277.
8. Charon JA, Mergenhagen SE, Gallin JI. Gingivitis and oral ulceration in patients with neutrophil dysfunction. *J Oral Pathol*. 1985;14:150–5.
9. Tsang P, Derkson G, Priddy R, Junker AK, Slots J, Larjava H. Severe periodontitis in a 5-year-old girl with hyperimmunoglobulin E syndrome. *Pediatr Dent*. 2005 Jan-Feb; 27(1):68–73

How to cite this article: Vora S, Karjodkar F, Sansare K et.al. Job's syndrome with oral manifestations- a rare case report and review of literature. *Int J Health Sci Res*. 2019; 9(5):429-432.

\*\*\*\*\*