

Case Report

Langerhans Cell Histiocytosis of Jaw in Pediatric Patient: A Rare Case Report

Neha Verma¹, Adit Srivastav², Naresh Kumar Sharma³, Kanupriya Gupta⁴

¹Senior Resident, ²Professor, MDS (Oral medicine and Radiology)
Unit of Oral Medicine and Radiology, Faculty of Dental Sciences, Institute Of Medical Sciences, Banaras Hindu University, Varanasi.

³Professor, ⁴Senior Research Fellow,
MDS (Oral and maxillofacial pathology), Unit of Oral and Maxillofacial Surgery, Faculty of Dental Sciences, Institute Of Medical Sciences, Banaras Hindu University, Varanasi.

Corresponding Author: Neha Verma

ABSTRACT

Langerhans cell histiocytosis is a rare pathology of immune cells histiocytes. There is clonal proliferation of histiocytes affecting axial skeleton bones like skull, jaw, ribs, spine, femur and pelvis. This proliferation leads to osteolytic lesions in bones. Diagnosing patients with this disease is challenging as it encompasses features of several other infective, inflammatory and neoplastic conditions.

Keywords- eosinophilic granuloma, langerhans cell histiocytosis, histiocytes, osteolytic lesions.

INTRODUCTION

Langerhans cell histiocytosis (LCH) is a rare disease involving histiocytes (Langerhans cell) activation and proliferation which affects bones. It is seen predominantly in pediatric population with incidence of 2 to 9 cases per million annually whereas only 1 case per 560,000 in adult population. [1]

Lichtenstein classified LCH into three clinical categories depending upon the age of individual on first appearance of disease and distribution:

- 1) Chronic Focal LCH (Eosinophilic Granuloma) – This presents as a uni- or multifocal lesion involving a single or multiple bones with or without involvement of soft tissue, with no systemic involvement and occurring at any age,
- 2) Chronic Diffuse LCH (Hand-Schüller-Christian disease) – This is seen in children or young adults with the typical triad of

exophthalmos, osteolytic lesions involving cranium and diabetes insipidus.

3) Acute Disseminated LCH (Letterer-Siwe disease) - This appears under the age of three years. It involves multiple organs and systems like liver, lung, lymph nodes, skin, bone and bone marrow. It has poor prognosis and is often fatal. [2]

LCH affects bone metabolism causing osteolytic lesions in low mineral density bones. Though pathogenesis of LCH is unclear but role of various inflammatory mediators is implicated. Interleukins (ILs), tumor necrosis factor α , receptor activator of NF- κ B (RANK), RANKL, osteoprotegerin (OPG), periostin and sclerostin are some of major molecules involved in LCH progression. RANKL and OPG control bone homeostasis through osteoclasts and also activate immune cells. [1]

LCH commonly involves the skull, long bones and the ribs. In facial bone it

affects mandibular jaw in the molar region than the maxilla. [3]

CASE REPORT

A 4 year old male patient reported in the department with swelling in right and left lower jaw since 6 months. . [Fig.1]

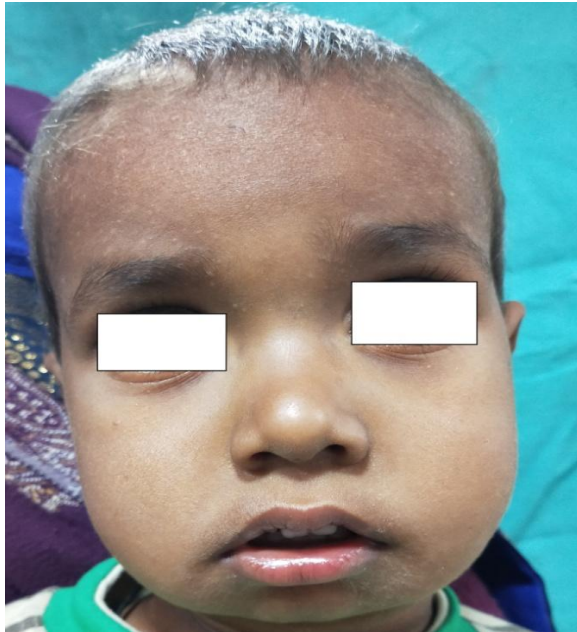

Fig.1 extra oral picture showing bilateral mandibular swelling

On intraoral examination deciduous right mandibular canine was displaced there was mobility of alveolus of right anterior mandible. [Fig.2]

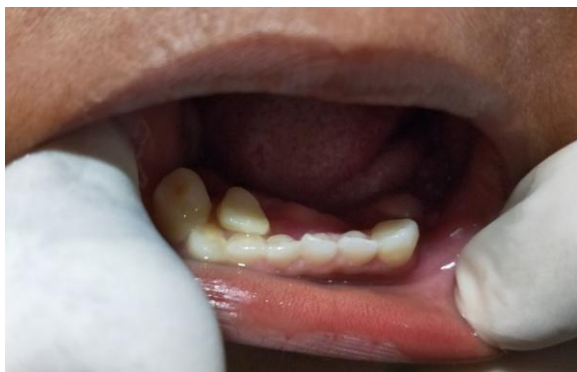

Fig. 2 intraoral picture showing displaced right mandibular deciduous canine

Associated swelling on bilateral posterior mandibular region was non tender on palpation. There was no history of fever. Patient was uncooperative for general radiographic examination so a CT scan was performed under sedation. CT showed

expansile osteolytic lesion in the bilateral body of mandible. [fig.3] with pathological fracture in right mandibular body region. [fig.4]

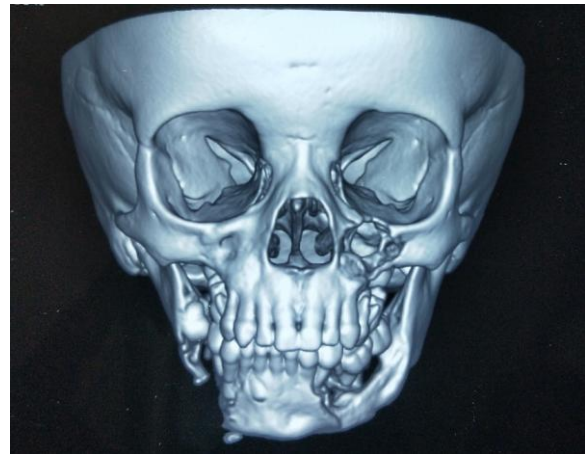


fig.3 3D reconstruction showing osteolytic lesion bilateral mandibular body region.

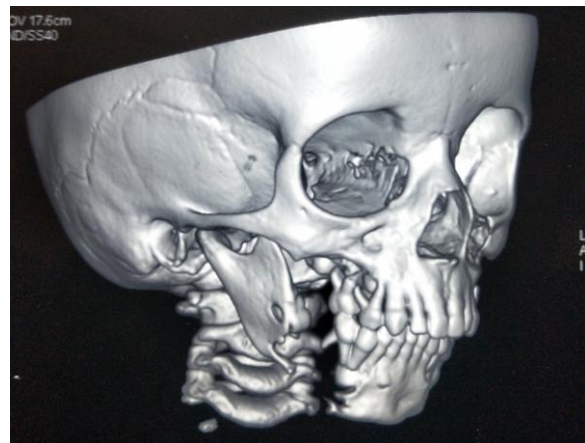


fig.4 3D reconstruction showing pathological fracture in right mandibular region

On histopathological examination diffuse infiltration of large, pale staining mononuclear cells resembling histiocytes with interspersed eosinophils were seen. Immunohistopathology showed positive result for CD1a marker and CD207 for Langerhans cells. This confirmed the diagnosis of Langerhans cell histiocytosis. Patient was planned for surgery for which he did not return.

DISCUSSION

Langerhans cell histiocytosis is rare immune cell pathology. Though LCH is may remain asymptomatic only to be discovered on radiographic examination accidentally, but it may present with

progressively growing localized swelling, pain with tenderness in the region of involvement. Associated low grade fevers, raised erythrocyte sedimentation rate with slight leukocytosis are other features of this disease. [4,5]

Langerhans cell histiocytosis presents a diagnostic challenge especially in pediatric patients. It is often confused with focal infective lesions and diseases with similar presentations like osteomyelitis, odontogenic cysts, primary bone tumours and lymphoma. Confirmation by immunohistochemistry becomes important to rule out other possible diseases. CD1a, CD207 and S-100 are positive markers for Langerhans cell histiocytosis. [6]

CONCLUSION

Langerhans cell histiocytosis is a disease which cannot be identified specifically by clinical or radiographic examination only, confirmation by immunohistochemistry is important for its prompt diagnosis and management.

REFERENCES

1. Anastasilakis, A. D., Tsoli, M., Kaltsas, G., Makras, P. Bone metabolism in Langerhans cell histiocytosis. *Endocrine connections* 2018;7(7):R246-R253.
2. Kannan, K., Alwithanani, N., Salama, M., Kumar, M., Uthappa, R., Ahamed, M. Eosinophilic Granuloma in Jaw Bone: A Pare Pediatric Case Report. *Ethiopian journal of health sciences*, 2016;26(5):487-490.
3. Jindal, M., Sharma, V. K., Ahmed, I., Agrawal, A. Langerhans cell histiocytosis of maxilla and mandible in 6 years old child: a case report. *International journal of clinical pediatric dentistry* (2009);2(2): 45-9.
4. dos Anjos Pontual ML, da Silveira MM, de Assis Silva Lima F, et al. Eosinophilic granuloma in the jaws. *Oral Surg Oral Med Oral Pathol Oral Radiol Endod* 2007;104:e47-51
5. Huysse WCJ, Hogendoorn RC, Bloem JL, et al. Eosinophilic granuloma of the skull. *JBR-BTR* 2006;89:134-5
6. Sherwani, R. K., Akhtar, K., Qadri, S., Ray, P. S. Eosinophilic granuloma of the mandible: a diagnostic dilemma. *BMJ case reports*, 2014, bcr2013200274. doi:10.1136/bcr-2013-200274

How to cite this article: Verma N, Srivastav A, Sharma NK et.al. Langerhans cell histiocytosis of jaw in pediatric patient: a rare case report. *Int J Health Sci Res.* 2019; 9(5):426-428.
