

A Study of the Anatomical Variation and Clinical Considerations of Greater Palatine Foramen in Adult Human Skulls of North Indian Population

Dalvinder Singh¹, Poonam Patnaik², Neha Gupta³

¹Professor, ²Associate Professor, Department of Anatomy, Faculty of Dentistry, Jamia Millia Islamia, Delhi

³Professor, Sudha Rustagi College of Dental Science & Research Institute, Faridabad, Haryana -121002

Corresponding Author: Dalvinder Singh

ABSTRACT

The greater palatine foramen conducts the greater palatine nerve, which is responsible for the innervation of the posterior hard palate. The morphometric knowledge of the greater palatine foramen is essential for anaesthetic procedures required in maxillofacial surgical procedures.

The aim of this study was to assess Morphometry and morphology of the greater palatine foramen in dry skulls of adults from north India. The study was conducted in 78 adult, dried, unsexed skulls of the north Indian population. All the skulls studied were normal with fully erupted third molars and free from any pathological changes. The dimension between greater palatine foramen to mid sagittal plane, incisive fossa and posterior border of hard palate were analyzed using a vernier caliper and a divider. The position, shape and direction of greater palatine foramen with its variations were also noted on both sides. In the present study the mean distance of the greater palatine foramen from mid sagittal plane of the palate was 14.45 ± 1.25 mm and 14.66 ± 1.13 mm on the right and left sides respectively, and from the incisive fossa was 36.91 ± 2.39 mm on the right side and 36.97 ± 2.66 mm on the left side. The mean distance of the greater palatine foramen to posterior border of hard palate was 4.75 ± 0.95 mm and 4.43 ± 1.07 mm on the right and left sides respectively. In 80.77% skulls the shape of the foramen was found to be oval whereas in 19.23% skulls it was round. In 76.92% skulls greater palatine foramen was located opposite to the 3rd maxillary molar, in 19.87% skulls between 2nd and 3rd molar, in 3.21% skulls distal to the 3rd molar. None of greater palatine foramen was located opposite to 2nd molar. In 66.03% skulls the foramen was directed anteromedial, in 25.64% skulls anterolateral and in 8.33% skulls it was directed anteriorly. The average number of lesser palatine foramen observed was 1.56 ± 0.67 on right and 1.29 ± 0.48 on left side of skull.

These observations about the relative anatomical position of greater palatine foramen can be utilized for anthropological studies, ethnic & racial classification of crania, greater palatine nerve block & surgical procedures in hard palate.

Key words: greater palatine foramen, hard palate, greater palatine canal, maxillary nerve block, molar teeth

INTRODUCTION

The hard palate is the horizontal bony plate formed by the palatine process of the maxilla and horizontal plate of palatine bone. It forms the roof of the oral cavity and floor of the nasal cavity. The greater

palatine foramen is an important anatomical landmark present on the posterolateral aspect of the hard palate. It is the lower aperture of the greater palatine canal, through which passes the greater palatine nerve and vessels. The greater palatine

nerve is a branch of maxillary division of the trigeminal nerve responsible for the innervation of the posterior part of hard palate. [1-2]

The greater palatine nerve block is common during procedures on the maxillary teeth and palate, however the common problem reported for this application is not easy to locate the exact location of the foramen, thus providing insufficient anaesthesia solution. [3] The foramen is also essential for the access to the palatine canal for reaching the pterygopalatine ganglion. [4-5] This method is high in success rate with minimum risk for obtaining a maxillary block. [6] Another advantage of this is the fact that the needle traverses the shortest route of any technique to block the maxillary nerve. [7-8] Studies have shown that the greater palatine neurovascular bundle is the most critical structure to be identified during subepithelial connective tissue palatal graft procedures. Additionally, in children with cleft palate, a greater palatine nerve block produces the most effective, consistent and prolonged analgesia after palatoplasty. [8-10]

There are varying opinions about the location of the greater palatine foramen in most of the books for example, it is termed near the lateral palatal border, [1] in the posterolateral border, [11] opposite the second maxillary molar, [12] between maxillary second and third molar [13] or opposite the maxillary third molar. [14] In addition, it is suggested that the location and number of greater palatine foramen could differ due to the difference between the ethnic groups. [15-19]

The key to successfully block the maxillary and the greater palatine nerves is accurate localization of the greater palatine foramen. Thus, the present study was carried out to study the morphometric evaluation and morphology of the greater palatine foramen in dry skulls of north Indian population to establish its more precise location. This would assist clinicians in consistently reliably locating the foramen.

MATERIALS AND METHODS

The study was conducted on 78 human adult skulls of unknown gender, obtained from the Department of Anatomy, Faculty of Dentistry, Jamia Millia Islamia University, Delhi, and Sudha Rustagi College of Dental Science & Research Institute, Faridabad (Haryana), India. All the skulls used for the study were dry, complete & showed presence of third molar either dentate or edentate. Skulls with damaged, mutilated and deformed hardpalate were excluded from the present study. The following measurements were taken bilaterally in all the skulls using vernier caliper and divider (Fig. 1):-

1. Distance between the medial edge of greater palatine foramen (GrPF) to the mid sagittal plane (MSP) → GrPF-MSP.
2. Distance between the anterior edge of GrPF to the posterior boundary of incisive fossa (IF) → GrPF-IF.
3. Distance between the posterior edge of GrPF to the point of maximum concavity of the posterior border of hard palate (PBHP) → GrPF-PBHP.
4. Shape of the greater palatine foramen → it was recorded as oval, round or irregular.
5. Location of the GrPF in relation to maxillary molar teeth.
6. Direction of the opening of the greater palatine canal into the oral cavity → for determining the direction of opening of the foramen on the palate, a 26 gauge needle was inserted into the greater palatine foramen. The directions were recorded as: anterolateral, anteromedially and anteriorly.
7. Number of lesser palatine foramina (LPF).

For all the values measured, the mean and the standard deviation were calculated individually for right and left sides. All the findings were tabulated and analyzed statistically using student's t test. Statistical differences were considered significant when the P value was less than 0.05.

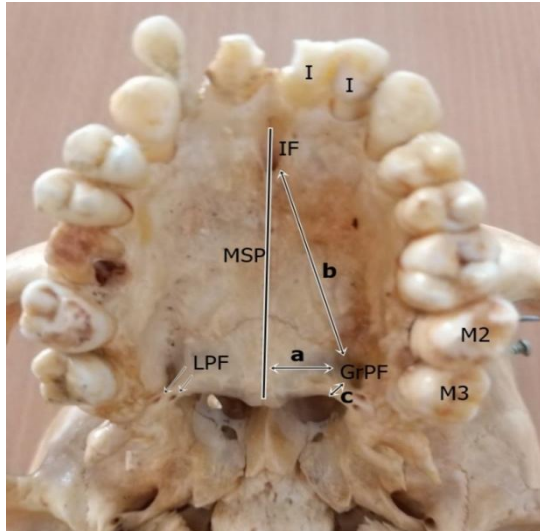


Figure 1. Photograph showing measurement of greater palatine foramen (GrPF) from various bony landmarks:

- a- Distance between GrPF and midsagittal plane (MSP).
 - b- Distance between GrPF and incisive fossa (IF).
 - c- Distance between GrPF and posterior border of hard palate.
- LPF→ Lesser palatine foramen, M3→ third maxillary molar, M2→ second maxillary molar, I→ incisor tooth

RESULT

All the measurements were executed separately for the right and left side of the skulls. No statistically significant difference

was observed between the right and left side for the distance between medial edge of greater palatine foramen and mid sagittal plane, distance between the anterior edge of greater palatine foramen from the posterior boundary of incisive foramen and distance of posterior edge of greater palatine foramen from posterior border of hard palate (Fig. 2).

The average distance of medial edge of greater palatine foramen from midline maxillary suture was 14.45 ± 1.25 mm on the right side and 14.66 ± 1.13 mm on the left side. The average distance between the anterior edge of greater palatine foramen and the posterior margin of incisive foramen was 36.91 ± 2.39 mm on the right side and 36.97 ± 2.66 mm on the left side. The average distance of posterior edge of greater palatine foramen from posterior border of hard palate on the right side was 4.75 ± 0.95 mm and on the left side was 4.43 ± 1.07 mm (Table 1).

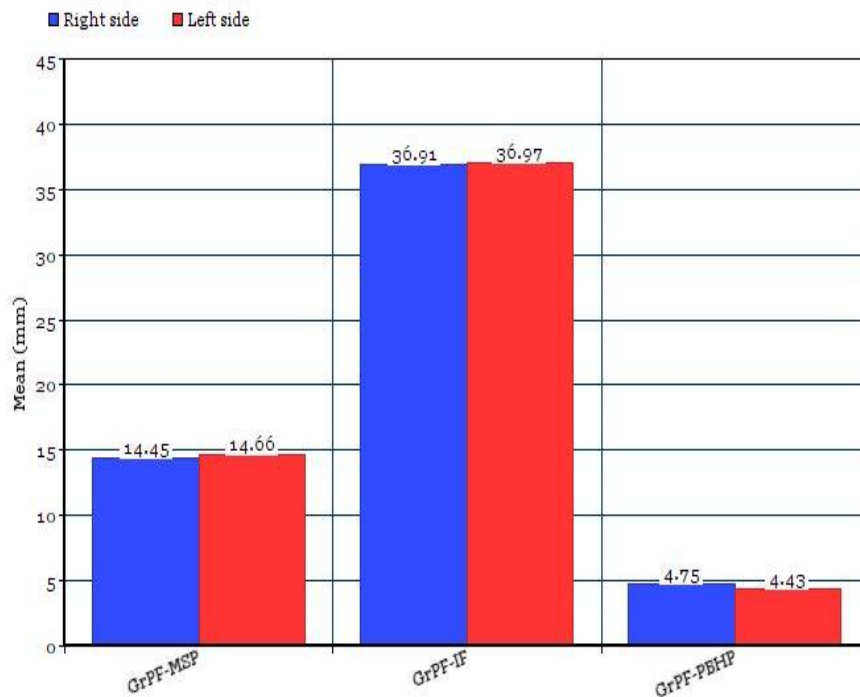


Figure 2. Bar diagram showing the distance of greater palatine foramen (GrPF) from various bony landmarks on right and left sides of skull.

- GrPF-MSP= Distance between GrPF and midsagittal plane (MSP).
- GrPF-IF= Distance between GrPF and incisive fossa (IF).
- GrPF-PBHP= Distance between GrPF and posterior border of hard palate.

Table 1.The distance of the greater palatine foramen (GrPF) from the mid sagittal plane, posterior boundary of incisive fossa and posterior border of hard palate.

parameter	Right	Left	Total	p-value
	Mean±SD (min-max)	Mean±SD (min-max)	Mean±SD (min-max)	
GrPF to mid sagittal plane(mm)	14.45±1.25 (12.00-16.28)	14.66±1.13 (11.52-16.12)	14.55±1.20	0.271,ns*
GrPF to posterior boundary of incisive fossa (mm)	36.91±2.39 (32.74-40.68)	36.97±2.66 (31.52-41.12)	36.94±2.53	0.883,ns
GrPF to posterior border of hard palate (mm)	4.75±0.95 (3.22-7.42)	4.43±1.07 (3.06-7.84)	4.59±1.03	0.051, ns

p<0.05 was considered statistically significant. *ns: not statistically significant

The shape of greater palatine foramen was oval in 80.77% of cases, whereas it was round in 19.23 % cases. The relationship of the greater palatine foramen to the maxillary molars was variable. It was noted that in 76.92% of skulls the greater palatine foramen was located opposite the third maxillary molars, in 19.87% of skulls it was located between the second and third molars and in 3.21% of skulls was situated beyond the third molar. No foramen was observed opposite the maxillary second molar. The greater palatine foramen was

present in all the skulls and the opening of greater palatine foramen on the palate was directed anteromedially in 66.03% of cases. It was directed anterolaterally in 25.64% while directed anteriorly in 8.33% of cases. The numbers of lesser palatine foramen were not symmetrical on either side and differed from zero to three. It was present on the right side in all the skulls, but it was absent on the left side in one skull. The mean number of lesser palatine foramen observed was 1.56±0.67 on right and 1.29 ±0.48 on left side (Table 2).

Table 2. Showing observations regarding non-metric parameters of greater palatine foramen.

		Right side	Left side	Total
A	Shape of the greater palatine foramen			
1	Oval	83.33%	78.21%	80.77%
2	Round	16.67%	21.79%	19.23%
3	Irregular	0%	0%	0%
B	Location of greater palatine foramen with respect to maxillary molars			
1	Opposite 2 nd molar	0%	0%	0%
2	Junction of 2 nd & 3 rd molar	15.38%	24.36%	19.87%
3	Opposite 3 rd molar	82.05%	71.79%	76.92%
4	Behind 3 rd molar	2.56%	3.85%	3.21%
C	Direction of opening of greater palatine foramen into the oral cavity			
1	Anteromedial	67.95%	64.10%	66.03%
2	Anterolateral	26.92%	24.36%	25.64%
3	anteriorly	5.13%	11.54%	8.33%
D	Number of lesser palatine foramen (LPF)			
1	Skulls with no LPF	0%	1.28%	0.64%
2	1 LPF	53.85%	60.26%	57.05%
3	2 LPF	35.90%	34.62%	35.26%
4	3 LPF	10.26%	3.85%	7.05%
5	Mean LPF count	1.56±0.67	1.29±0.48	1.43±0.63

DISCUSSION

The greater palatine nerve has to be blocked (GPN block) during various dental procedures and oral operations including palate repair. The greater palatine foramen is additionally used to give local injection into the greater palatine canal to regulate posterior bleeding in septorhinoplasty and sinus surgeries. [3,20] Kamath et al. [21] conducted a prospective randomized trial and observed that GPN block had several

advantages such as superior recovery, better pain scores and good post-operative analgesia. It's additionally easier to perform with a good success rate. Standard anatomy and surgical books provide general information about the location of greater palatine foramen, but there have been difficulties with surgery in the region because of lack of data on certain parameters. [22-24] In recent years, studies were carried out attracting attention to the

fact that greater palatine foramen localization could be a clinically important anatomical point. [23, 24] Additionally, the possibility of stimulating the pterygopalatine ganglion through greater palatine foramen also resulted in getting more attention. [25-27] Although similar results were obtained in the studies carried out in Europe, but significant variations were found by Indian researchers in their studies that were made on the same population group. [28-31] This indicates that even in the same population group broad anatomical variations can occur. The route of choice to block the maxillary nerve is through the greater palatine canal, which is accessed through the greater palatine foramen. This is needed in cases of repair of maxillary trauma, elevation of the maxillary sinus for dental implants and in treatment of chronic maxillofacial pain syndromes. Therefore, for dentists, oral maxillofacial surgeons and otorhinolaryngologists the precise location of the greater palatine foramen will be of huge importance. The present study assessed the relative anatomical position of the greater palatine foramen in north Indian population.

The mid sagittal plane is easily recognizable in patients owing to the presence of an overlying pale strip of mucosa. Hence, the distance of greater palatine foramen from mid sagittal plane becomes an easy landmark to locate the greater palatine foramen. In the present study, it was observed that the mean distance of greater palatine foramen to mid sagittal plane was 14.45 ± 1.25 mm on right side and 14.66 ± 1.13 mm on left side. Kumar A et al. [22] noted the same distance as 14.3 ± 1.42 mm and 14.4 ± 1.27 mm respectively on right and left side in (Punjab) Indian population. Anjankar et al. [32] also observed this distance as 15.4 mm and 15.1 mm respectively in central Indian population. According to Saralaya and Nayak [31] the distance of the greater palatine foramen from the sagittal plane was 14.7 ± 0.15 mm on right side and 14.7 ± 0.14 mm on left side in skulls obtained from the west coastal area

of Southern India. Vidulasri and Thenmozi [33] recorded 13.5 ± 1.5 mm on the right and 13.16 ± 1.17 mm in south Indian skulls. Ajmani ML [19] reported a distance of 15.4 ± 0.21 mm on both sides in Nigerian skulls, and 14.7 ± 0.96 mm on the right side and 14.6 ± 1.08 mm on the left side in Indian skulls.

The mean distance measured between the greater palatine foramen and the incisive fossa in the present study was 36.91 ± 2.39 mm on the right side and 36.97 ± 2.66 mm on the left side. Saralaya and Nayak [31] observed the same distance as 37.2 ± 0.29 mm and 37.4 ± 0.30 mm respectively on right and left side in south Indian population. Kumar A et al. [22] also observed this distance as 36.6 ± 2.20 mm and 35.7 ± 3.94 mm respectively in Punjab, India. According to Sathiya S et al. [34] the mean distance of greater palatine foramen from incisive fossa was 34.92 ± 2.22 mm on the right side and 34.83 ± 2.19 mm on the left side. Vidulasri and Thenmozi [33] studied same distance and noted the values as 37.9 ± 2.9 mm and 37.3 ± 2.5 on right and left side respectively. Slight variation in location of the greater palatine foramen may be due to sutural growth occurring between the maxilla and palatine bone. Additionally, with the eruption of the posterior teeth, the anteroposterior dimensions of the palate increases. [35] The present study was conducted in the skulls of North Indian origin, thus the difference can be attributed to racial and ethnic factors. In different studies, the mean distance value between greater palatine foramen and posterior border of hard palate also differ greatly. Our study found that the distance from the greater palatine foramen to the posterior border of hard palate was 4.75 ± 0.95 mm on the right and 4.43 ± 1.07 mm on the left. According to Anjankar et al. [32] the mean distance measured from the foramen to posterior palatal border was 3.5 mm and 3.3 mm on right and left side respectively, whereas Saralaya and Nayak [31] found the same distance was fairly constant on both sides, at a mean of 4.2 mm. Sathiya S et al.

[34] in their result reported that the mean distance from greater palatine foramen to incisive fossa was 3.57 mm on both sides of the skull. Vidulasri and Thenmozhi [33] noted the same distance as 3.8 mm and 4.3 mm respectively on right and left side in south Indian population.

In the study, shape of greater palatine foramen was observed to be oval in the majority of the skulls with 83.33% on right side and 78.21% on left side, while round shape was observed in 16.67% skulls on right side and 21.79% on left side. Sathiya S et al. [34] conducted a study in Tamil Nadu, India and reported that the shape of greater palatine foramen was oval in 89.5% and round in 10.5% of the skulls. As reported by Sushobhana et al. [36] the shape of greater palatine foramen was oval in 74% cases, round in 23% cases and irregular in 3% of the skulls. Nimigean et al. [23] reported the oval shape of greater palatine foramen in 84% and circular shape in 16% of skulls.

The position of maxillary molar is one of the most commonly used criteria for determining the location of greater palatine foramen. However, the location of the foramen is described differently by various authors. According to Snell [37] the foramen was situated at a posterolateral angle of the hard palate. Bannister [38] had described it near the lateral margin of hard palate behind the palatomaxillary suture, whereas Sicher & Dubrul [39] had reported it close to the posterior margin of the hard palate. Saralaya and Nayak [31] in their study had cited it commonly opposite the third molar (74.6%). Next common site was between second and third molars (24.2%). In 0.4% it was opposite second molar, and in 0.8% it was distal to third molar. According to Kumar A et al. [22] the foramen was located opposite the third molar in 85%, behind third molar in 1%, opposite second molar in 5%, and between second and third molars in 9%. Tiwari S et al. [40] reported it to be 70.83% opposite third molar, 27.5% opposite the junction of second and third molar and 1.67% opposite second molar. In

a cadaveric study it was observed that the most frequent position of greater palatine foramen was between the second and third molars [41] and similar results were observed in Chinese skull studies. [15] In the present study, the most common position of greater palatine foramen was found to be opposite to the third molar with an incidence of 82.05% on right side and 71.79% on left side. The second most common position was between second and third molar in 15.38% skull on right side and 24.36% on left side. In 2.56% it was distal to the third molar on right side and 3.85% on left side. No greater palatine foramen was observed opposite to the second molar on either side.

The direction of the greater palatine canal and its variations are important for the purposes of anaesthetizing branches of the maxillary division of the trigeminal nerve, to control posterior nasal hemorrhage and relief of sphenopalatine neuralgia. [3,42-44] Different researchers have investigated the direction of the greater palatine foramen opening on the palate and the results are widely varied. Saralaya and Nayak [31] described that in 46.2% cases the foramen opened anteromedially, in 41.35 cases anteriorly and in 12.5% it opened anterolaterally. According to Kumar A et al. [22] the direction of foramen was anterolateral in 73%, anteromedially in 19%, anteriorly in 1% and vertically in 7% of skulls. In a study carried out on 86 adult skulls from central India, [32] the direction of opening of greater palatine foramen into oral cavity was found to be anterolateral in 74.42% cases, anteriorly in 15.12% cases, anteromedially in 6.98% cases and vertically in 3.48% cases. Tiwari S et al. [40] had reported the direction of the foramen as anteromedial in 54.17% cases, and anteriorly in 45.83% of skulls. According to our results, the opening of the foramen was directed anteromedial in 66.03%, anterolateral in 25.64% and anteriorly in 8.33%.

The number of lesser palatine foramen is inconstant. As reported by Saralaya and Nayak, [31] this varies from

zero to four. They observed an average of 1.9 lesser palatine foramen on the left side and 1.8 on the right side. In Kenyan skulls, Hassanali and Mwaniki [18] have found as many as five lesser palatine foramina on the left side in 0.84% cases. They stated that placing the needle behind the greater palatine foramen could lead to blockage of lesser palatine nerve, resulting in soft palate anaesthesia and gagging sensation. Kumar A et al. [22] studied 100 skulls and reported the average no of lesser palatine foramen was 1.2 and 1.3 on the right and left sides respectively. In the present study, the average no of lesser palatine foramen observed was 1.56 ± 0.67 on the right side and 1.29 ± 0.48 on the left side of the skull. The maximum number of lesser palatine foramen observed was three and was absent in one skull on the left side. In cases where no lesser palatine foramina were present it is proposed that lesser palatine nerve and vessels might also be emerging from greater palatine foramen. [45]

The greater palatine nerve and the pterygopalatine ganglion can be accessed through the greater palatine foramen and the canal. Therefore, it is of immense importance to have a detailed knowledge of the anatomy of the greater palatine foramen. Since diverse results were found in studies from different region of the India, this may indicate that, the positions of the greater palatine foramen differ among ethnic groups. Variations in observations may be attributed to different degrees of sutural growth in palatomaxillary suture and appositional growth in different races at posterior border of the maxilla. Also, there are changes in position of the greater palatine foramen with age because with the eruption of molar teeth, it moves posteriorly. [35] These variation should always be considered during surgical procedures. The present study in north Indian population shows that greater palatine foramen was mostly oval shape and aligned with the maxillary third molar. This data will help compare skulls with those from other regions and ethnic groups, and

will also help anesthetics to precisely locate the position of greater palatine foramen.

Conflicts of Interests: None

REFERENCES

1. Willams PL, Warwick R, Dyson M, Bannister H. Gray's Anatomy, 37th ed. London, 1989; 354.
2. Romanes GJ. Cunningham's Textbook of Anatomy. 12th ed. New York: Oxford University press, 1981; 116.
3. Douglas R, Wormald PJ. Pterygopalatine fossa infiltration through the greater palatine foramen: where to bend the needle. Laryngoscope, 2006; 116(7):1255-57.
4. Teixeira CS, Souza VR, Marques CP, Silva Junior W and Pereira KF. Topography of the greater palatine foramen in macerated skulls J. Morphol Sci. 2010; 27(2): 88-92.
5. Howard-Swirzinski K, Edwards PC, Saini TS, Norton NS. Length and geometric patterns of the greater palatine canal observed in cone beam computed tomography. Int J Dent. 2010; 2010.pii: 292753.
6. Malamed SF. Handbook of Local Anesthesia. 5th ed. St. Louis: Elsevier Mosby, 2004.
7. Methathrathip D, Apinhasmit W, Chompoonong S, et al. Anatomy of greater palatine foramen and canal and pterygopalatine fossa in Thais: considerations for maxillary nerve block. SurgRadiolAnat. 2005; 27:511-6.
8. Wong JD, Sved AM. Maxillary nerve block anaesthesia via the greater palatine canal: a modified technique and case reports. Aust Dent J. 1991; 36:15-21.
9. Benninger B, Andrews K, Carter W. Clinical measurements of hard palate and implications for subepithelial connective tissue grafts with suggestions for palatal nomenclature. J Oral Maxillofac Surg. 2012; 70 (1): 149-53.
10. Jonnavithula N, Durga P, Madduri V, Ramchandran G, Nuvvula R, Srikanth R, et al. Efficacy of palatal block for analgesia following palatoplasty in children with cleft palate. PediatrAnaesth. 2010; 20(8):727-33.
11. Gardner E, Gray DJ, O'Rahilly R. Anatomy. 4th ed. Philadelphia: WB Saunders, 1975: 997.

12. Selden HM. Practical anesthesia for dental and oral surgery, 1948, 3rd edn. Lea Fabiger, Philadelphia, 206.
13. Shane SME. Principles of sedation, local and general anesthesia in dentistry, 1975 1st ed. Charles C Thomas, Illinois, pp 173.
14. Moore KL. Clinically Oriented Anatomy, 1st ed. Baltimore: Williams and Wilkins, 1980: 1004.
15. Wang TM, Kuo KJ, Shih C, Ho LL, Liu JC. Assessment of the relative locations of the greater palatine foramen in adult Chinese skulls. *Acta Anat Basel*, 1988; 132:182-86.
16. Canter SR, Slavkin HC, Canter MR. Anatomical study of pterygopalatine fossa and canal: considerations applicable to the anesthetization of the second division of the fifth cranial nerve. *J Oral SurgAnesthHosp Dent Serv*. 1964; 22:318-23.
17. Chentanez V, Kaweewongprasert S, Thunvarachorn P, Punrut N. Position of greater palatine foramina, length and direction of greater palatine canals: anatomic study of 120 adult human skulls. *Chula Med J*. 1985; 29:1187-97.
18. Hassanali J, Mwaniki D. Palatal analysis and osteology of the hard palate of the Kenyan African skulls. *Anat Rec*. 1984; 209(2):273-80.
19. Ajmani ML. Anatomical variation in position of the greater palatine foramen in the adult human skull. *J Anat*. 1994; 184(Pt 3):635-7.
20. Williams WT, Ghorayeb BY. Incisive canal and pterygopalatine fossa injection for hemostasis in Septorhinoplasty. *Laryngoscope*, 1990; 100: 1245e-1247e.
21. Kamath MR, Mehandale SG, Raveendra US. Comparative study of greater palatine nerve block and intravenous pethidine for postoperative analgesia in children undergoing palatoplasty. *Indian J Anaest*. 2009; 53 (6):654-61.
22. Kumar A, Sharma A, Singh P. Assessment of the relative location of greater palatine foramen in adult Indian skulls: Consideration for maxillary nerve block. *Eur J Anat*. 2011; 15 (3): 150-54.
23. Nimigaen V, Nimigean Vr, Buřincu L, Salavastru DPL. Anatomical and clinical considerations regarding the greater palatine foramen. *Rom J MorpholEmbryol*. 2013; 54:779-83.
24. Sharma NA, Rajendra SG. Greater palatine foramen - key to successful hemimaxillary anaesthesia: a morphometric study and report of a rare aberration. *Singapore Med J*. 2013; 54(3):152-9.
25. Ikuta CRS, Cardoso CL, Ferreira-Júnior O, Lauris JRP, Souza PHC, Rubira-Bullen IRF. Position of the greater palatine foramen: an anatomical study through cone beam computed tomography images. *SurgRadiol Anat*. 2013;35(9):837-42.
26. Piagkou M, Xanthos T, Anagnostopolou S, Demesticha EK, Piagkos G, Protogerou V, Lappas D, Skandalakis P, Johnson EO. Anatomical variation and morphology in the position of the palatine foramina in adult human skulls from Greece. *J Craniomaxillofac Surg*. 2012;40(7):e206-10.
27. Tomaszewska IM, Tomaszewski KA, Kmiatek EK, Pena IZ, Urbanik A, Nowakowski M, Walocha JA. Anatomical landmarks for the localization of the greater palatine foramen—a study of 1200 head CTs, 150 dry skulls, systematic review of literature and meta-analysis. *J Anat*. 2014; 225(4):419-35.
28. D'Souza AS, Mamatha H, Nayak J. Morphometric analysis of hard palate in south Indian skulls. *Biomed Res*. 2012; 23:173-5.
29. Dave MR, Gupta S, Vyas KK, Joshi HG. A study of palatal indices and bony prominences and grooves in the hard palate of adult human skulls. *NJIRM*. 2013;4(1):7-11.
30. Jotania B, Patel SV, Patel SM, Patel P, Patel S, Patel K. Morphometric analysis of hard palate. *Int J Res Med*, 2013, 2(2): 72-75.
31. Saralaya V, Nayak SR. The relative position of the greater palatine foramen in dry Indian skulls. *Singapore Med J*. 2007;48(12):1143-6.
32. Anjankar VP, Gupta SD, Nair S, Thaduri S, Trivedi GN, Budhiraja V. Analysis of position of greater palatine foramen in central Indian adult skulls: a consideration for maxillary nerve block. *Indian J PharmBiol Res*. 2014; 2(1):51-54.
33. Vidulasri N and Thenmozhi MS. Morphometric analysis of greater palatine foramen in dry skulls. *IJPSR*, 2015; Vol. 6(11): 4779-82.
34. Sathiya S, Udhaya K, Priya SH. Morphological study of greater palatine foramen in adult human skull bones. *NJBMS*, 2017; | Vol 7 (3), 139-44.
35. Slavkin HC, Canter MR, Canter SR. An anatomic study of the pterygomaxillary

- region in the craniums of infants & children. *Oral Surg Oral Med Oral Pathol.* 1966; 21:225-35.
36. Sushobhana, Mishra SR, Singh S, Passey J, Singh R, Sinha P. Anatomical Study and Clinical Considerations of Greater Palatine Foramen in Adult Human Skulls of North Indian Population. *IJARS.* 2015 Oct; Vol 4(4) 41-46.
 37. Snell R S. *Clinical Anatomy for Medical Students.* 2nd ed. Boston, Little, Brown and Company, 1981.p.672.
 38. Bannister D. *Gray's Anatomy.* 38th ed. London, Churchill Livingstone, 1989.p.354.
 39. Sicher H & Dubrul BL. *Oral Anatomy.* 7th ed. St. Louis, C. V. Mosby Co., 1980.pp.84-5.
 40. Tiwari S, Agarwal S, Vasudeva N. Topography of the greater palatine foramen in north Indian population: Key to successful maxillary nerve block. *GJRA Vol.* 6, (12), Dec. 2017; 442-45.
 41. Fu JH, Hasso DG, Yeh CY, Leong DJM, Chan HL, Wang HL. The accuracy of identifying the greater palatine neurovascular bundle: a cadaver study. *J Periodontol.* 2011; 82 (7):1000–06.
 42. Das S, Kim D, Cannon TY, et al. High-resolution computed tomography analysis of the greater palatine canal. *Am J Rhinol.* 2006; 20:603–08.
 43. Erdogan N, Unur E, Baykara M. CT anatomy of pterygopalatine fossa and its communications: A pictorial review. *Comput Med Imaging Graph.* 2003;27:481–87.
 44. Stankiewicz JA. Greater palatine foramen injection made easy. *Laryngoscope,* 1988; 98: 580–81.
 45. Jaffar AA and Hamadah HJ. An analysis of the position of the greater palatine foramen. *J Basic Med Sc.* 2003; 3 (1):24-32.

How to cite this article: Singh D, Patnaik P, Gupta N. A study of the anatomical variation and clinical considerations of greater palatine foramen in adult human skulls of north Indian population. *Int J Health Sci Res.* 2019; 9(5):13-21.
