

# Morphology and Morphometric Analysis of the Foramen Magnum in Dried Adult Skulls in North Indian Region

Dalvinder Singh<sup>1</sup>, Poonam Patnaik<sup>2</sup>, Neha Gupta<sup>3</sup>

<sup>1</sup>Professor, <sup>2</sup>Associate Professor,

Department of Anatomy, Faculty of Dentistry, Jamia Millia Islamia, Delhi - 110025

<sup>3</sup>Professor, Sudha Rustagi College of Dental Science & Research Institute, Faridabad, Haryana -121002

Corresponding Author: Dalvinder Singh

## ABSTRACT

**Introduction:** Foramen magnum is a clinically important landmark present at the skull base due to its close association with brain stem and spinal cord. The foramen magnum dimensions are necessary because the structures passing through it may be compressed in cases of foramen magnum meningioma, foramen magnum achondroplasia and foramen magnum herniation, additionally as also required to determine some malformations such as Arnold Chiari syndrome, which shows expansion of transverse diameter. Thus, the present study was carried out to provide the morphology and morphometry of foramen magnum of dry human skulls in North Indian population.

**Materials and methods:** Eighty four dry skulls of adult human being were studied. Anteroposterior and transverse diameters of foramen magnum were calculated using vernier caliper and shapes were visually assessed. Additionally, the area and index of foramen magnum were also calculated using formulae.

**Results:** The average anteroposterior diameter and transverse diameter of foramen magnum were  $33.57 \pm 2.82$  mm and  $27.49 \pm 2.61$  mm respectively. The average area and index of the foramen magnum were calculated as  $728.12 \pm 112.98$  mm<sup>2</sup> and  $82.09 \pm 7.04$  respectively. The incidence of the morphological types of foramen magnum were observed as a oval shape in 29.76% of cases, round in 26.19%, tetragonal in 16.67%, egg shape in 10.71%, irregular in 5.95%, hexagonal in 5.95% and pentagonal in 4.76% of the cases.

**Conclusion:** The data obtained may serve as an aid to neurosurgeons in assessing the morphology of cervicovertebral junction in lateral transcondylar surgical approaches for reaching lesions in the middle and posterior part of cranial base. The findings are also enlightening for the anaesthetist, orthopaedic surgeon, radiologists, forensic experts, anatomists and anthropologists.

**Keywords:** Skull, foramen magnum, morphology, morphometry, shape.

## INTRODUCTION

The skull forms the skeleton of the head, composed of bones united to one another at joints called sutures. There are several openings in the base of the skull known as foramina. Foramen magnum is the largest opening in the occipital bone of the skull, lies in an anteromedian position and

through which the spinal cord and its membranes exits the cranial cavity. Additionally the structures passing through the foramen are vertebral artery, anterior and posterior spinal arteries, spinal accessory nerve, tectorial membrane and alar ligaments connecting the dens of axis with the occipital bone and

occasionally the tonsil of the cerebellum. [1] Foramen magnum is a fundamental component of studies on skull in particular interest for anthropology, anatomy, forensic medicine, and other medical fields. [2-3]

The knowledge of foramen magnum morphometry is also needed to determine some developmental and acquired craniocervical junction disorders. Achondroplasia is a genetic disorder that results in dwarfism and abnormal endochondral bone formation at the cranial base, leads to a narrow cervical spinal canal and a stenotic foramen magnum. Clinical appearances of constant brainstem compression by stenosis of the foramen magnum and related structures are respiratory complications, lower cranial nerve dysfunctions, upper and lower extremity paresis, hypotonia or hypertonia and general motor development delay. [4-5] In Arnold-Chiari deformity there is enlargement of the transverse diameter of the foramen magnum. [3,6-7] Other Diseases related with malformations and anomalies of craniocervical junction are abnormal clivoaxial angle, hypoplasia of the posterior fossa, platybasia and stenosis of the foramen magnum. These anomalies predisposed to herniation of the cerebellar tonsils into the foramen magnum that can block blood and CSF flow between the cranial cavity and spinal canal resulting in hydrocephalus. [8-14]

The transcondylar approach is a skull-base technique that enables neurosurgeons to access the brainstem and cervico medullary junction region with minimum retraction. Understanding the bony anatomy of this region is very important for this approach. [6]

A review of literature on foramen magnum revealed that morphological differences of foramen magnum are noticed in different population and this depends on genetic, environment and socio-economic factors. These variations have become significant due to newer imaging techniques like computed tomography and magnetic resonance imaging in the subject of diagnostic medicine. Therefore, present

study has been done to increase data about foramen magnum in Indian population especially in north Indian skulls.

## MATERIALS AND METHODS

The study was conducted on 84 dry human adult skulls of unknown gender, obtained from the Department of Anatomy, Faculty of Dentistry, Jamia Millia Islamia University, Delhi, and Sudha Rustagi College of Dental Science & Research Institute, Faridabad (Haryana), India. All the skulls used for the study were dry, complete & showed normal anatomical features. Skulls with broken and deformed foramen magnum were excluded from the present study.

The various parameters measured using vernier caliper are as follows (Figure 1.): -

1. Anteroposterior diameter of Foramen magnum (APDfm): Anteroposterior diameter of the foramen magnum was measured from basion (median point on the anterior margin of the foramen magnum) to opisthion (median point on the posterior margin of the foramen magnum) in sagittal plane.

2. Transverse diameter of Foramen magnum (TDfm): Transverse diameter of FM was measured perpendicular to anteroposterior diameter in the coronal plane at a point where it was maximum.




Figure 1. Photograph showing measurement of foramen magnum diameters.

APDfm- Anteroposterior diameter, TDfm- Transverse diameter

3. Area of foramen magnum (Afm): It is the surface area of foramen magnum calculated using formula derived by Radinsky. [15]

$$\text{Area of foramen magnum (Afm)} = \frac{1}{4} \pi wh$$

$\pi$  → Mathematical constant = 22/7

w → Transverse diameter of Foramen magnum (TDfm)

h → Anteroposterior diameter of Foramen magnum (APDfm)

4. Foramen magnum index (Ifm):

Calculated by: Foramen magnum width (TDfm) X 100 / Foramen magnum length (APDfm). [16]

The above parameters were recorded as an average of two observations which were measured independently by two different people. The mean and standard deviation for each parameter was calculated and expressed as mean ± standard deviation. In addition the shapes of the foramen magnum were also noted and classified as oval, round, tetragonal, hexagonal, pentagonal, egg shaped and irregular (Figure 2).

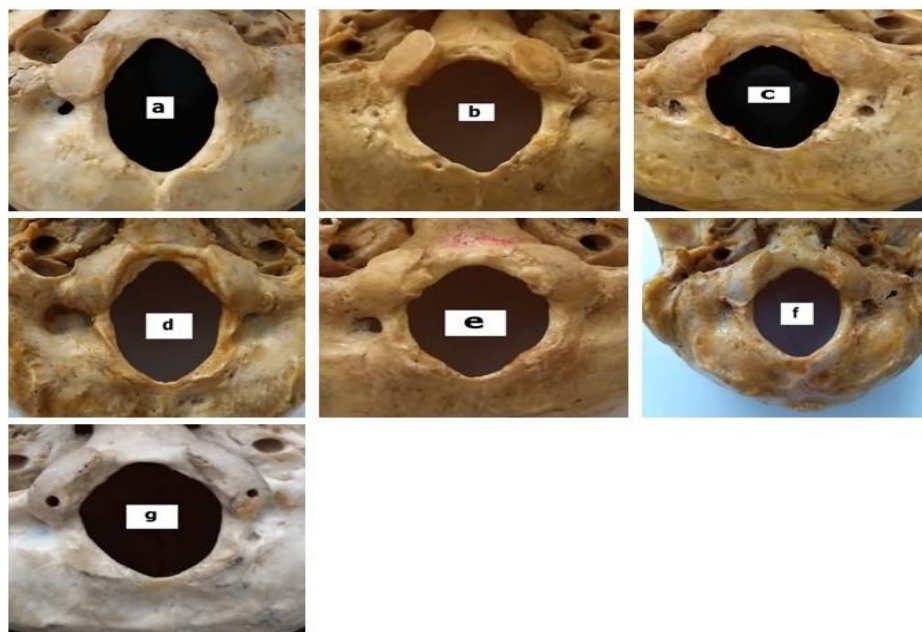


Figure 2. Photograph showing morphological variants of the shape of Foramen magnum: (a) oval, (b) hexagonal, (c) irregular, (d) egg shaped, (e) tetragonal, (f) round, (g) pentagonal

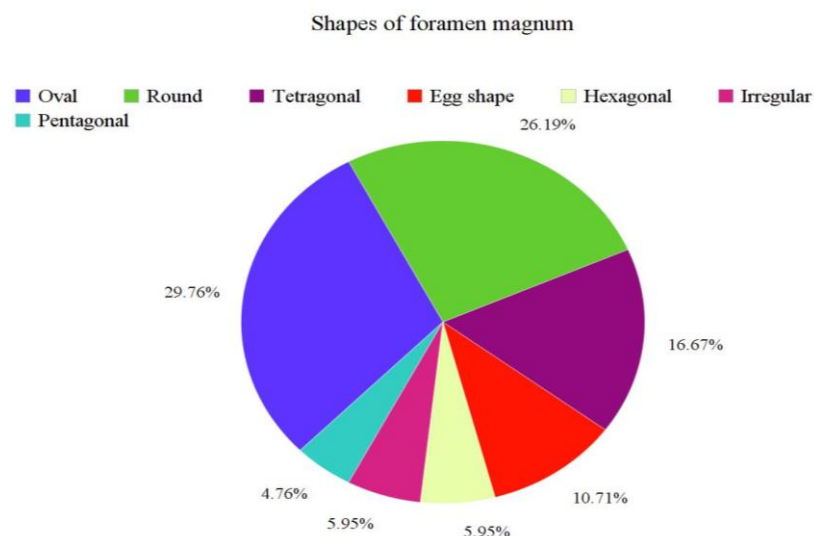


Figure 3. Pie diagram showing various shape of foramen magnum in present study.

## RESULT

The various parameters related to the foramen magnum were measured and displayed in Table 1 & 2. The anteroposterior diameter of the foramen magnum was in a range of 29.20-39.10 mm with a mean of  $33.57 \pm 2.82$  mm, and the transverse diameter of the foramen magnum was in a range of 21.11 - 31.80 mm with a mean of  $27.49 \pm 2.61$  mm.

The mean surface area of the foramen magnum was  $728.12 \pm 112.98$  mm<sup>2</sup>,

range being from 501.74 mm<sup>2</sup> to 923.38 mm<sup>2</sup>. The mean foramen magnum index was found to be  $82.09 \pm 7.04$ .

The foramen magnum was observed to have oval shape in 29.76%, round in 26.19%, tetragonal in 16.67%, egg shape in 10.71%, hexagonal in 5.95%, irregular in 5.95% and pentagonal in 4.76% of the cases (Figure 3). Among the various shapes observed the oval shaped foramen magnum was found to be the highest in occurrence.

**Table 1. Morphometric dimensions of foramen magnum in present study.**

Parameter	Mean+S.D.	Minimum	Maximum
Anteroposterior diameter (APDfm) (mm)	$33.57 \pm 2.82$	29.20	39.10
Transverse diameter (TDfm) (mm)	$27.49 \pm 2.61$	21.11	31.80
Foramen magnum area (Afm) (mm <sup>2</sup> )	$728.12 \pm 112.98$	501.74	923.38
Foramen magnum index (Ifm)	$82.09 \pm 7.04$	69.79	93.53

**Table 2. Comparison of foramen magnum shapes with previous studies.**

Shape of foramen magnum	Present study	Mishra AK et al (2018)	Sampada PK et al (2017)	Singh KC et al (2017)	Rajkumar et al (2017)	Rohinidevi M et al (2016)	Sharma S et al (2015)	Mursheed KA et al (2003)
Oval	29.76	37.8	58	34	66	18	16	8.1
Round	26.19	30.9	9	20	24.83	26	22	21.8
Tetragonal	16.67	7.04	8	16	3.35	11	12	12.7
Egg	10.71	-	11	-	-	14	16	6.3
Hexagonal	5.95	11.2	3	18	4.02	6	8	17.2
Irregular	5.95	9.85	10	4	-	22	18	19.18
pentagonal	4.76	7.04	-	4	2.68	6	8	13.6

## DISCUSSION

The foramen magnum is a transition zone between skull and vertebral column. It plays a significant role as a landmark because of its close relationship to key structures such as brain, spinal cord, accessory spinal nerves and vertebral arteries. It is a morphologically variable osteological feature in the skull which has undergone evolutionary modification. [17] During the fetal life, development of skull base begins as a cartilaginous model with multiple centers of ossification and the foramen magnum alone is one such center. At birth the occipital bone consist of a basilar part, two lateral parts and a squamous part all are joined by cartilage and forming a ring around the foramen magnum. [18] Anatomical knowledge of the foramen magnum is important for understanding the pathophysiology of

various disorders of the craniovertebral junction as well as for planning surgical procedures. [3,19-21] Considering these factors, The present study was undertaken to provide information on the morphometric analysis of the foramen magnum in skulls of the north Indian population.

In the present study, mean anteroposterior diameter of foramen magnum was  $33.57 \pm 2.82$  mm and the mean transverse diameter was  $27.49 \pm 2.61$  mm. Muthukumar N [6] et al. observed that the average anteroposterior length of the foramen magnum was 33.3 mm and the transverse diameter was 27.9 mm. Sampada P K et al. [22] reported an average anteroposterior diameter of foramen magnum was  $34.84 \pm 2.32$  mm and an average transverse diameter of  $29.39 \pm 1.73$  mm. In a study [23] done on 71 skulls of Uttar Pradesh the mean anteroposterior

diameter of foramen magnum was  $34.09 \pm 2.23$  mm and transverse diameter was  $28.22 \pm 2.19$  mm. However Philipp Gruber [24] in his study on skulls from western Europe found the average anteroposterior diameter of foramen magnum was 36.6 mm within range from 30.1 mm to 42.6 mm and the average transverse diameter was 31.1 mm within range from 25 mm to 38.9 mm.

Waneboard Chicoine [19] observed that the mean diameters were 36 mm for the length and 31 mm for the width of the foramen magnum. Solan S [25] studied sixty human skulls and observed that the mean anteroposterior diameter of foramen magnum was  $36 \pm 2.9$  mm and mean transverse diameter was  $32.2 \pm 2.9$  mm (Figure 4).

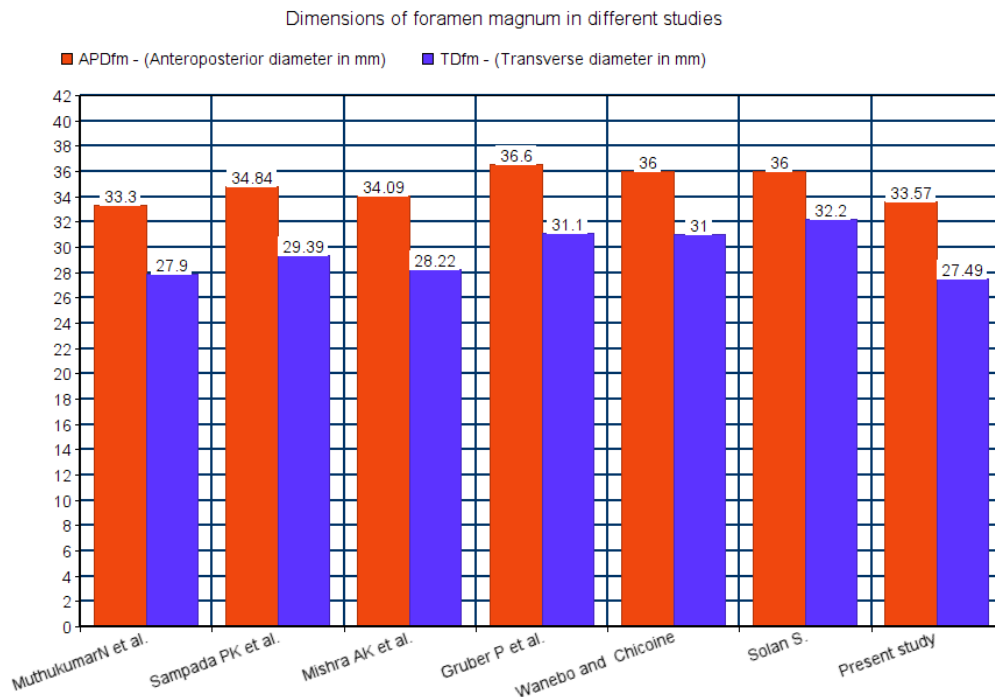


Figure 4. Bar diagram showing the comparison foramen magnum dimensions in different studies.

In the present study the area of the foramen magnum observed was  $728.12 \pm 112.98$  mm<sup>2</sup>. In a study done by Praveen T and Singh P [26] on 92 dried skull reported the mean area of foramen magnum was  $792.61 \pm 91.01$  mm<sup>2</sup>. Shika et al. [27] studied 50 dried skulls and observed that the mean area of the foramen magnum was 970.57 mm<sup>2</sup>. Rajkumar et al. [28] in 2017 did measurements on 298 dry skull of unknown sex, and reported the area of foramen magnum was  $754.32 \pm 105.6$  mm<sup>2</sup>. A study which was done on south Indian population [22] reported the mean area of foramen magnum was  $803.8 \pm 83.42$  mm<sup>2</sup>. Rohinidevi et al. [29] studied 35 skulls and observed that the area of foramen magnum was 820.53 mm<sup>2</sup>. The variations obtained in the abovementioned studies may be due to the

ethnic group involved and size of study sample.

In the present study foramen magnum index was found to be  $82.09 \pm 7.04$ , which was in accordance with other studies. In a study conducted by Singh KC et al. [30] on 50 dried skulls of unknown sex, they found that the mean foramen magnum index was  $84.56 \pm 6.32$ . A study done by Rohinidevi et al. [29] on 35 Indian dry skulls and found that the average foramen magnum index was 82.54. There is another study conducted on 298 skulls by Rajkumar et al. [28] and reported that the mean foramen magnum index was  $83.14 \pm 6.33$  mm.

The shape of the foramen magnum is morphologically variable. Variations in foramen magnum shape should be taken into consideration during radiological

diagnostic procedures and surgical approaches to the region. This is also important for deciding that how much bone must be removed. [21] In early fetal development, foramen magnum is one of the centres of ossification and because of evolutionary changes its shapes are variable. [6,17-18] The irregular shape of the FM may be due to developmental anomalies related to bones and soft tissues at the craniovertebral junction. [3,20]

In our study, oval shape of foramen magnum was commonly seen (29.76%). This was followed by round (26.19%), tetragonal (16.67%), egg shaped (10.71%), hexagonal (5.95%), irregular (5.95%) and pentagonal (4.76%). The findings of previous studies are presented in Table 2. According to Sampada PK et al., [22] Singh KC et al., [30] Rajkumar et al. [28] and Mishra AK et al. [23] the oval shape is the main type, while it is the round shape according to Rohinidevi M et al., [29] Mursheed KA et al. [31] and Sharma S et al. [32] The variations in the shape of the foramen magnum might have been attributed by the factors such as diverse ethnical group, sample size, sexual dimorphism and types of population.

## CONCLUSION

The present study elucidates the morphometric data and the variations in the morphology of the foramen magnum. The average anteroposterior diameter and transverse diameter of the foramen magnum were  $33.57 \pm 2.82$  mm and  $27.49 \pm 2.61$  mm respectively. The mean surface area of  $728.12 \pm 112.98$  mm<sup>2</sup> and index of  $82.09 \pm 7.04$  was observed in foramen magnum, and oval shape found in 29.76% of skulls in north Indian region. Knowledge of the morphometry of foramen magnum is important for surgeon during the surgeries of foramen magnum meningioma or posterior cranial fossa lesions and also in determining Arnold Chiari Syndrome. This is significant as the consequences outcomes of various surgical procedures depend upon the size and variations of these foramina. These findings are important not only for

neurosurgeons but also to the anaesthetist, orthopedist, radiologists, forensic experts, anatomists and anthropologists.

**Conflicts of Interests:** None

## REFERENCES

1. Standring S, Borley NR, Collins P, Crossman AR, Gatzoulis MA, et al. Gray's Anatomy 40<sup>th</sup> Ed, London: Elsevier Ltd., 2008. 415,420,424,711.
2. Ferreira FV, Rosenberg B and da Luz HP. The Foramen Magnum index in Brazilians. Rev Fac Odontol Sao Paulo. 1967; 5(4):297-302.
3. Furtado SV, Thakre DJ, Venkatesh PK, Reddy K and Hegde AS. Morphometric analysis of foramen magnum dimensions and intracranial volume in pediatric Chiari I malformation. Acta Neurochir (Wien). 2010; 152: 221-227.
4. Hecht TJ, Horton WA, Reid CS, et al. Growth of the foramen magnum in achondroplasia. American J of Medical Genetics, 1989; 32:528-35.
5. Tubbs RS, Griessenauer C, Loukas M, Shoja MM, Cohen GD, et al. Morphometric analysis of the foramen magnum: an anatomic study. Neurosurgery, 2010; 66:385-8.
6. Muthukumar N, Swaminathan R, Venkatesh G, Bhanumathy SP. A morphometric analysis of the foramen magnum region as it relates to the transcondylar approach. Acta Neurochir (Wien.) 2005; 147:889-895.
7. Sgouros S, Goldin HJ, Hockely AD, Wake MJ, et al. Intracranial volume change in childhood. J Neurosurg. 1999; 91:610-616.
8. Reich JB, Sierra J, Camp W, et al. Magnetic resonance imaging measurements and clinical changes accompanying transtentorial and foramen magnum brain herniation. Annals of Neurology. 1993; 33:159-70.
9. Stovner LJ, Bergan U, Nilsen G, Sjaastad O. Posterior cranial fossa dimensions in the Chiari I malformation: relation to pathogenesis and clinical presentation. Neuroradiology, 1993; 35(2):113-118. doi: 10.1007/bf00593966.
10. Henderson FC, Wilson WA, Mott S et al. Deformative stress associated with an abnormal clivo-axial angle: a finite element analysis. Surgical Neurology International, 2010; 1(1, article 30) doi: 10.4103/2152-7806.66461.
11. Milhorat TH, Nishikawa M, Kula RW, Dlugacz YD. Mechanisms of cerebellar tonsil herniation in patients with Chiari malformations as guide to clinical management. Acta Neurochirurgica. 2010;

- 152(7):1117–1127. doi: 10.1007/s00701-010-0636-3.
12. Botelho RV, Ferreira EDZ. Angular craniometry in craniocervical junction malformation. *Neurosurgical Review*, 2013; 36(4):603–610. doi: 10.1007/s10143-013-0471-0.
  13. Chamberlain WE. Basilar impression (platybasia): a bizarre developmental anomaly of the occipital bone and upper cervical spine with striking and misleading neurologic manifestations. *The Yale Journal of Biology and Medicine*, 1939;11(5):487–496.
  14. Cinalli G, Sainte-Rose C, Kollar EM, et al. Hydrocephalus and craniosynostosis. *Journal of Neurosurgery*, 1998;88(2):209–214. doi: 10.3171/jns.1998.88.2.0209.
  15. Radinsky L. Relative brain size a new measure. *Science*, 1967;155:836-838.
  16. Martin R. Saller K. Lehrbuch de Anthropologie. Band 1. Stuttgart: Gustav Fisher Verlag. 1957; Pp 455-509.
  17. Nevell L and Wood B. Cranial base evolution within the hominin clade. *J Anat*. 2008; 212: 455-468.
  18. Scott J H. The cranial base. *Am J Phys Anthropol*. 1958; 16, 319-348.
  19. Wanebo JE, Chicoine MR. Quantitative analysis of the transcondylar approach to the foramen magnum. *Neurosurgery*, 2001;49(4):934–943.
  20. Chethan P, Prakash KG, Murlimanju BV, et al. Morphological analysis and morphometry of the foramen magnum:an anatomical investigation. *Turk Neurosurg*. 2012; 22(4): 416–419.
  21. Kizilkanat ED, Boyan N, Soames R, et al. Morphometry of the hypoglossal canal, occipital condyle, and foramen magnum. *Neurosurg Q*. 2006;16(3):121–125.
  22. Sampada PK, Poornima B, Mallikarjun M, Santosh B Sakri. Morphometric and morphological study of foramen magnum in dried human skull bones. *Int J Anat Res*. 2017; Vol 5(2.1) ISSN 2321-4287:3682-86.
  23. Mishra AK, Pandey SB, Yadav CK, Haque M, Chandra N. Morphometric study of foramen magnum of skulls in population of Uttar Pradesh. *Int J Anat Res*. 2018, Vol 6(2.2) ISSN 2321-4287:5186-90.
  24. Gruber P, Henneberg M, Böni T and Rühli FJ. Variability of Human Foramen Magnum Size. *Anat Rec*. 2009; 292:1713–19.
  25. Solan S. Morphometric analysis of foramen magnum and occipital condyles in human skull among eastern population - A case study. *Ind J of App Res*. 2015;Vol 5 (9) ISSN - 2249-555X,187-189.
  26. Praveen T and Singh P. A north Indian skull based study of a morphological and morphometrical measurements of foramen magnum. *Ind J of App Res*. July-2018 ; Vol8 (7) 8618 ISSN, 68-70.
  27. Shika S, Sharma AK, Bhawani S M, Arshad M. Morphometric Evaluation of the Foramen Magnum and Variation in its Shape and Size: A Study on Human Dried Skull. *IntJAnat Res*. 2015;3(3):1399-03.
  28. Rajkumar, Kattimuthu P, Manik P, Singh V. Morphometric analysis of the foramen magnum of dry human skulls in north Indian population. *Int J Anat Res*. 2017; Vol 5(1):3480-84.
  29. Rohinidevi M and Vimala V. Morphometric analysis of foramen magnum and variations in its shape in dried human adult skulls: . *Int J Anat Res*. 2016;4(3):2670 -73.
  30. Singh KC, Rai G, Rai R. Morphological Variations of the Foramen Magnum in Adult Human Dry Skull in Eastern UP (India) Population. *Int J Med Res. Prof*.2017; 3(2); 205-08.
  31. Murshed KA, Cicekeibasi AE, Tuncer I. Morphometric evaluation of the foramen magnum and variations in its shape. A study of computerized tomographic images of normal adults. *Tur J Med Sci*. 2003;33:301-306.
  32. Sharma S, Sharma AK , Modi BS , Arshad M. Morphometric evaluation of the foramen magnum and variation in its shape and size: A study on human dried skull. *Int J Anat Res*. 2015, Vol 3(3):1399-03. ISSN 2321- 4287.

How to cite this article: Singh D, Patnaik P, Gupta N. Morphology and morphometric analysis of the foramen magnum in dried adult skulls in North Indian region. *Int J Health Sci Res*. 2019; 9(4):36-42.

\*\*\*\*\*