

Case Report

Maxillary First and Second Molars with Two Palatal Root Canals: Two Case Reports

Dr Shweta Mittal¹, Dr Rajat Goel², Dr Vinay Kumar¹, Dr Archana Goel²

¹Associate Prof., Dept. Of Conservative Dentistry & Endodontics, PGIDS University of Health Sciences ROHTAK

²MDS Conservative Dentistry & Endodontics, PGIDS University of Health Sciences ROHTAK

Corresponding Author: Dr Shweta Mittal

ABSTRACT

Aim: To report anatomic variation in maxillary first and second molars.

Introduction: The aim of this article was to show the importance of the knowledge of the anatomy of root canals. Unusual root and root canal morphologies associated with molars have been recorded in several studies in the literature. However, scientific information focusing on variations of the palatal root is rare.

Case Description: In this article two cases are presented involving root canal treatment of maxillary first and second molar with unusual morphologic configurations of the palatal root canals. During root canal treatment operating microscope was used. Type II and type IV configuration as described by Vertucci was identified in maxillary first and second molar palatal root respectively.

Conclusion Anatomic variations can occur in any tooth, and palatal roots of maxillary first and second molars are no exception.

Clinical Significance: This report points to the importance of looking for additional roots and canals because knowledge of their existence would enable clinician to treat a case successfully that otherwise might end in failure.

Key Words: palatal root canal, operating microscope, maxillary molar

INTRODUCTION

Cleaning and obturation of entire root canal system is the ultimate goal of root canal therapy. ^[1] There are many reasons for endodontic failure like incomplete instrumentation, inadequate cleaning, insufficient canal obturation, and also left out untreated canals. ^[1]

Maxillary molars are known to have a second mesial canal located in the mesiobuccal root. Pe'cora et al ^[2] evaluated the anatomy of 370 maxillary molars by means of clearing and located a second canal in mesiobuccal root with frequencies of 25%, 42%, and 32% with maxillary first, second, and third molars respectively. Cleghorn ^[3] reviewed 34 studies and found

56.8% and 43.1% incidence of two and one canal respectively in the mesiobuccal root of maxillary molars out of 8399 teeth. In contrast to these findings, very few literatures are available about variations in the palatal roots and their canals. But still these anatomic variations should not be disregarded.

Baratto-Filho ^[4] in their study found two palatal canals in 2.05%, 0.65%, 4.55% cases on ex vivo, clinical and computed tomography respectively. Stone and Stroner ^[5] reported multiple systems associated with palatal root and palatal root canals. Benenati ^[6] reported a maxillary second molar with two palatal roots and a groove located in this side of the tooth, according to the

author, this groove was the result of the formation of two palatal roots. Baratto-Filho [7] et al found two maxillary second molars with four canals and two different palatal roots. Christie [8] et al. analysed endodontic treatment in 16 maxillary molars during and on six extracted teeth for palatal roots and these 22 molars were classified according to the root separation level and their divergences into three types i.e. type I to type III.

In their database study, Iqbal and Fillmore [9] emphasized that the patient's age was an important factor for the detection of fewer canals in maxillary molars. This might be because of the calcification and morphologic changes that occur with age and makes discovery of root canals difficult in aged person. This could be one of the reasons of the big discrepancies in the number of canals in different studies and case reports.

Numerous articles reinforced the importance of knowing the anatomic variations in case reports showing maxillary molars with palatal canals. The least frequent anomaly appears to be that of the double palatal root. The present article describes two cases with different canal configurations of the palatal roots in maxillary first and second molar.

CASE REPORT 1

A 24-year-old female patient reported to the Department of Endodontics, with the chief complaint of intermittent pain in the upper right back teeth for the past 10 days. Her medical history was found to be non-contributory. Clinical examination revealed a symptomatic tooth #16 with caries on mesial wall (Fig1 A). The tooth exhibited tenderness to percussion. Intraoral periapical radiograph revealed a normal root canal anatomy and widening of periodontal ligament space of the involved tooth (Fig 1 B). Provisional diagnosis of apical periodontitis with symptomatic irreversible pulpitis was made. Non-surgical endodontic therapy was planned. The tooth was anesthetized. After isolation with rubber dam, the access cavity was prepared.

Clinical evaluation of the internal anatomy of the pulp chamber revealed 3 principal root canal orifices: mesiobuccal, distobuccal, and palatal. The pulp chamber was frequently flushed with 2.5% sodium hypochlorite to remove pulp tissue remnants. With DG-16 endodontic explorer, a small hemorrhagic point was noticed. The access cavity was further modified. Inspection of the pulp chamber revealed 4 distinct orifices, 2 buccally and 2 palatally (Fig1C). The additional canal patency was checked with #10 K-file. Working length radiograph confirmed the presence of two canals in the palatal root joining into one at apical one third (Fig1D). All the canals were instrumented by the crown down technique using protaper nickel-titanium rotary instruments with 2.5% sodium hypochlorite solution and EDTA. All the instrumented canals were medicated with $\text{Ca}(\text{OH})_2$ and the tooth was then temporized with IRM cement. After 1 week, the tooth was asymptomatic, master cone apical GP X ray was taken (Fig 1E). The canals were obturated with F2 protaper gutta-percha and sealed with IRM cement (Fig 1F). Postobturation radiograph revealed Vertucci type II root canal morphology in the palatal root. (Fig 1F). After one month patient was given full metal crown. At follow up of 18 month patient was asymptomatic. (Fig1G,H)

CASE REPORT 2

A 32-year-old female patient reported to the Department of Endodontics, with chief complaint of intermittent pain in the upper right back teeth for the past 3 months. Her past dental history revealed that she visited a general dental practitioner with the same complaint 3 months back and after due examination, root canal treatment was commenced, but the patient discontinued the treatment as she was not relieved of pain. Her medical history was found to be non-contributory. Clinical examination revealed a symptomatic tooth #17 with caries on buccal and distal walls with open access cavity and accumulation of food debris. The tooth exhibited tenderness to percussion. Intraoral periapical (IOPA)

radiograph revealed a prepared access cavity with root canal anatomy not completely clear (Fig 2A). After isolation with rubber dam, the access cavity was modified using a round bur. Initial evaluation of the internal anatomy of the pulp chamber revealed 3 principal root canal orifices: mesiobuccal, distobuccal, and palatal. The pulp chamber was frequently flushed with 2.5% sodium hypochlorite to remove pulp tissue remnants. Under inspection with the microscope, an inconspicuous dentinal structure in the palatal aspect of the pulp chamber floor was removed with ultrasonic instruments and a second palatal canal orifice was detected. It was located approximately 3 mm distally from the orifice of the main palatal canal.

The access cavity was further modified from triangular to trapezoidal to get better access to the additional canal. Inspection of the pulp chamber revealed 4 distinct orifices, 2 buccally and 2 palatally (Fig 2B). Working length X ray was taken (Fig 2C). Canals were instrumented with 20 K-files to size 20 and Gates-Glidden drills 4-2 were used to flare the coronal thirds of the root canals. Apical preparation was performed with hand files. With operating microscope at 8 x magnification we can clearly see all the 4 orifices (Fig 2D). All canals were obturated by using cold lateral condensation (Fig 2 E, F) and after one month tooth was restored with amalgam filling. Postobturation radiograph revealed Vertucci type II root canal morphology in the palatal root (Fig F).

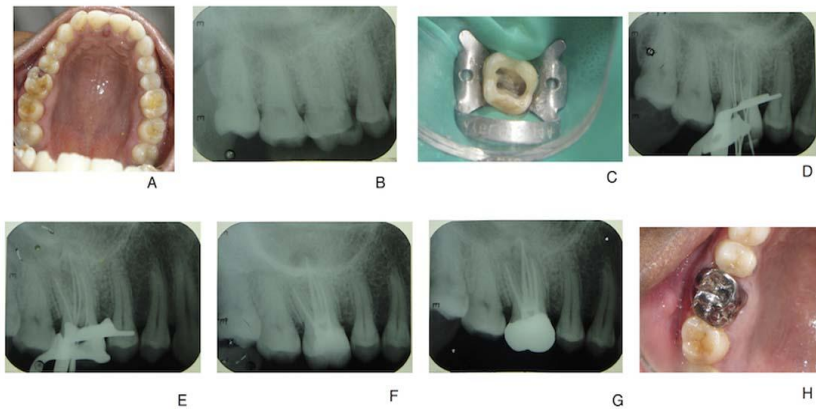


Fig A The preoperative clinical presentation showing mesial caries
 Fig B The preoperative radiograph showed no sign of periapical radiolucencies
 Fig C Clinical presentation after access and orifice enlargement
 Fig D Working length X-ray
 Fig E Master apical G.P X-ray
 Fig F The post operative radiograph showing two palatal canals joining at apical one third
 Fig G H A total of 18 month follow up. In the mean time tooth was restored with metal crown.

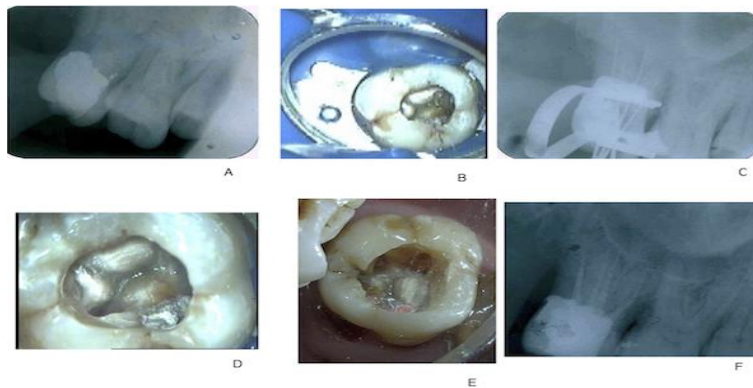


Fig A Preoperative radiograph showing already accessed and temporarily filled 17
 Fig B After access refinement and locating second palatal canal
 Fig C Working length X-ray
 Fig D After BMP AT 8 x magnification
 Fig E After obturation showing 4 distinct orifices
 Fig F Post operative radiograph showing 2 palatal canals

DISCUSSION

The root and root canal morphology of teeth varies greatly. Anatomic variation can be found in both maxillary first and second molar. Although the incidence of two palatal canals or roots might be very low and has been rarely described, this anomaly should not be left out of consideration during dental practice.

In our first case of maxillary first molar we found second palatal canal configuration similar to Vertucci^[10] type II. In our second case of maxillary second molar we found two palatal canals that remain separated till apex which is similar to Vertucci^[10] type IV. Christie^[8] et al and Peikoff^[11] et al in their retrospective studies have given different classification of maxillary second molar based on root canal variation. On basis of Christie classification Type I maxillary molars have two widely divergent, long, and tortuous palatal roots. The buccal roots are often “cow-horn-” shaped and less divergent. Type II maxillary molar has four separate roots, but the roots are often shorter, run parallel, and have buccal and palatal root morphology with blunt root apices. Type III maxillary molar is constricted in root morphology with the mesiobuccal, mesiopalatal, and distopalatal canal engaged in the web of root dentin. The distobuccal root in these cases appears to stand alone and may even diverge to the distobuccal. Based on this classification our first case might be type III and second case might be of type II. But in this classification identification of type II and a type III case is very difficult on a radiograph alone. Peikoff^[11] et al reported six variations of a second maxillary molar in a retrospective study on root canal treated 520 molars as three distinct roots and canals (56%), three separate roots and four canals (two mesiobuccal canals) (22.7%), three roots and canals uniting mesiobuccal and distobuccal canals (9%), two separate roots and canals (6.9%), a single root with one canal (3.1%), and four roots or canals including two palatal canals (1.4 %). According to this classification, our report

falls into the latter group. Up to now, the variant with four separate roots and four separate canals including two palatal was the least frequent abnormality, with its incidence ranging from 1.47 to 2.1%.^[12] This could be in our second case.

Wasti^[13] in an *in vitro* study using the clearing technique found a bifurcation of palatal canals of maxillary first molars with a comparatively high incidence of 33.3%. On the other hand, Cleghorn^[3] et al reviewed 14 articles that included 2,578 teeth in clinical and laboratory studies regarding the canal morphology of the palatal roots of first maxillary molars and reported that this root has a single canal and a single foramen 99% and 98.8%, respectively. This discrepancy in results could be due to the reason that these morphologic variations in preoperative radiographs are difficult to identify and very often impossible. So the visualization of pulp chamber, use of operating microscope, and electronic apex locator are more important. For this purpose, operating microscope usage in daily clinic could potentialize and facilitate the localization and handling of additional canals as a result of a significantly higher magnification of the field of view.^[14] Magnification could therefore increase the detection of additional canals. Buhley^[15] et al in their study have shown that the prevalence of detection of additional canals increased to 93% as a result of regular use of an operating microscope. In our second case with the help of operating microscope only we were able to locate the second palatal canal.

Properly designed and prepared access cavities is the initial step in locating canal orifices which will eliminate many potential problems during canal preparation and obturation. The observation of a palatogingival groove on palatal surface of crown and root also indicates the chances of two palatal canals. In second case of the present paper, a large access was required on palatal side to locate the 2 palatal canals. Clinical photograph of floor shows two well-separated palatal orifices. Teeth with 2

palatal roots often have a wider mesiodistal dimension of the palatal cusps, the access outline will be square rather than triangular in such cases. Vertucci [10] studied the proximity of canal orifices and their separation at apical area. If the separation of orifices is greater than 3 mm, canals remain separated through the entire length and usually joined when distance is less than 3 mm. In our cases we support this theory as the distance between the two orifices was less than 3 mm in our first case while in second case the distance was more than 3.

Recently, the use of cone beam or spiral computed tomography scan is valuable in diagnosis of anatomic variations. Use of these facilitates helps in easy detection of variations and number of root canal as compared to previously available techniques. Aggarwal [16] et al used in their case report a spiral computed tomography scan to determine whether the second palatal canal of a maxillary molar was truly in the palatal root. This can really be important in our second case. Only with a three-dimensional CT scan image or cone beam computed tomography we can be sure whether there are two distinct palatal roots are there or there are two canals in one root.

CONCLUSION

Based on the dental literature and this series of clinical cases, it is evident that knowledge of the anatomic morphology of the maxillary molars is essential for the success of endodontic treatment. It is very important that careful attention is paid to any evidence of additional root canals. Although such cases occur infrequently, the clinician should focus not only on variations of the buccal roots but also on palatal roots.

REFERENCES

1. Siqueira JF Jr., Ro cas IN. Clinical implications and microbiology of bacterial persistence after treatment procedures. *J Endod* 2008;34:1291–301.
2. Pecora JD, Woelfel JB, Sousa-Neto MD, et al. Morphologic study of the maxillary molars. Part II: Internal anatomy. *Braz Dent J* 1992;3:53–73.
3. Cleghorn BM, Christie WH, Dong CC. Root and root canal morphology of the human permanent maxillary first molar: a literature review. *J Endod* 2006;32:813–21
4. Baratto-Filho F, Zaitter S, Haragushiku GA, et al. Analysis of the internal anatomy of maxillary first molars by using different methods. *J Endod* 2009; 35:337–42.
5. Stone LH, Stroner WF. Maxillary molars demonstrating more than one palatal root canal. *Oral Surg Oral Med Oral Pathol* 1981;51:649–52.
6. Benenati FW. Maxillary second molar with two palatal canals and a palatogingival groove. *J Endod* 1985;11:308–10
7. Baratto-Filho F, Fariniuk LF, Ferreira EI, Pecora JD, Cruz-Filho AM, Sousa-Neto MD. Clinical and macroscopic study of maxillary molars with two palatal roots. *Int Endod J*. 2002;35:796–801.
8. Christie WH, Peikoff MD, Fogel HM. Maxillary molars with two palatal roots: a retrospective clinical study. *J Endod* 1991;17: 80–4.
9. Iqbal M, Fillmore E. Preoperative predictors of number of root canals clinically detected in maxillary molars: a PennEndo Database study. *J Endod* 2008;34:413–6.
10. Vertucci FJ. Root canal anatomy of the human permanent teeth. *Oral Surg Oral Med Oral Pathol* 1984;58:589–99.
11. Peikoff MD, Christie WH, Fogel HM. The maxillary second molar: variations in the number of roots and canals. *Int Endod J* 1996;29:365–9.
12. Caliskan MK, Pehlivan Y, Sepetc, iog̃ lu F, et al. Root canal morphology of human permanent teeth in a Turkish population. *J Endod* 1995;21:200–4.
13. Wasti F, Shearer AC, Wilson NH. Root canal systems of the mandibular and maxillary first permanent molar teeth of

- south Asian Pakistanis. *Int Endod J.* 2001;34:263–6
14. Sempira HN, Hartwell GR. Frequency of second mesiobuccal canals in maxillary molars as determined by use of an operating microscope: a clinical study. *J Endod* 2000;26:673–4.
15. Buhrley LJ, Barrows MJ, BeGole EA, Wenckus CS. Effect of magnification on locating the MB2 canal in maxillary molars. *J Endod* 2002;28:324–7.
16. Aggarwal V, Singla M, Logani A, et al. Endodontic management of a maxillary first molar with two palatal canals with the aid of spiral computed tomography: a case report. *J Endod* 2009;35:137–9.

How to cite this article: Mittal S, Goel R, Kumar V et.al. Maxillary first and second molars with two palatal root canals: Two case reports. *Int J Health Sci Res.* 2019; 9(4):332-337.
