

Case Report

# Enumerating Instantaneous Effect of Proprietary Herbal Drug Inhalation on the Patient of CAD with Significant LV Dysfunction- A Case Report

Kajaria Divya

Assistant Professor, Department of Kayachikitsa, All India Institute of Ayurveda, New Delhi

## ABSTRACT

Ayurveda is mainly known for its curative role in chronic disabling diseases and through era it is promoted as preventive medicine. The potential of Ayurvedic medicines in the management of emergency/ acute conditions is totally unexplored. Due to some unexplained reasons it is unanimously accepted by the scientific community that Ayurveda has no role in managing acute medicinal conditions like myocardial infarction, status asthmaticus, malignant hypertension, status epilepticus, etc. But as the time changes and with the integration of science and scientific parameters in the Ayurveda it is now possible to hunt the possible role of Ayurvedic therapies in the management of acute medicinal conditions. This article is a case report describing the effects of an Ayurvedic drug develop in an aerosol form and given via nasal route through nebulization in a patient of CAD- post PTCA with stenting to LAD, having significant left ventricular dysfunction and who was advised for CABG. The patient was present with chest pain and breathlessness. The patient was evaluate 30 minutes after administration of drug showed significant changes in HR, Cardiac Index, total peripheral resistance index, respiratory rate, ANS activity, Fatigue index, Electro-cardiac stability, Physical stress, Stress resistance, Arterial vessel elasticity, Peripheral vessel elasticity, Cardiovascular status and Cardiac functions. All the reports are electronically generated and presented in the article for the critical review of reader with the scope of further research for the standardization and its commercialization.

**Key Words:** Herbal aerosol, Cardiac Index, Arterial vessel elasticity, Stress resistance.

## INTRODUCTION

Cardiovascular diseases (CVDs) are the leading cause of death all over world including India where it attributed a quarter of all mortality. <sup>[1]</sup> Among CVDs, Ischemic heart disease and stroke are the predominant causes that accounts for >80% of CVD deaths. <sup>[2]</sup> It raises concern in the recent past due to alarming rise of incidences, early age of onset, coexisting comorbidity and high case of fatality. The disease become havoc for patients and the only diagnosis of CADs are sufficient to put patients in mental stress. This stress as propagated in the general population under the false banner of awareness is much more dreadful than the disease itself. Management of CADs is also

very cumbersome; whether it includes coronary artery bypass graft (CABG) or Percutaneous transluminal coronary angioplasty (PTCA) all are expensive and invasive techniques with no exception for the toxic side effects as all conventional medicines possess. Basically CVDs become epidemic in India, and in developing countries like India the cost burden produce by such ailment is very agonizing that need urgent search for some better alternatives. India being the heritage of world most ancient medical treatise having treasure of herbal remedy can become the world leader in searching a safe, non-invasive, cheap and effective remedy for CVDs. This case report illustrates the effect of Ayurvedic medicine

in the management of acute IHD.

## CASE REPORT

A male patient aged 52 years, known case of coronary artery disease (CAD)- post percutaneous transluminal coronary angioplasty (PTCA) with stenting to left anterior descending artery (LAD), unstable angina, significant double vessel disease with significant left ventricular dysfunction (LVEF= 35%), diabetes mellitus (DM) and hypothyroidism was presented with the complaints of breathlessness, chest pain and restlessness. The patient was admitted in the

conventional medicine hospital for the same complaints earlier and was advised for coronary artery bypass graft (CABG). He didn't give his consent and came to Ayurveda for the needful management. His physical examination reveals no cyanosis, edema and icterus. His Pulse rate was 88 bpm, regular, blood pressure was 100/60 mmHg,  $PSO_2$ - 96% with normal heart sound and normal respiratory sound. Abdomen was soft and non-tender with normal bowel sound. His previous investigations were as follows:

<ul style="list-style-type: none"> <li>• ECG- ST depression (lateral) Negative T wave (lateral, anterior)Left anterior hemiblock Probably MI (anterior)</li> <li>• 2D ECHO – LV normal in size with akinesia of mid anterior septum with moderate systolic dysfunction (LVEF =35%), LV RWMA, mild MR, moderate PAH.</li> <li>• Stress Echocardiography- Positive for reversible Ischemia.</li> <li>• Coronary Angiogram - Coronary Artery Double Vessel Disease with Left dominance.</li> </ul>	<ul style="list-style-type: none"> <li>• Hemogram- Hb-11.3, TLC-7000, Platelet count- 150000.</li> <li>• KFT, LFT- Urea- 33mg/dl, Creatinine – 0.80 mg/dl, <math>Na^+</math>- 143.0 mmol/L, <math>K^+</math>- 4.5 mmol/L, T.Bilirubin-1.0mg/dl, SGPT- 24 U/L.</li> <li>• S.CPK/CK-MB- 68 /16</li> <li>• TFT- <math>T_4</math>-147 nmol/l, TSH-1.01 uIU/ml</li> <li>• RBS- 106mg/dl</li> <li>• Viral marker-negative</li> </ul>
---	--

On-going conventional medicines: The patient was already taking anti-hypertensive (Telpress MT-50mg), antiplatelets (Ecosprin -75mg), statins (Rosuvastatin- 20mg), hypoglycemic (Diamicon- XR & Cetapin- XR- 500mg) and thyronorm (125mcg).

## TREATMENT & RESULT

The patient was nebulised with the 3ml aerosol of herbal drugs and was re-evaluated after 30 minutes. Effect of the herbal medicine on cardiorespiratory system as assessed by two different non-invasive FDA approved whole body bioimpedance technology and Accelerated Plethysmography technology; the reports were focusing Pre & Post effects on cardiac function, cardiovascular function, autonomic nervous system, digital stress scoring, hormonal imbalance and sleep disorder level.

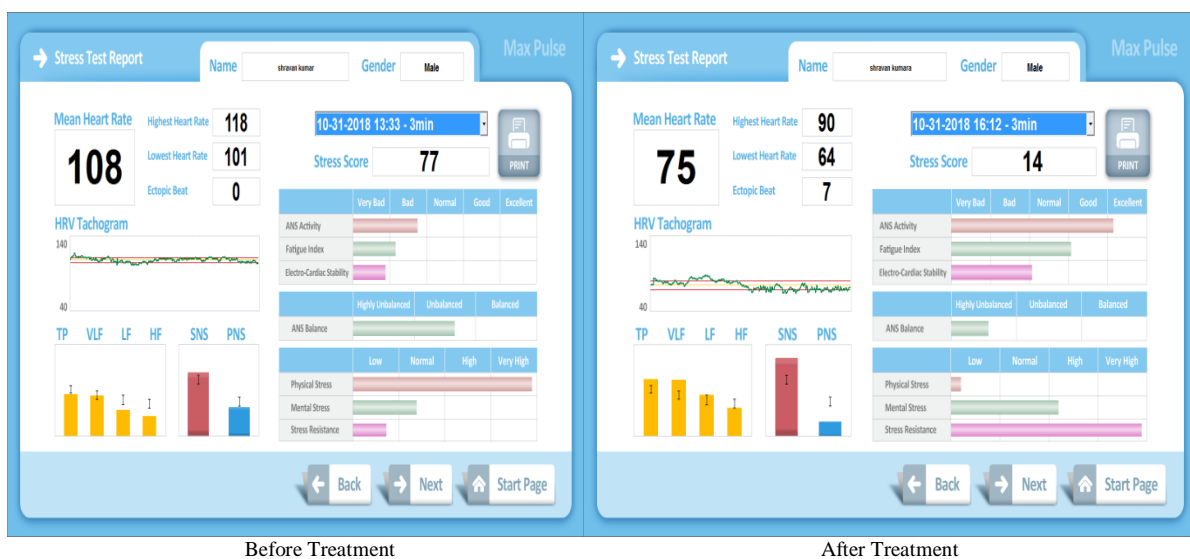

Fig. 1: Max-Pulse HRV-Based Stress & Autonomic Nervous System Before and After Treatment test report

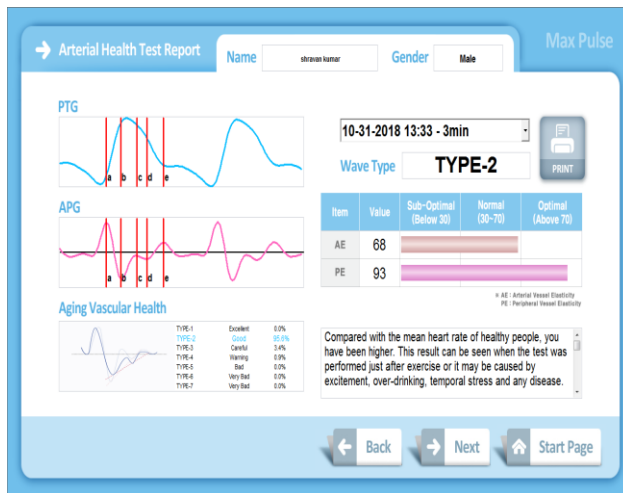


Fig. 2: Pre Treatment (AE- Arterial Elasticity, PE- Peripheral Vessels Elasticity)

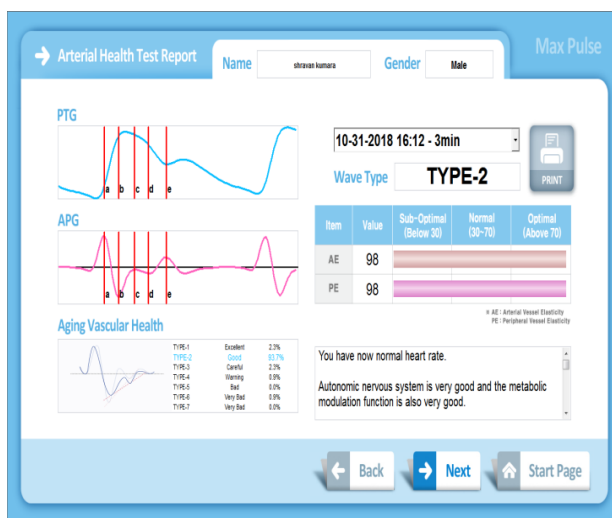
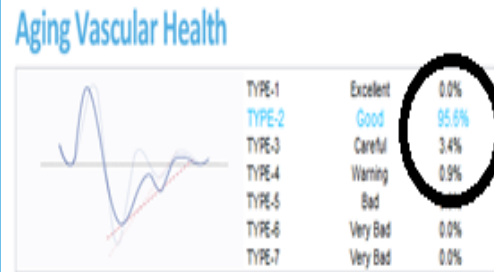
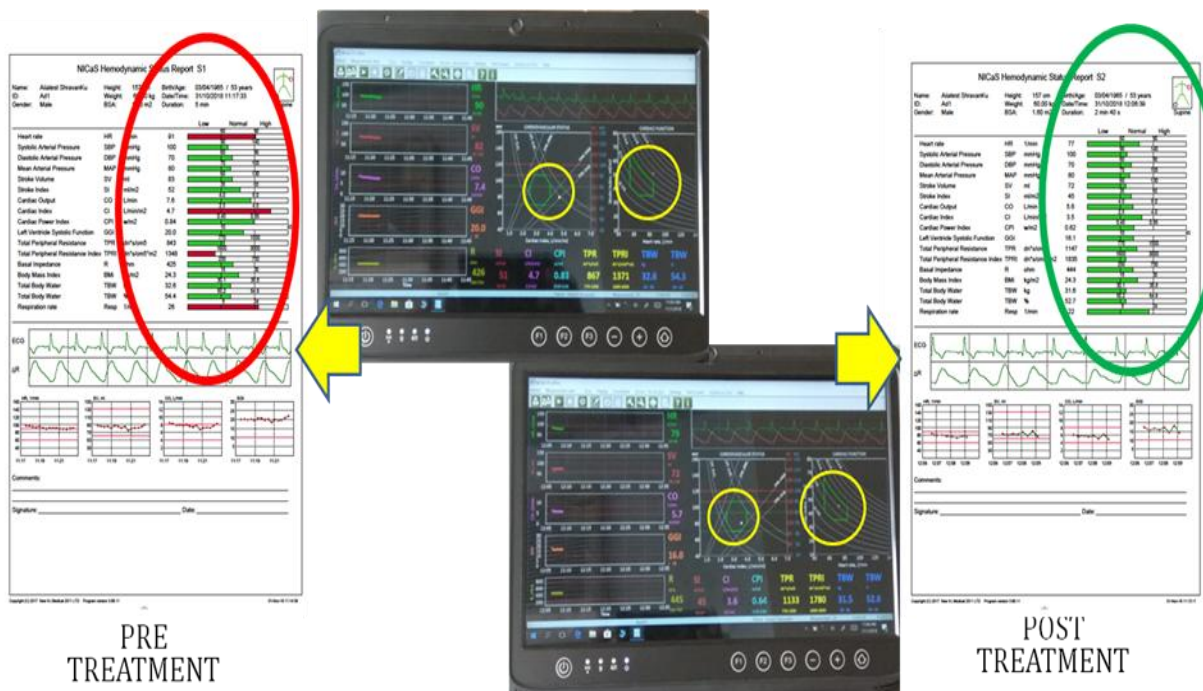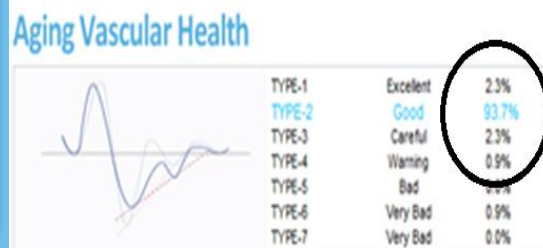Fig. 3: Post Treatment (AE- Arterial Elasticity, PE- Peripheral Vessels Elasticity)



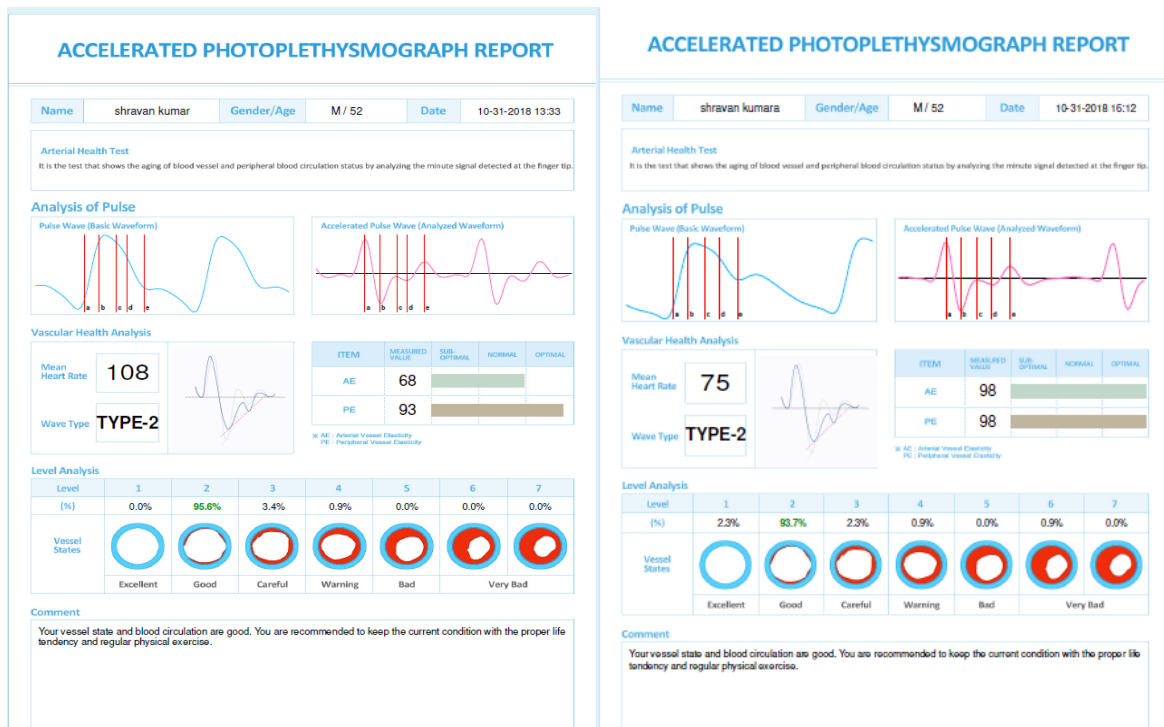


Fig. 5: Accelerated Plethysmograph Report Before and After Treatment with Drug

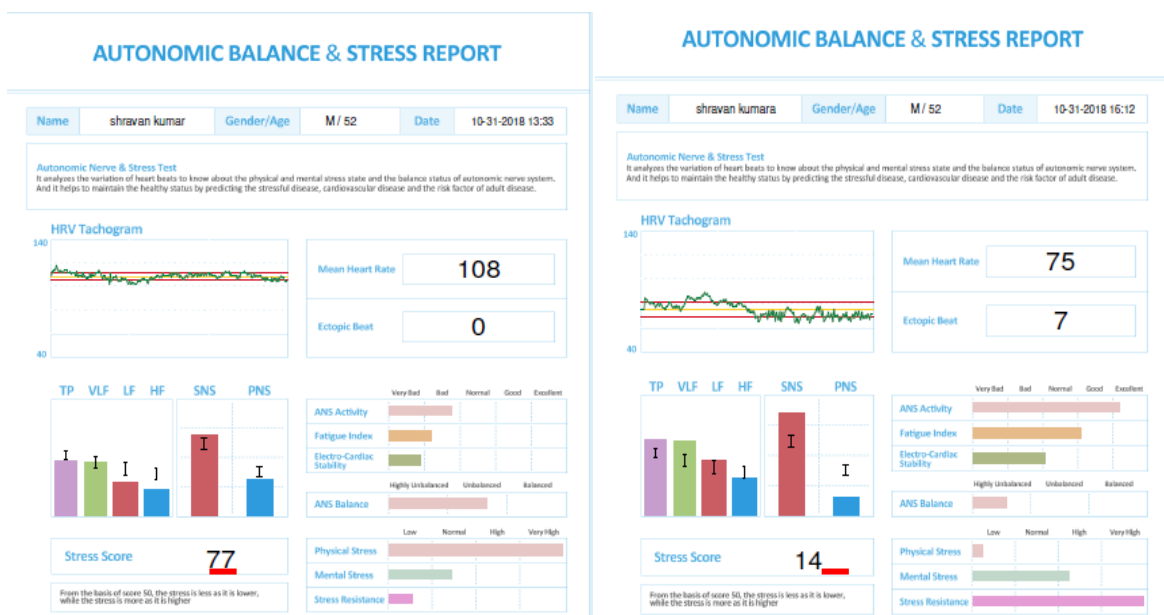


Fig. 6: Autonomic Balance & Stress Report Before and After Treatment with Drug

## DISCUSSION

Effect of drug given through nasal route in the form of aerosol produces significant changes in the stress level (BT= 77, AT=14), autonomic nervous system activity (BT= Bad, AT= Excellent), physical stress level which was very high before treatment becomes normal after treatment. The stress resistance which was low before treatment becomes very high after treatment

and fatigue index become normal after treatment. The mean heart rate (MHR) reduces from 108 bpm to 77 bpm after treatment. The result reveals that drug helps in reducing stress level, balance the autonomic system activity thereby normalize the heart rate and reduces the excessive cardiac pressure. Accelerated Plethysmograph report showed that arterial vessel elasticity increases from 68 to 98

(become normal to optimal) with type 2 wave representing level 2 (95.6%) of vessel status showing good vessel state and blood circulation after treatment. Hemodynamic status report showed significant changes in Heart Rate (BT= 91bpm, AT= 77 bpm), Cardiac Index (BT= 4.7 L/min/m<sup>2</sup>, AT= 3.5 L/min/m<sup>2</sup>), Total Peripheral Resistance Index (BT=1348 dynes\*sec /cm<sup>5</sup>/m<sup>2</sup>, AT= 1835 dynes\*sec /cm<sup>5</sup>/m<sup>2</sup>), Respiratory rate (BT= 26/ min, AT= 22/min). All these parameters become normal after treatment. The drug is hydroalcoholic extract of herbs that are reported in Ayurveda having cardioprotective and bronchodilator activities. The herbs present in the drug are rich source of volatile oil suggesting their probable effect on brain dopamine system. Effect of drug was assessed after 30 minutes of administration which reveals the changes in the hemodynamic status, arterial elasticity, cardiac index and cardiac functions that indirectly support the fact that administrating drug via nasal route fasten drug assimilation into circulation by direct diffusion through alveoli. Estimation of drug reaching upto alveoli and diffusing into blood stream will be helpful in optimizing the dose of drug for future studies.

## CONCLUSION

It will be very early and misleading to draw any concrete assessment on the basis of one patient study. Despite of this restriction the study open a totally new area of research for management of cardiac diseases. It is quite possible that in near future merely inhaling or delivering drug through nasal route manage hypoxemia and restore cardiac functions and hemodynamic homeostasis.

## ACKNOWLEDGEMENT

The authors are thankful to Mr. Alok Vashisth, Director Health Care Marketing & Research Development for Modernization & Preventive Aspects, BVM Meditech Private Ltd. for extending his sincere help in carrying out investigations.

## REFERENCES

1. Prabhakaran Dorairaj, Jeemon Panniyammakal, Roy Ambuj. Cardiovascular Diseases in India; Current Epidemiology and Future Directions. *Circulation*. 2016;133:1605–1620.
2. Chauhan Shraddha, Aeri Bani Tamber. Prevalence of cardiovascular disease in India and its economic impact- A review. *International Journal of Scientific and Research Publications*. 2013; 3 (10).

How to cite this article: Divya K. Enumerating instantaneous effect of proprietary herbal drug inhalation on the patient of CAD with significant LV dysfunction- a case report. *Int J Health Sci Res*. 2019; 9(3):337-341.

\*\*\*\*\*