

Case Report

# Pneumothorax in Marfan Syndrome: A Case Report

Vikas R. Ratnaparkhe<sup>1</sup>, Kavita Upadhyay<sup>2</sup>

<sup>1</sup>Consulting Physician (MD, Medicine), Dr. Hedgewar Hospital, Aurangabad.

<sup>2</sup>DNB Medicine Resident, Dr. Hedgewar Hospital, Aurangabad.

Corresponding Author: Vikas R. Ratnaparkhe

## ABSTRACT

Marfan syndrome is a multisystem connective tissue disorder of autosomal dominant inheritance, which typically involves manifestations of the cardiovascular, skeletal, and ocular systems. Pulmonary involvement occurs less frequently.

We report a case of a 22-year-old male suffering from sudden onset, progressive shortness of breath and right-sided chest pain. On physical examination he had decreased breath sound on the right side of chest, together with marfanoid habitus. The chest X ray suggested Rt. sided pneumothorax. ICD insertion was done. This case indicates that pulmonary symptoms like secondary spontaneous pneumothorax, bullae, emphysema can manifest as initial symptoms of undiagnosed Marfan syndrome.

**Keywords:** Marfan syndrome, pneumothorax, ICD.

## INTRODUCTION

Marfan syndrome is a multisystem connective tissue disorder of autosomal dominant inheritance, involving manifestations of the cardiovascular, skeletal, and ocular systems. The incidence of Marfan syndrome is approximately 2–3 in every 10,000 individuals, and pulmonary involvement occurs much less frequently. Previously, few publications described spontaneous pneumothorax in Marfan syndrome and not until recently, the association between pneumothorax and Marfan syndrome was further explored by Karpman et al. <sup>(1)</sup> the incidence ranged between 4.8% and 11%. <sup>(5)</sup> We here present a case with spontaneous pneumothorax as an initial diagnosis of Marfan syndrome.

## CASE REPORT

A 22 yrs. male was admitted with C/o Sudden onset of severe right sided chest

pain, Breathlessness, Uneasiness, Cough without expectoration of 3 days duration.

O/E Pulse: 102/min, RR: 30/min, BP: 120/90, Tall, thin, long extremities, fingers & toes. Narrow thin face, high arched palate, reduced upper-to-lower body segment ratio. Positive wrist sign (Walker's sign), Pes planus (Flat feet), Steinberg sign.

## INVESTIGATIONS:

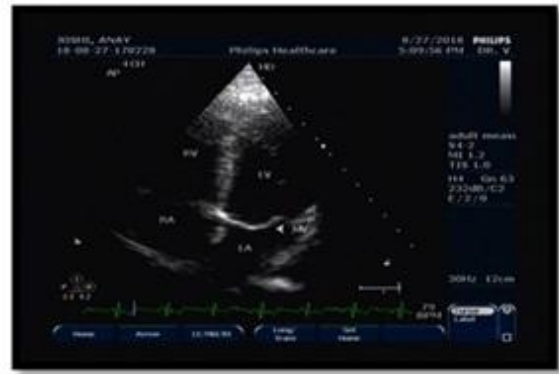HB: 14.7 gm%, WBC: 9800/ $\mu$ L, Platelet: 2, 45,000/ $\mu$ L, Creat: 0.77 mg/dl, SGOT(AST): 16.30 U/I, SGPT(ALT): 15.00 U/I, NA: 139, K+: 3.60, Chl: 108 meq/L.

Chest X-ray posteroanterior (PA) view confirmed the right-sided pneumothorax (fig. 5)

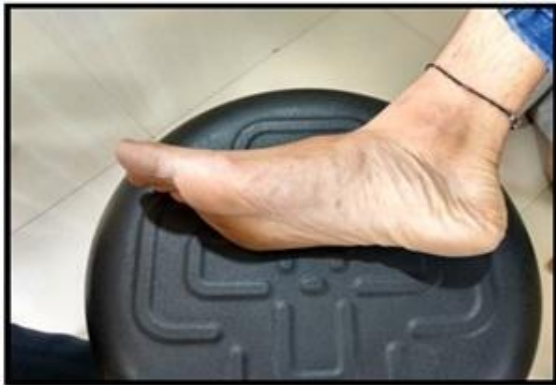2 D Echo: Mitral valve prolapsed & mitral regurgitation.

According to the 2010 Revised Ghent Nosology for Marfan syndrome, the patient was diagnosed as Marfan syndrome. <sup>(2)</sup>

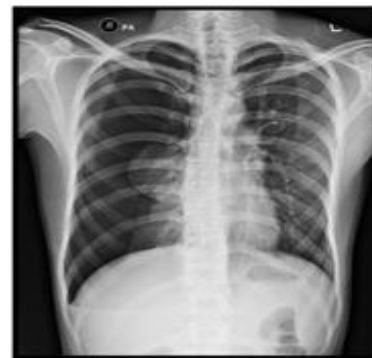As he presented IN the following situations: Arachnodactyly, Positive wrist sign(walker's sign) (fig. 2), Steinberg signs, Characteristic facial appearance: Enophthalmos, Dolichocephaly, Narrow & thin face. Above-average height Pes planus (flat feet) (fig. 1), Teeth crowded, Severe myopia >3 diopters, Spontaneous Pneumothorax Mild to moderate mitral valve prolapse (fig. 4)



(fig. 4) Mitral valve prolapse



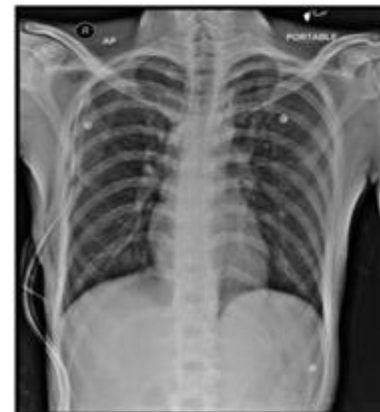(fig. 1) Pes planus (flat feet)



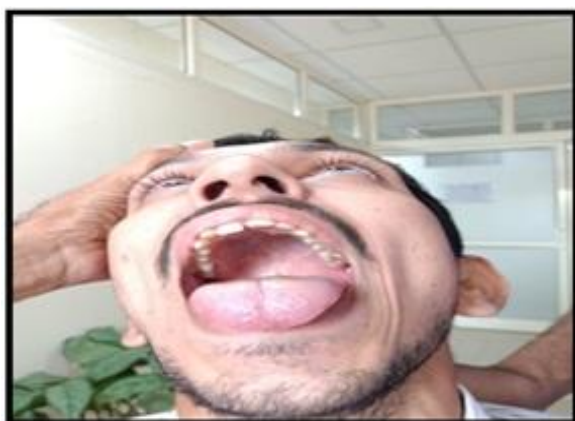
(fig. 5) right-sided pneumo



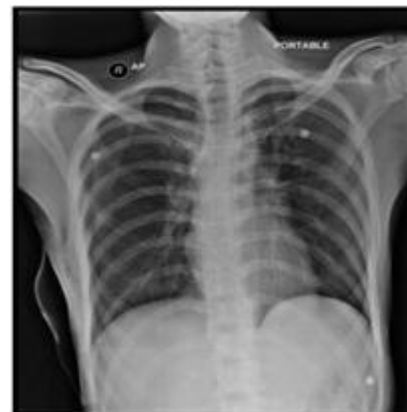(fig. 2) Positive wrist sign(walker's sign)



(fig. 6) after ICD insertion



(fig. 3) High arch palate



(fig. 7) ICD removal

### **TREATMENT GIVEN:**

ICD insertion done and assured expansion of collapsed lung.

Antibiotics and IV fluids were given as per the need of the situation for 7 days.

ICD was removed after 4 days.

Chest physiotherapy was given thereafter.

### **DISCUSSION**

Undiagnosed Marfan, admitted to hospital due to spontaneous pneumothorax. The diagnosis of Marfan syndrome was based on his marfanoid habitus, characteristic as per Ghent criteria. MFS is an autosomal dominant disorder. About 75% of the time, the condition is inherited from a parent, while 25% of the time it is a new mutation.

Patients with Marfan syndrome usually harbor mutations involving the gene FBN1 encoding the connective tissue protein fibrillin-1. (12) Fibrillin-1 is an important matrix component of both elastic and non-elastic tissues.

No cure for Marfan syndrome is known. Many people have a normal life expectancy with proper treatment. Surgery for repair of the aorta or replace a heart valve. Mitral valve prolapse and aortic aneurysm are the serious complications in Marfan syndrome.

The rate of mitral valve involvement is considerable and makes about 75%, while in more severe variants with myxomatous valve alterations it approximates 28%. Leaflets of aortic & tricuspid valves are also subjects to the characteristic changes.

A heart murmur, abnormal reading on ECG, symptoms of angina can indicate prolapsed of mitral valve or aortic aneurysm.

Pulmonary symptoms are not a major feature of MFS, but spontaneous pneumothorax is common.

Pneumothorax in patients with Marfan syndrome was reported between 5% and 11%. (3) Men were more affected than female patients. (4) Approximately, 16% of patients with Marfan syndrome have pulmonary symptoms, and pulmonary

involvements may contribute to 10% of death in patients with Marfan syndrome

Other possible pulmonary manifestations of MFS include sleep apnea and idiopathic obstructive lung disease.

Treatment of a spontaneous pneumothorax is dependent on the volume of air in the pleural space and the natural progression of the individual's condition. A small pneumothorax might resolve without active treatment in one to two weeks.

Recurrent pneumothoraces might require chest surgery. Moderately sized pneumothoraces might need chest drain management for several days in a hospital. Large pneumothoraces are likely to be medical emergencies requiring emergency decompression.

### **CONCLUSION**

Early diagnosis based on atypical symptoms of Marfan syndrome like pneumothorax and bullae helped in the early evaluation of cardiovascular system and early managements of the disease, which proved to increase life expectancy of patients with Marfan syndrome markedly.

Progress in the past decades has led to an improved understanding of the cause, pathophysiology, clinical manifestations, and treatments of Marfan syndrome.

Pneumothorax should be considered immediately, along with aortic dissection, in any patient with Marfan's syndrome in whom acute chest pain, with or without dyspnea, develops.

### **REFERENCES**

1. Karpman C, Aughenbaugh GL, Ryu JH. Pneumothorax and Bullae in Marfan Syndrome. *Respiration*. 2011;82(3):219-24.
2. Weiming Hao, Yong Fang, Hao Lai et al. Marfan syndrome with pneumothorax: case report and review of literatures. *Journal of Thoracic Disease*.; *J Thorac Dis* 2017; 9(12):E1100-E1103.
3. Carolina Viveiro, Patricia Rocha, Cristiana Carvalho et al. Spontaneous pneumothorax as manifestation of Marfan syndrome. *BMJ Case Rep*. 2013 Dec 5;2013.

4. Hall JR, Pyeritz RE, Dudgeon DL et al. Pneumothorax in the Marfan Syndrome: Prevalence and Therapy. *Ann Thorac Surg.* 1984 Jun;37(6):500-4.
5. Chiu HH, Wu MH, Chen HC, et al. Epidemiological profile of Marfan syndrome in a general population: a national database study. *Mayo ClinProc* 2014;89:34-42. 10.1016/j.mayocp.2013.08.022

How to cite this article: Ratnaparkhe VR, Upadhyay K. Pneumothorax in Marfan syndrome: a case report. *Int J Health Sci Res.* 2019; 9(11):143-146.

\*\*\*\*\*