

Case Report

# Sclerosing Epithelioid Fibrosarcoma of Thigh: Need for Timely Diagnosis and Aggressive Management

Suhaib Rawoot

Chief Resident, Department of General Surgery, Grant Medical College & Sir JJ Group of Hospitals, Mumbai-400008.

## ABSTRACT

Sclerosing epithelioid fibrosarcoma (SEF) is a rare soft tissue sarcoma occurring in the extra osseous sites. They account to less than 1 % of all soft tissue sarcomas. Only 89 cases of SEF have been reported till date. <sup>[1]</sup> We hereby present a rare case of SEF in a 17 year old male who presented with a swelling in the right thigh of 2 months duration. Fine needle aspiration cytology of the swelling revealed it to be a spindle cell tumour. He underwent wide local excision. Histopathology and immuno histochemistry proved it to be sclerosing epithelioid fibrosarcoma. A case report and review of literature is presented below. This is also the first case to be reported from the Indian subcontinent to the best of our knowledge.

**Key words:** Sclerosing epithelioid fibrosarcoma, timely diagnosis, aggressive management

## INTRODUCTION

Sclerosing epithelioid fibrosarcoma (SEF) is an uncommon fibrosarcoma of intermediate-grade. It was first described in 1995 by Meis-Kindblom and colleagues and has lately been recognized as a distinct clinical entity. <sup>[2]</sup> SEF is a malignancy of the older adult. The mean age of presentation is 47 years (range 14–87 years) with an equal sex distribution. <sup>[1,3]</sup> Only 10% of patients are younger than 20 years at time of diagnosis. <sup>[1]</sup> It occurs primarily in the deep musculature and frequently associated with the adjacent fascia or periosteum. SEFs mainly present as tumours of the lower extremities (39%), followed by the trunk (21%) and upper extremities (14.5%). Rare locations like pituitary gland, intraspinal or base of penis have also been described. <sup>[1-8]</sup> SEFs tend to have a high rate of local recurrence and distant metastasis. (30%-

40%). <sup>[9-11]</sup> SEFs are still a surgical enigma as there is no standard treatment regimen available, in spite of the aggressive nature of the disease. A case report and a review of literature have been presented, emphasising the aggressive management required to treat the disease.

## CASE REPORT

A 17 year old male patient presented with a swelling in the right thigh for 2 months, which rapidly increased in size. A hard swelling situated in the subcutaneous plane without fixity to the underlying structures was seen. There was no clinically palpable lymphadenopathy. Magnetic Resonance Imaging (MRI) of the right thigh showed a mass in the right thigh measuring 6x4x4.5 cm in the subcutaneous plane with no communication with the muscular component of the thigh. (Fig 1)

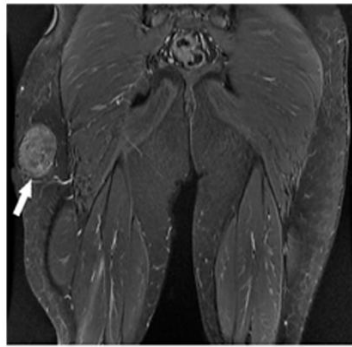


Fig. 1(a)

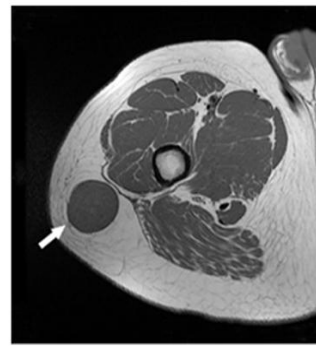


Fig. 1(b)

Fig 1) Magnetic Resonance Imaging of the right thigh showing a mass in the subcutaneous plane measuring 6cmsX4cmsX 4.5cms. A) coronal section B) Axial section

The patient underwent a wide local excision. The margins were free of disease. Grossly the tumour measured 6x4x4.5cm. Histopathology diagnosed it be a case of Sclerosing Epithelioid Fibrosarcoma. This was confirmed on immunohistochemistry, which was positive for vimentin and Bcl 2(Fig 2) and negative for pancytokeratin, epithelial membrane antigen, Smooth muscle actin, desmin, S-100, CD 34, HMB 45, p53 and pericytoplasmic nuclear antigen.

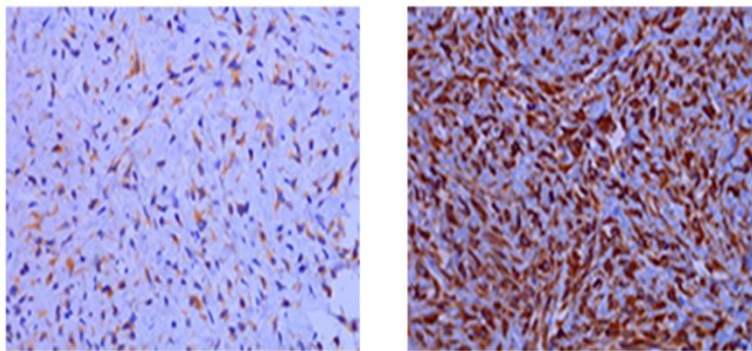


Fig. 2 A & B: ImmunoHisto Chemistry Showing Sclerosing epithelioid fibrosarcoma with Positivity for a) Vimentin b) BCL-2

The Ki 67 proliferative index was < 1 percent. Computed Tomography of the Chest and abdomen, and bone scan revealed no evidence for metastasis. The patient received chemotherapy and radiotherapy. The patient is disease free and asymptomatic after 2 years of follow up.

## DISCUSSION

Sclerosing epithelioid fibro sarcoma (SEFs) is a rare neoplasm of intermediate grade which belongs to the family of fibrosing fibro sarcomas. The other tumours included in this group are low-grade fibromyxoid sarcoma (FMS) and hyalinising spindle cell tumor with giant rosettes.<sup>[12]</sup> This was first described by Meis-Kindblom

et al in 1995. Since then 89 cases have been reported till date. However, the lack of timely diagnosis and standard treatment guidelines has been associated with an increased risk of local recurrence and metastasis from this disease.

Clinically it is a disease of the adults with a mean age of presentation of 47 years, with an equal sex incidence. Less than 10 % of the tumours occur in individuals less than 20 years as seen in our patient. The most common site for the tumour is in the lower extremities followed by trunk and upper extremities.

SEF shares some pathologic features with two other fibrosing fibrosarcomas, low-grade fibro-myxoid sarcoma and

hyalinising spindle cell tumor with giant rosettes. [3] Criteria for diagnosing this uncommon tumour include: small to medium cell size, clear or pale cytoplasm, cellular arrangement in cords and strands, dense collagenous stroma; vimentin staining; rough endoplasmic reticulum and a Golgi apparatus producing, collagen secretion granules. [8] Histologically, SEF predominantly consists of epithelioid cells arranged in strands, nests, and/or sheets, and set in a fibrotic and extensively hyalinised stroma. [3,12] As these tumours are related to each other, immunohistochemistry is helpful in differentiating them from one another.

The consistent immunohistochemical finding is a strong and diffuse reactivity for vimentin, and negative for other markers like pan cytokeratin, smooth muscle actin, and desmin. [3,4] However a subset of cases stain for Epithelial Membrane Antigen (EMA) [2,4,8] a finding that may be related to the tumour's epithelioid phenotype. Some rare cases also express Neuron Specific Enolase (NSE) [2,13] or S-100 protein. [2,14,15]

Ki-67 is a nuclear antigen which is expressed only when mitosis occurs. There is a correlation between high Ki-67 labelling index, (especially, more than 20%) and poor clinical diagnosis in soft tissue sarcoma. [16] In a recent case study it was seen that SEFs with metastases presented with a much higher proliferative activity indicated by 60%. In contrast, the Ki 67 score in primary tumours was 6-7% as seen in our case. (Ki 67 score < 1%)

On a genetic level, Sclerosing epithelioid fibrosarcoma is characterized by rearrangement of 10p11. [15,17] Ultrastructurally, cells of SEF resemble fibroblasts due to abundant rough endoplasmic reticulum. [18]

Follow-up data indicate that SEF is an aggressive tumor with mortality rates ranging between 25% and 57%. [2,3] The high mortality rate observed in patients with SEF may also be due to the lack of experience of most of the physicians in how to treat patients with SEF potentially leading

to inadequate therapy and unfavourable outcome. [1] This when coupled with the lack of timely diagnosis can lead to presentation of the disease in advanced stages leading to increased mortality. In a case presented by C Ossendorf et al [1] it was seen that the time taken for the diagnosis of the disease was 33 months. In our case the time taken to make the diagnosis was 21 days.

Once diagnosed every effort for an aggressive management of this disease has to be carried out as this disease is known to recur and metastasize years after surgery. Meis-Kindblom reported that the median interval to the first local recurrence was 4.8 years (2.3 to 11 years) and the median interval to metastases was 7.7 years (4.7 to 14 years). [1] The tumour can metastasize to the lungs, skeleton, chest wall/pleura, pericardium, and brain. [1] The most frequent site of distant tumour manifestation was the lung, followed by osseous lesions to multiple bones and to the pleura/chest wall. [2] In addition, SEF shares the potential for lymph node metastasis with other epithelioid malignant soft tissue tumours such as epithelioid sarcoma [19] and epithelioid malignant peripheral nerve sheath tumor. [20]

Even though our patient had no evidence of metastasis at the time of presentation on Computed tomography of the abdomen and pelvis and bone scan, he received 6 cycles of doxorubicin, methotrexate and cisplatin based chemotherapy and regional radio therapy to reduce the risk of local recurrence/metastasis. The patient is disease free and has no recurrence or metastasis after 2 years of follow up.

## CONCLUSION

A high index of suspicion is required, and immuno histochemistry is helpful in diagnosis. Aggressive management in the form of chemoradiotherapy must be provided to avoid local recurrence and metastasis.

## REFERENCES

1. Ossendorf C, Studer G M, Bode B, Fuchs B, "Sclerosing epithelioid fibrosarcoma: case presentation and a systematic review," *Clinical Orthopaedics and Related Research* 2008; 466:1485–91
2. Meis-Kindblom J M, Kindblom L G, Enzinger F M. "Sclerosing epithelioid fibrosarcoma: a variant of fibrosarcoma simulating carcinoma." *American Journal of Surgical Pathology* 1995; 19:979–93.
3. Antonescu C R, Rosenblum M K, Pereira P, Nascimento A G, Woodruff J M. "Sclerosing epithelioid fibrosarcoma: a study of 16 cases and confirmation of a clinicopathologically distinct tumor," *American Journal of Surgical Pathology* 2001;25: 699–709.
4. Hindermann W, Katenkamp D. "Sclerosing epithelioid fibrosarcoma," *Pathologie* 2003; 24:103–8.
5. Massier A, Scheithauer W B, Taylor H C, Clark C, Llerena L. "Sclerosing epithelioid fibrosarcoma of the pituitary," *Endocrine Pathology* 2007; 4: 233–8.
6. Battiata A P, Casler J. "Sclerosing epithelioid fibrosarcoma: a case report," *Annals of Otolaryngology, Rhinology and Laryngology*. 2005;114: 87–9.
7. Bilsky M H, Scheffler A C, Sandberg D I, Dunkel I J, Rosenblum M K. "Sclerosing epithelioid fibrosarcomas involving the neuraxis: report of three cases," *Neurosurgery*. 2000; 47: 956–60.
8. Eyden B P, Manson C, Banerjee S S, Roberts I S D, Harris M, "Sclerosing epithelioid fibrosarcoma: a study of five cases emphasizing diagnostic criteria," *Histopathology*. 1998; 33:354–60.
9. Sassi S H, Dhouib R, Ben Dhaou S. "Sclerosing epithelioid fibrosarcoma. A case report," *Revue de Chirurgie Orthopedique et Reparatrice de l'Appareil Moteur*. 2008; 94: 92–5.
10. Smith P J, Almeida B, Krajacevic J, Taylor B. "Sclerosing epithelioid fibrosarcoma as a rare cause of ascites in a young man: a case report," *Journal of Medical Case Reports*. 2008; 2: 248–51.
11. Tomimaru Y, Nagano H, Marubashi S. "Sclerosing epithelioid fibrosarcoma of the liver infiltrating the inferior vena cava," *World Journal of Gastroenterology*. 2009 ; 15:4204–8.
12. Antonescu C R, Erlandson R A. "Fibrosarcoma mimicking plasmacytoma or carcinoma: an ultrastructural study of 4 cases". *Ultrastructural Pathology* 2001; 25: 31–7.
13. Hanson I M, Pearson J M, Eyden B P, Slawik S, Harris M, "Evidence of nerve sheath differentiation and high grade morphology in sclerosing epithelioid fibrosarcoma." *Journal of Clinical Pathology*. 2001; 54:721–3.
14. Reid R, Barrett A, Hamblen D L. "Sclerosing epithelioid fibrosarcoma," *Histopathology*. 1996;28: 451–6.
15. Gisselsson D, Andreasson P, Meis-Kindblom J M, Kindblom L G, Mertens F, Mandahl N. "Amplification of 12q13 and 12q15 sequences in a sclerosing epithelioid fibrosarcoma," *Cancer Genetics and Cytogenetics*. 1998;107: 102–6.
16. Folpe AL, Gown AM. *Enzinger and Weiss's Soft Tissue Tumors*. 4th edition. St. Louis, Mo, USA: Mosby. Immunohistochemistry for analysis of soft tissue tumors 2001; 199–245.
17. Ogose A, Kawashima H, Umezumi H. "Sclerosing epithelioid fibrosarcoma with der(10)t(10;17)(p11;q11)," *Cancer Genetics and Cytogenetics*. 2004;152:136–40.
18. Jiao Y F, Nakamura S I, Sugai T. "Over expression of MDM2 in a sclerosing epithelioid fibrosarcoma: genetic, immunohistochemical and ultrastructural study of a case." *Pathology International*. 2002; 52:135–40.
19. Prat J, Woodruff J M, Marcove R C. "Epithelioid sarcoma. An analysis of 22 cases indicating the prognostic significance of vascular invasion and regional lymph node metastasis," *Cancer*. 1978; 41:1472–87.
20. Evans L. "Low-grade fibromyxoid sarcoma. A report of two metastasizing neoplasms having a deceptively benign appearance," *American Journal of Clinical Pathology*, 1987; 88: 615–9.

How to cite this article: Rawoot S. Sclerosing epithelioid fibrosarcoma of thigh: need for timely diagnosis and aggressive management. *Int J Health Sci Res*. 2019; 9(10):271-274.

\*\*\*\*\*