

Case Report

Serous Papillary Cystadenofibroma of Ovary: A Rare Case Report

Sujata S. Kumbhar¹, Avinash M. Mane², Purva S. Mayekar³, Saswati Boral³

¹Associate Professor, Department of Pathology, KIMS, Karad

²Assistant Professor, Department of Pathology, KIMS, Karad

³Tutor, Department of Pathology, KIMS, Karad

Corresponding Author: Avinash M. Mane

ABSTRACT

Background - Benign cystadenofibroma of ovary is a rare, slow growing benign epithelial neoplasm of unknown etiology, mostly seen in 15 to 65 years of women. It contains epithelial and fibrous stromal components. Most tumours are asymptomatic and are usually detected incidentally during an abdominal ultrasound, performed for other reasons.

Case history - In our case while operating for tubal ligation in 25 years old non symptomatic female, a left ovarian cystic mass was incidentally found. Microscopic findings revealed serous papillary cystadenofibroma.

Discussion - Benign cystadenofibroma in majority of cases present as single mass within ovary, though rarely can present as multiple masses. These are usually detected incidentally and may resemble a malignant neoplasm.

Key words: Benign, serous papillary cystadenofibroma, ovary.

INTRODUCTION

Surface epithelial stromal tumors are the most common neoplasms of the ovary. These tumors include different types namely, serous, mucinous, endometrioid, clear cell and transitional cell along with combination of these types.^[1]

Surface epithelial tumors account for more than 90% of ovarian tumors, of which serous tumors comprise 46%. Sex-cord stromal tumors constitute 8% of ovarian tumors, fibroma being the commonest, comprising 70% in this category.^[2]

Ovarian cystadenofibroma is a rare benign tumor mostly seen in women of 15 to 65 years of age.^[3] It is a slow growing benign epithelial tumor of unknown etiology. It usually occurs on a combination of solid and cystic component.

These tumors may appear cystic and have thin walls with lack of solid areas.

These tumors may also show papillary projections. Grossly fibromas are usually solid and firm. Cystic degeneration may rarely occur in fibromas.

CASE REPORT

A 25 yr old female with history of P2L2 was posted for Abdominal Tubal ligation with no significant complaints. No history of vaginal bleeding /abdominal pain / increased in size of abdomen. All routine investigations performed were within normal limits. While operating for tubal ligation the gynaecological surgeon incidentally found a left ovarian cyst measuring about 4 cm which was sent for histopathological reporting along with cut pieces of fallopian tube. Right sided ovary was normal.

On follow up of the patient, she was doing well with no other complaints.

GROSS EXAMINATION –

We received a left sided ovarian cyst measuring 4.3x3.5x1.7cm and weighing 20 gms. External surface was smooth, grey white and showed congested blood vessels on cutting open, a single uniloculated cyst filled with serous fluid was noted and showed focal areas of papillary excrescences. (Fig. 1)

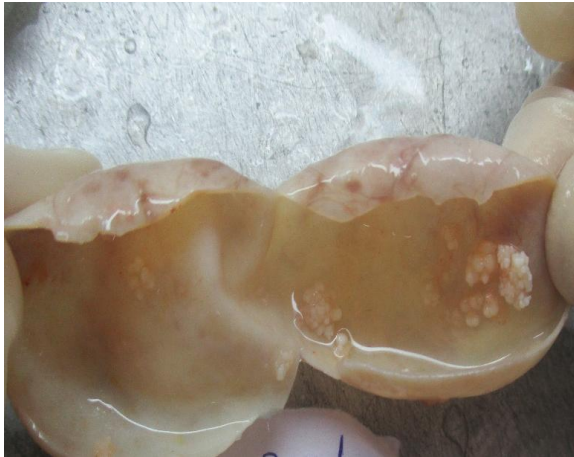

Fig. 1 : Uniloculated cyst filled with serous fluid and showing focal areas of papillary excrescences

On microscopy, section showed cyst wall with simple papillary processes lined by cuboidal epithelium and stroma containing spindly fibroblasts. There was no atypia, no architectural complexity and no invasion. (Fig 2, Fig 3 and Fig 4)

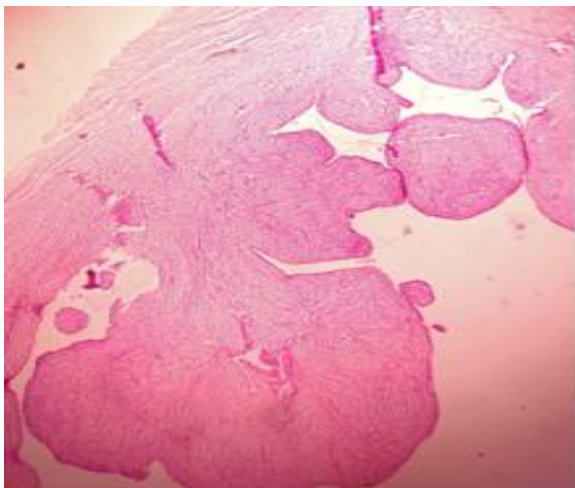


Fig 2 : Cyst wall with simple papillary processes (H and E 40X)

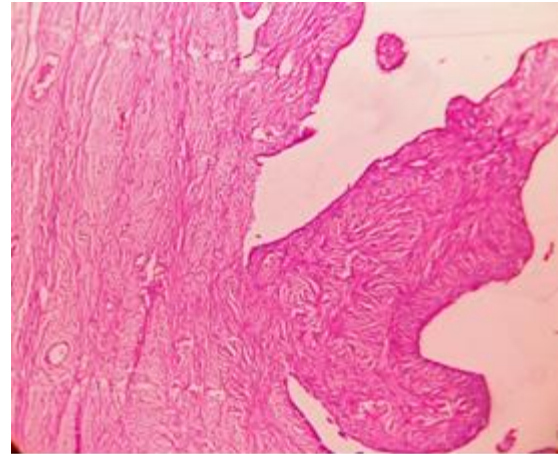


Fig 3: Stroma containing spindly fibroblast (H and E 100X)

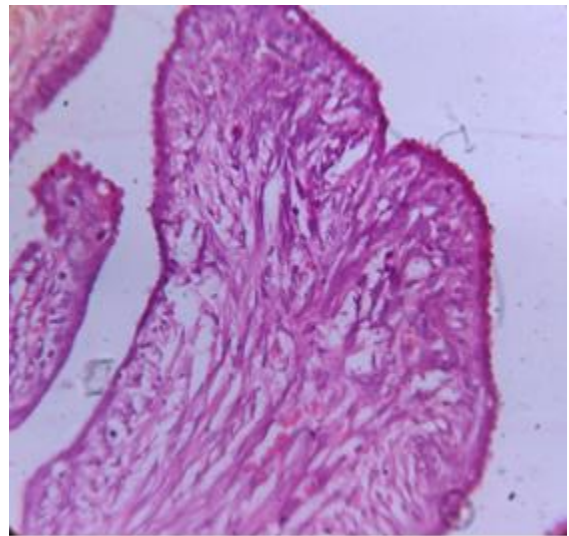


Fig4: Stroma containing spindly fibroblast (H and E, HP :1000X)

We diagnosed the lesion as Serous Papillary Cystadenofibroma- Left ovarian cyst

DISCUSSION

Benign Serous Cystadenofibroma of Ovary can occur worldwide in women of any age, race or ethnicity. Nevertheless, it is more common between the ages 15-65 years. [3] It is an uncommon benign neoplasm containing epithelial and fibrous stromal components. It usually occurs as a combination of cystic and solid mass within the ovary. In majority of the cases, the tumor is present as a single mass within the ovary; though rarely, the tumor can occur as multiple masses within a single ovary, or it may affect both the ovaries as well. These tumors are considered to be serous type of

tumors based on their characteristic appearance under a microscope.

The etiology of these tumors is unknown but mostly occurs spontaneously. These tumors present as painless, well circumscribed mass in the ovary.

Benign Serous cystadenofibroma of Ovary usually presents with signs and symptoms, such as abdominal pain, vaginal bleeding but many such tumors show no signs and symptoms and are usually detected incidentally during an abdominal ultrasound, performed for other reasons. [4]

The routine imaging features of this tumor may mimic a malignant neoplasm but the presence of fibrous component often gives a characteristic MRI appearance of low signal intensity on T2W images which helps differentiate it from malignant tumors. [5-7]

The complications due to these ovarian tumors are rare, but may include rupture of the cystic portion of the tumor within the abdomen, or torsion of the affected ovary. The treatment for Benign Serous Cystadenofibroma of Ovary is complete surgical removal of the tumor. With prompt and appropriate treatment, the prognosis is generally excellent.

On incidental finding of such tumors on gross examination, a cystadenofibroma may resemble a malignant tumor. A frozen section of such tumors in operating rooms may help in avoiding unnecessary extensive operative procedures.

CONCLUSION

We are presenting this case of Benign Serous Papillary Cystadenofibroma because

of its rarity in the literature of gynaecopathology and also its close differential to malignant neoplasm.

REFERENCES

1. Longacre TA, Blake Gilks C. Surface epithelial stromal tumors of the ovary. In: Goldblum JR, editor. *Gynaecologic Pathology*. 1st edition. Churchill Livingstone Elsevier; 2009. p. p. 393.
2. Young RH. Blaustein's pathology of the female genital tract. In: Kurman RJ, Hedrick Ellenson L, Ronnett BM, editors. 6th edition. New York, NY, USA: Springer; 2011. p. p. 786.
3. Czernobilsky B, Borenstein R, Lancet M. Cystadenofibroma of the ovary. A clinicopathologic study of 34 cases and comparison with serous cystadenoma. *Cancer*. 1974;34:1971-81.
4. Groutz A, Wolman I, Wolf Y, Luxman D, Sagi J, Jaffa AJ, David MP. Cystadenofibroma of the ovary in young women. *Eur J Obstet Gynecol Reprod Biol*. 1994;54:137-9.
5. Cho SM, Byun JY, Rha SE, Jung SE, Park GS, Kim BK, et al. CT and MRI findings of cystadenofibromas of the ovary. *Eur Radiol*. 2004;14:798-804.
6. Jung DC, Kim SH, Kim SH. MR imaging findings of ovarian cystadenofibroma and cystadenocarcinofibroma: clues for differential diagnosis. *Korean J Radiol*. 2006;7:199-204
7. Takeuchi M, Matsuzaki K, Kusaka M, Shimazu H, Yoshida S, Nishitani H, et al. Ovarian cystadenofibromas: Characteristic magnetic resonance findings with pathologic correlation. *J Comput Assist Tomogr*. 2003;27:871-3

How to cite this article: Kumbhar SS, Mane AM, Mayekar PS et.al. Serous papillary cystadenofibroma of ovary: a rare case report. *Int J Health Sci Res*. 2019; 9(10):217-219.
