

Original Research Article

Expression of Vascular Endothelial Growth Factor-A 165 (VEGF-A) in Term Normal Placenta: Immunohistochemical Study

Vanitha¹, Dr. Daksha Dixit², Dr. Adarsh Sanikop³, Dr. R. D. Virupaxi⁴

¹PhD Scholar, ²Professor, ⁴Professor & Head, Department of Anatomy,

³Assistant Professor, Department of Pathology,

Jawaharlal Nehru Medical College, KLE Academy of Higher Education & Research (KAHER), Belagavi, Karnataka, India.

Corresponding Author: Vanitha

ABSTRACT

Introduction: Vascular Endothelial Growth Factor (VEGF) is a potent angiogenic growth factor and acts as a key regulator of vascular development, implicated in the development of both pathological and physiological angiogenesis. In the placenta, it has been identified recently and considered as one of the important angiogenic growth factors in the development of the embryo. We have taken up this study to see the expression of VEGF-A 165 in normal placenta by immunohistochemistry.

Materials and methodology: One hundred central sections of placenta slides were deparaffinized followed by peroxidase block and protein block. After this, the slides were incubated in VEGF mouse monoclonal antibody for 1 hr followed by incubation in Horseradish peroxidase (HRP) for 30 mins and Diaminobenzidine (DAB). Stained sections were observed for VEGF expression in the villi of placental tissues.

Results: Expression of VEGF was observed in syncytiotrophoblast, endothelium of blood vessels and Hofbauer cells of villi of the placenta.

Conclusion: In this study, we studied the expression of VEGF in normal term placenta of 37-41 weeks of gestation. The VEGF expression on syncytiotrophoblast and Hofbauer cells can act on paracrine mode on vessels to modulate angiogenesis, to maintain endothelium and permeability and through autocrine mode to influence trophoblast function during pregnancy.

Key words: Placenta, terminal villi, VEGF.

INTRODUCTION

Vascular endothelial growth factor is an angiogenic growth factor (VEGF), Disulphide-linked homodimeric glycoprotein which was first identified as a vascular permeability factor. Later, in 1989, Napoleone Ferrara and his colleagues at Genentech, isolated and cloned the vascular endothelial growth factor from bovine pituitary follicular cells. It is a potent angiogenic growth factor and acts as a key regulator of vascular development, [1]

implicated in the development of both pathological and physiological angiogenesis. [2] In the placenta, it has been identified recently and considered as one of the important angiogenic growth factors in the development of the embryo. There are different types of VEGF which have been identified, like VEGF-A, PlGF, VEGF-B, VEGF-C, VEGF-D and VEGF-E, [3] but only VEGF-A, PlGF, VEGF-B and VEGF-C have been identified in placenta. [4] VEGF-A is also called as VEGF. [5] There

are different isoforms of VEGF-A like VEGF-A121, VEGF-A145, VEGF-A165, VEGF-A183, VEGF-A189 and VEGF-A 206 having 121, 145, 165, 183, 189 and 206 amino acids. [6] VEGF binds 2 tyrosine kinase receptors, Vascular Endothelial Growth Factor Receptor-1 (VEGFR-1 or Flt-1) [7] and Vascular Endothelial Growth Factor Receptor-2 (VEGFR -2 or KDR) [8] which are present in endothelial cells. In addition, it also binds Neuropilin -1(NRP-1) and Neuropilin-2 (NRP-2). [6] An in-vitro study has shown the role of VEGF in spiral artery remodeling, trophoblast invasion during implantation and also in the reduction of apoptosis, thereby helps in angiogenesis and vasculogenesis. [9] The growth factors which stimulate and maintain vascular growth and function have developmental and clinical significance. There are reports on the expression of VEGF in placenta, but studies showed discrepancies in the expression of VEGF, so we have taken up this study to see the expression of VEGF-A 165 in normal placenta by immunohistochemistry.

MATERIALS AND METHODS

One hundred normal placentae of 37-41 weeks of gestational age were collected, after taking an informed consent. A section of placenta was taken from the center and fixed in neutral buffered formalin for 24 hrs. After fixing the tissue, the tissue was processed for the block preparation. Then it was sectioned into 3µm and transferred onto positively coated slides. For immunostaining, the slide was incubated overnight at 37°C and in the morning it was kept on a hot plate for fixing at 63°C for 1hr. Then the slide was processed for deparaffinization followed by peroxidase block and protein block. After this, the slide was incubated in VEGF mouse monoclonal antibody (Diagnostic Biosystems USA Pleasanton, catalog # PDM165-RUO) for 1hr followed by incubation in HRP (Biocare Medical, USA) for 30 mins and DAB (Biocare Medical, USA). Positive (Kidney tissue) and negative control slides (Reagent

control) were run together with the sample tissue. Stained section was observed for VEGF expression in the villi of placental tissues.

RESULTS

The VEGF-A staining was observed in syncytiotrophoblast, endothelium of blood vessels and hofbauer cells of villi of placenta (Figure 1 & 2). There were no differences in the expression of VEGF in 37-41 weeks of gestation.

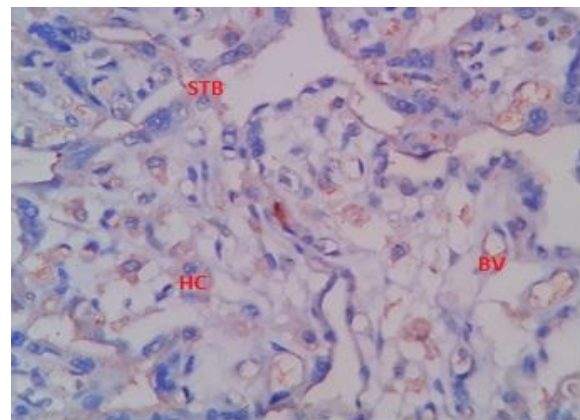


Figure 1: VEGF expression in blood vessels (BV), hofbauer cells (HC) and syncytiotrophoblast (STB) layer of villi of placenta

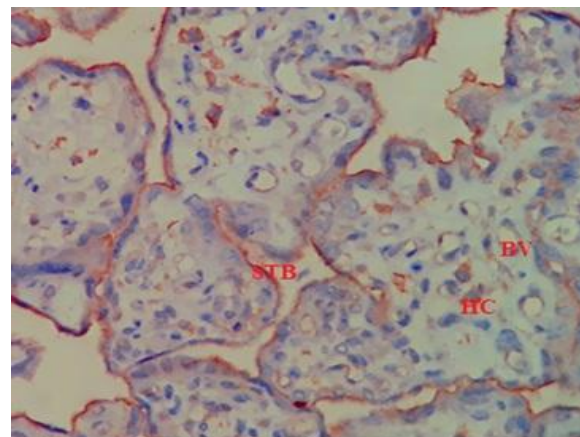


Figure 2: VEGF expression in blood vessels (BV), hofbauer cells (HC), syncytiotrophoblast (STB) layer of villi of placenta

DISCUSSION

Development of vessels in the placenta, as well as in maternal endometrial tissue is required to maintain the pregnancy and fetal growth, which are regulated by the angiogenic growth factors. Alterations in the

expression of these growth factors can affect the development of the fetus. VEGF is considered to be one of the dominant angiogenic growth factors in the development of vessels in the placenta. In this immunohistochemical study, we tried to find expression of VEGF-A in the normal placenta of 37-41 weeks of gestation. The VEGF expression was found in the syncytiotrophoblast layer, endothelial cells of blood vessels and hofbauer cells of villi of placenta. Earlier studies on early and term normal placenta showed, VEGF in hofbauer cells and decidual cells, glandular epithelium and extravillous trophoblast (EVT) in the uterus of the first trimester. In term, VEGF was found in syncytiotrophoblast, EVT and in the extracellular material. Expression of VEGF by hofbauer cells can act on endothelial cells for the capillary formation and vessel permeability throughout gestation and Flt on hofbauer cells may act on autocrine manner to control their function. The expression on EVT, decidual cells and glandular epithelium suggests its role in EVT migration and differentiation. [10] In another study, the expression was observed in syncytiotrophoblast, cytotrophoblast, endothelial cells, EVT, hofbauer cells and diffused staining within the villous in term placenta. More staining was observed in cytotrophoblast than that in syncytiotrophoblast. [11] Vuorela et al observed protein expression in villous blood vessels and less or no staining in the villous stroma and mRNA expression in mesenchymal cells of chorionic plate. Hence the cells of chorionic plate secrete VEGF, that diffuses through the villi and acts on the endothelium of vessels of villi in paracrine mode. [12] In one of in-situ hybridization studies of the placenta of first and third trimester revealed, VEGF mRNA expression on syncytiotrophoblast, cytotrophoblast and hofbauer cells of mesoderm, may be involved in the angiogenesis of fetal blood vessels during placental growth. Expression was also observed in decidua of the first-trimester

uterus, in glandular epithelium and uteroplacental junction adjacent to Nitabuch's stria. In term placenta, the expression of VEGF mRNA was seen in syncytiotrophoblast cells and in hofbauer cells. This study concluded that macrophages are the primary source of VEGF. [13] Our study results are consistent with the mRNA expression of VEGF in syncytiotrophoblast and hofbauer cells, but not with the endothelial cells. The endothelial expression may be due to the presence of receptors of VEGF by which VEGF acts on it. [10] One of the in-vitro studies showed expression of VEGF in cytotrophoblast and syncytiotrophoblast by ribonuclease protection assay (RPA). However, the expression was lower compared to PLGF. Under hypoxic condition, the expression of VEGF was increased in cultured cells. [14] VEGF is important in the development of blood vessels in the placenta and placental tissue. There was a positive correlation between the expression of VEGF and blood vessels /unit area of tissue in the pig. Increased blood vessels at the placental endometrial interface results in an increased nutrient transfer between mother and fetus. [15] One of the study showed increased expression of VEGF in blood vessels of villi of placenta under pathological conditions. [16] In another study, VEGF mRNA was localized to cytotrophoblast, syncytiotrophoblast, stromal cells and in perivascular cells of first, second and third trimester placentae. But in preeclampsia, VEGF was found mainly in syncytiotrophoblast and fibrous stroma. An increased level of VEGF was observed in preeclampsia. In this study, they found a difference in the expression of VEGF in normal and preeclampsia and their results were consistent with mRNA expression. [17] Isolated macrophages from villi have shown expression of VEGF, which may have dual immune and morphogenetic role on the placenta. [18] In this study, we found expression of VEGF in syncytiotrophoblast, blood vessels of the villi and hofbauer cells of the villous stroma of villi of placenta.

The VEGF expression on syncytiotrophoblast and Hofbauer cells can act on paracrine mode on vessels to modulate angiogenesis, to maintain endothelium and permeability and through autocrine mode to influence trophoblast function during pregnancy. [13,14]

CONCLUSION

In this study, we observed the expression of VEGF in syncytiotrophoblast, blood vessels of the villi and Hofbauer cells of villi of normal term placenta of 37-41 weeks of gestation. This will help to understand its expression and function in normal pregnancy.

REFERENCES

1. Ferrara N. History of Discovery: Vascular Endothelial Growth Factor. *Arterioscler Thromb Vasc Biol.* 2009;29:1-3.
2. Ahmed A, Dunk C, Ahmad S, Khaliq A. Regulation of Placental Vascular Endothelial growth factor (VEGF) And Placental growth Factor (PLGF) and Soluble Flt-1 by Oxgen-A Review. *Placenta.*2000;21:16-24.
3. Ferrara N. VEGF: An update on biological and therapeutic aspects. *Curr Opin Biotechnol.* 2000; 11: 617-624.
4. Regnault TRH, Galan HL, Parker TA, Anthony RV. Placental development in normal and compromised pregnancies-A review. *Placenta.* 2002;23(16):S119-S129.
5. Mattei MG, Borg JP, Rosnet O, Marme D, Birnbaum D. Assignment of vascular endothelial growth factor (VEGF) and placenta growth factor (PLGF) genes to human chromosome 6p12-p21 and 14q24-q31 regions, respectively. *Genomics.* 1996;32: 168–169.
6. Andraweera PH, Dekker GA, Roberts CT. The vascular endothelial growth factor family in adverse pregnancy outcomes. *Hum Reprod Update.* 2012; 18(4): 436–457.
7. Terman BI, Dougher-Vermazen M, Carrion ME, Dimitrov D, Armellino DC, Gospodarowicz D et al. Identification of the KDR tyrosine kinase as a receptor for vascular endothelial cell growth factor. *Biochem Biophys Res Commun.* 1992; 187: 1579–1586.
8. Rodeck Charles H and Whittle Martin J. *Fetal Medicine: Basic science & Clinical practice- Development of placenta and its circulation.* 2nd edtn. Churchill Livingstone, Elsevier. London.69-88,104.
9. Zhou Y, Bellingard Valerie, Feng Kui-Tzu, McMaster Michael, Fisher Susan J. Human cytotrophoblasts promote endothelial survival and vascular remodeling through secretion of Ang2, PlGF, and VEGF-C. *Dev Biol.* 2003; 263: 114–125.
10. Cooper JC, Sharkey AM, McLaren J, Charnock-Jones DS, Smith SK. Localization of vascular endothelial growth factor and its receptor, flt in human placenta and decidua by immunohistochemistry. *J Reprod Fertil.* 1995; 105: 205-213.
11. Clark DE, Smith SK, Sharkey A M, Charnock- Jones DS. Localization of VEGF and expression of its receptors flt and KDR in human placenta throughout pregnancy. *Hum Reprod.* 1996;11(5): 1090-1098.
12. Vuorela Piia, Hatva Erika, Lymboussaki Athina, Kaipainen Arja, Joukov Vladimir, Persico Maria Graziella et al. Expression of Vascular Endothelial Growth factor and Placenta Growth Factor in Human placenta. *Biol Reprod.* 1997; 56: 489-494.
13. Sharkey AM, Charnock-Jones DS, Babcock CA, Brown KD, Smith SK. Expression of mRNA for vascular endothelial growth factor in human placenta. *J Reprod Fertil.* 1999; 99: 609-615.
14. Shore VH, Wang TH, Wang CL, Torry RJ, Caudle MR, Torry DS. Vascular Endothelial Growth Factor, Placenta Growth Factor and Their Receptors in

- Isolated Human Trophoblast. Placenta.1997; 18: 657-665.
15. Vonnahme AK, Wilson E Matthew, Ford Stephen P. Relationship Between Placental Vascular Endothelial Growth Factor Expression and Placental/Endometrial Vascularity in the Pig. Biol Reprod. 2001; 64: 1821–1825.
 16. Kumazaki K, Nakayama M, Suehara N, Wada Y. Expression of Vascular Endothelial Growth Factor, Placental Growth Factor, and Their Receptors Flt-1 and KDR in Human Placenta Under Pathologic Conditions. Hum Pathol. 2002;33(11).1069-1077.
 17. Geva E, Ginzinger DG, Zaloudek CJ, Moore DH, Byrne A, Jaffe RB. Human Placental Vascular Development: Vasculogenic and Angiogenic (Branching and Nonbranching) Transformation Is Regulated by Vascular Endothelial Growth Factor-A, Angiopoietin-1, and Angiopoietin-2. J Clin EndocrinolMetab. 2002; 87(9): 4213–4224
 18. PavlovOV, NiauriDA, SelutinAV, Selkov SA. Coordinated expression of TNF α - and VEGF-mediated signaling components by placental macrophages in early and late pregnancy. Placenta.2016;42:28-36.

How to cite this article: Vanitha, Dixit D, Sanikop A et.al. Expression of Vascular Endothelial Growth factor-A 165 (VEGF-A) in term normal Placenta: Immunohistochemical study. Int J Health Sci Res. 2018; 8(8):110-114.
