

Studying With Multidetector Computed Tomography Angiography Techniques of Aortic Arch Branching Variation

Gunes Bolatli¹, Mahinur Ulusoy², Mustafa Koplay³, İsmail Zararsız⁴

¹PhD Student, Department of Anatomy, Beykent University, Medical Faculty, İstanbul, Turkey

²Assist. Prof. Dr. Department of Anatomy, Beykent University, Medical Faculty, İstanbul, Turkey

³Prof. Dr. Department of Radiology, Selcuk University, Medical Faculty, Konya, Turkey

⁴Prof. Dr. Department of Anatomy, Girne American University, Medical Faculty, Kıbrıs, Turkey

Corresponding Author: Gunes Bolatli

ABSTRACT

In this study, Multidetector Computed Tomography (MDCT) angiography technique with aortic arch branching variation types, frequency and clinical significance were investigated. MDCT examinations carried out 83 men, 97 women were evaluated 180 patients. Arcus aorta types and frequency of the variation was detected.

In our study, the aortic arch showing a normal branching pattern was accepted as Type 1. Other than that, a variation was detected in 345 of the patients (32.24%). These variations were divided into the types from 1 to 7 in an array ranked from the most frequent to the least frequent. Unlike previous studies, two new variation types were defined.

Clinically important aortic arch branching variation can be detected by CT angiography technique. A good knowledge of these variations is important and instructive in terms of common invasive and surgical interventions.

Keywords: Aortic arch, Variations, Anatomy, MDCT.

INTRODUCTION

The arch of aorta ascends in front of the right pulmonary artery and tracheal bifurcation. It ends on the left of the body of fourth thoracic vertebrae. Three large branches originate from the arch of aorta. The first branch, brachiocephalic trunk, ascends behind the right sternoclavicular joint. It gives off the right common carotid artery and right subclavian artery branches here. The second branch originated, left common carotid artery, enters the neck region behind the left sternoclavicular joint. The third branch, left subclavian artery, arises from the distal portion of the aortic arch and enters the neck region behind the left sternoclavicular joint. ^[1]

In the literature reviews, variations of these branches arising from the aortic arch are commonly seen. Arterial variations in the aortic arch are of importance during cardiovascular surgical interventions. They may lead to symptoms as a result of compression caused by variational arteries. ^[2,3] Multidetector computed tomography (MDCT) is a non-invasive method used for visualising arteries. In this study, we aimed to determine and categorize the variations in the pattern of the arch of aorta on multidetector computed tomography images. The recognition of variations during the interventions performed in this region will increase the success of operation by

reducing complications. It will help in diagnosing the neck pathologies.

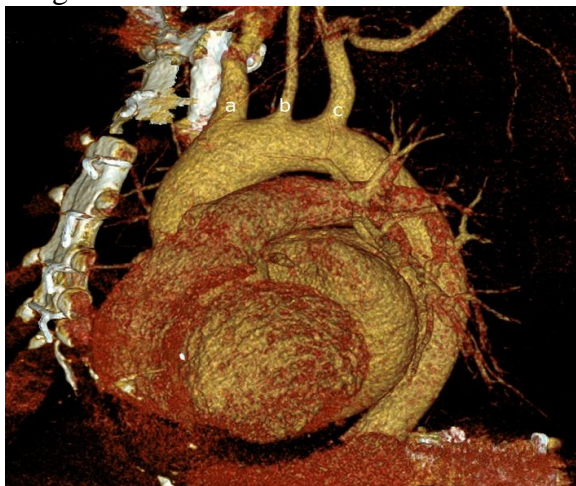MATERIALS AND METHODS

The tomography images of 1070 patients underwent MDCT imaging at Selcuk University Faculty of Medicine, Department of Radiology and found to have no pathology were examined. The examination was performed using a 256-slice dual-source CT (Siemens, Somatom, Definition Flash, Germany) with a routine slice thickness of 3 mm and after reconstruction, with an interslice distance of 1 mm and a slice thickness of 1 mm. The incidence and types of the arch of aorta variations were determined by multiplanar reconstruction (MPR), maximum intensity projection (MIP) and 3D volume rendering images.

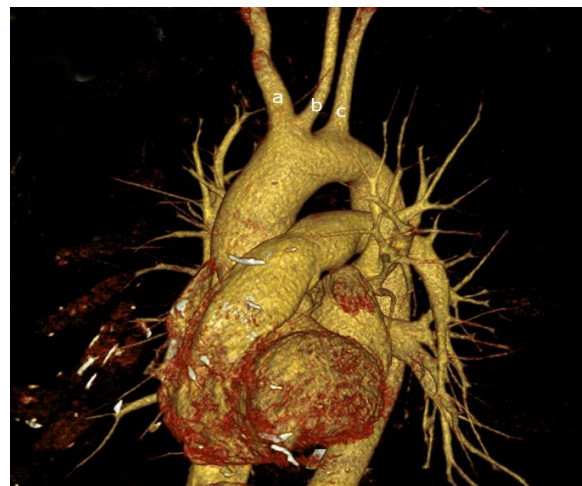RESULT

In our study, the aortic arch showing a normal branching pattern was accepted as Type 1. Other than that, a variation was detected in 345 of the patients (32.24%). These variations were divided into the types from 1 to 7 in an array ranked from the most frequent to the least frequent. Unlike previous studies, two new variation types were defined.

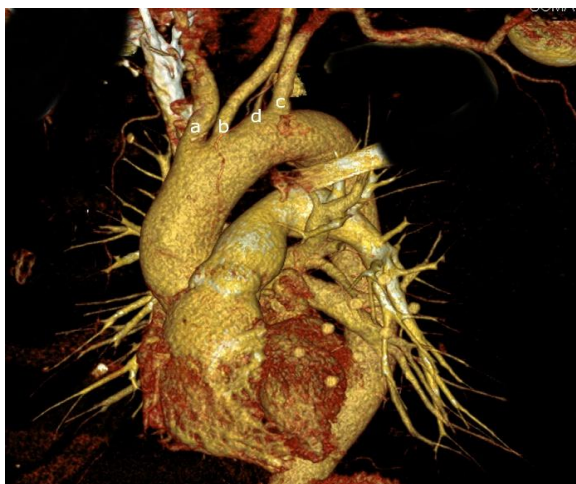
In an anatomically normal case, the brachiocephalic trunk, left common carotid artery and left subclavian artery arise from the arch of aorta from the right to the left. In this study, a normal branching pattern was termed as Type 1 and was seen in 721 patients (67.38%) (Figure 1).



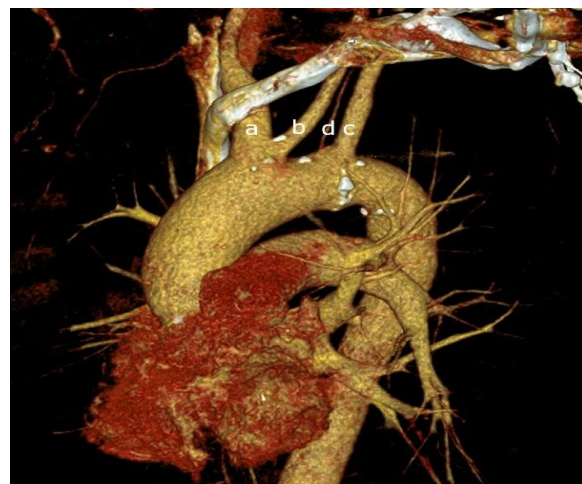a. Type 1



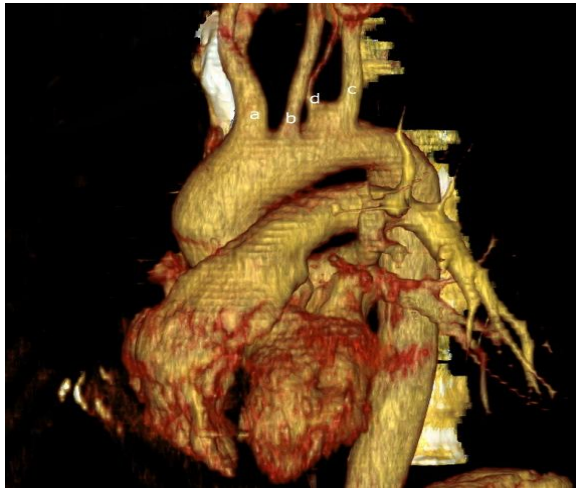
b. Type 2



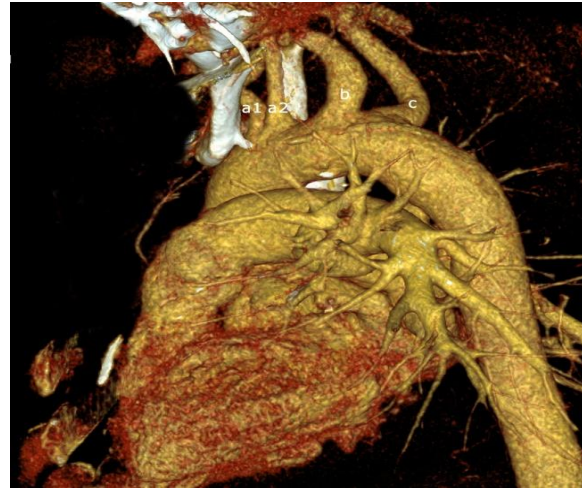c. Type 3



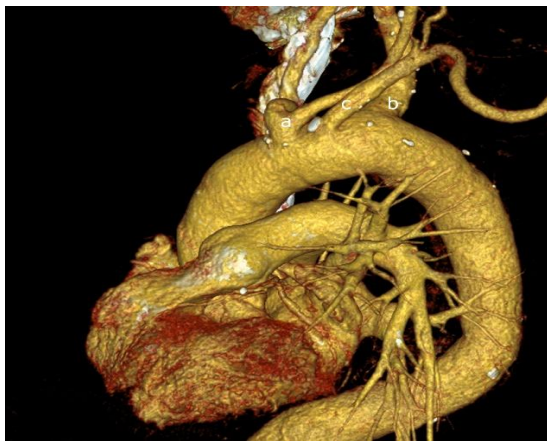d. Type 4



e. Type 5



f. Type 6



g. Type 7

Figure 1: Types of the aortic arch [a. Brachiocephalic trunk b. Left common carotid artery c. Left subclavian artery d. Vertebral artery a1. Right subclavian artery a2. Right common carotid artery]

When we sort the branches arising from the arch of aorta from the right to the left, in the variation type in which only two branches arise, the first branch is the brachiocephalic trunk and left common carotid artery in the form of a single root and the second branch is the left subclavian artery. This type, determined as Type 2, is the most common (25.6%) variation (Figure 1).

In the variation type of Type 3, four branches are separated from the aortic arch. When we sort the branches from the right to the left, the 1st branch is the brachiocephalic trunk, the 2nd branch is the left common carotid artery, the 3rd branch is the vertebral artery and the 4th branch is the left subclavian artery. The incidence of this type was found to be 4.67% (Figure 1).

Another variation of the arch of aorta when the branches are sorted from the right to the left is the type in which brachiocephalic trunk and left common carotid artery arising from the single root is the 1st branch, the vertebral artery is the 2nd branch, and left subclavian artery is the 3rd branch. This type was termed as Type 4 and the incidence was found to be 1.37% (Figure 1).

In Type 5 variation, the first branch arising from the aortic arch is the brachiocephalic trunk, the second branch is the left common carotid artery, the third branch is the vertebral artery along with left subclavian artery arising from the same root. The incidence of this type of variation was found to be 0.37% (Figure 1).

In the Type 6 variation, in which four branches arising from the arch of aorta are seen, the brachiocephalic trunk do not form and the right subclavian artery and right common carotid artery arise from the aortic arch. The third branch is the left common carotid artery and the fourth branch is the left subclavian artery. The incidence of this type of variation was found to be 0.37% (Figure 1).

In Type 7 variation, the brachiocephalic trunk arises from the aortic arch as the first branch, but left subclavian artery arises as the second branch and the common carotid artery is arises as the third branch and are replaced by each other. The incidence of this type was found to be 0.28% (Figure 1).

DISCUSSION

The aortic arc and its branches form during the 4-8th weeks of intrauterine life. Variations may occur in the arc of aorta during this developmental course. [4,5]

In our study that we conducted on the images of 1070 patients, we found a variation in the aortic arc with a rate of 32.24%. According to this rate, it is not a rare condition to see branching variations of the aortic arc. When we look at the literature, the incidence rate of the classic type, we called type 1, varies from 67.3% to 73.3%. [2-16] In our study, the incidence rate of Type 1 is 67.38% (Table 1). The incidence of variation in other studies has been found to be less than our study. We think that this variability may be caused by the differences among the races.

In the literature, the most common variation type of the arc of aorta has been indicated as Type 2. The rate of incidence varies between 8% and 21.5% (2-16) (Table 1). In our study, this rate was found to be 25.6% which was a higher rate than other studies in the literature. It is very important to recognize these variations during intravenous interventions. The recognition of these variations while selecting a catheter during catheterization procedure shortens the procedure time and increases the

success. [17] This type is also known to cause clinical symptoms such as cough and dyspnea. [18]

The incidence rate of the vertebral artery originating from the arc of aorta, evaluated as Type 3, is 1.6% to 8.3% in the literature [2-16] (Table 1). In our study, the incidence of this type was found to be 4.67%. We know that the recognition of this variation during neurovascular interventions may reduce the complications of the procedure. [19] Moreover, non-invasive interventions such as CT and MR may suggest that the vertebral artery is obstructive. [20]

It has been seen that Type 4 was described in five studies in the literature. The incidence rate in these studies ranged from 0.2% to 1.1% [4,5,10,11,15] In our study, the incidence rate of Type 4 was found to be 1.31%.

No study on Type 5 and Type 7 was found in the literature reviews. The incidence rates of these types in our study are also very low. The incidence of Type 5 was found to be 0.37% and the incidence of Type 7 was found to be 0.28%. A study on Type 6 was found in the literature. The incidence rate in this study was 0.16%. [8] In our study, the incidence rate was seen to be 0.37%.

Table 1: Incidence of the types of aortic arch branches variations

	Type1	Type2	Type3	Type4	Type6	Type7	Type8
Bolatli et al.	67.38%	25.6%	4.67%	1.318%	0.37%	0.37%	0.28%
Aisling et al.	79.2%	12.5%	8.3%				
Shin et al.	84%	8%	8%				
Alsaif et al.	75%						
Nayak et al.	91.4%	4.8%	1.6%				
Natsis et al.	%83	15%	0.79%		0.16%		
Bhatia et al.			7.41%				
Karacan et al.	79.2%	14.1%	4.1%	1.2%			
Paraskevas et al.				0.2%			
Ogengo et al.	67.3%	32.7%	3.5%				
Jakakanini et al.	74%	20%	6%				
Patil et al.	77.3%	14.6%	8%				
Ergun et al.	73.3%	21.5%	2.6%				
Muller et al.		8%	4.2%	1.1%			
Çelikyay et al.	74.4%	21.1%	2.9%	0.4%			
Vucurevic et al.	74.72%	15.6%	3.63%				

We think that this study, in which we examined the branching variations of the aortic arc, would provide very useful data to anatomists, radiologists and surgeons.

CONCLUSION

Although aortic variations are usually asymptomatic, it is important to know these variations during neck and

thoracic surgery. In addition, these variations may be accompanied by other congenital abnormalities.

REFERENCES

1. M.Gilroy A. Anatomy: An Essential Textbook 2013. 48-9 p.
2. Celikyay ZRY, Koner AE, Celikyay F, Deniz C, Acu B, Firat MM. Frequency and imaging findings of variations in human aortic arch anatomy based on multidetector computed tomography data. Clin Imag. 2013;37(6): 1011-9.
3. Muller M, Schmitz BL, Pauls S, Schick M, Rohrer S, Kapapa T, et al. Variations of the aortic arch - a study on the most common branching patterns. Acta Radiol. 2011;52(7): 738-42.
4. O'Malley AM, El Kininy WH, Debebe H, Burukan AB, Davy SW. A cadaveric study of aortic arch variation in an Irish population. Ir J Med Sci. 2017.
5. Shin IY, Chung YG, Shin WH, Im SB, Hwang SC, Kim BT. A morphometric study on cadaveric aortic arch and its major branches in 25 korean adults: the perspective of endovascular surgery. J Korean Neurosurg Soc. 2008;44(2):78-83.
6. Haifa A. Alsaif WSR. An Anatomical Study of the Aortic Arch Variations JKAU: Med Sc. 2010;27:37-54.
7. Soubhagya R. Nayak MMP, Latha V. Prabhu, Sujatha D'Costa, Prakash Shetty. Anatomical organization of aortic arch variations in the India: embryological basis and review. J Vasc Bras 2006;5(2):95-100.
8. Natsis KI, Tsitouridis IA, Didagelos MV, Fillipidis AA, Vlasis KG, Tsikaras PD. Anatomical variations in the branches of the human aortic arch in 633 angiographies: clinical significance and literature review. Surg Radiol Anat. 2009;31(5):319-23.
9. Bhatia K, Ghabriel MN, Henneberg M. Anatomical variations in the branches of the human aortic arch: a recent study of a South Australian population. Folia Morphol (Warsz). 2005;64(3):217-23.
10. Karacan A, Turkvaten A, Karacan K. Anatomical variations of aortic arch branching: evaluation with computed tomographic angiography. Cardiol Young. 2014;24(3):485-93.
11. Paraskevas G, Agios P, Stavrakas M, Stoltidou A, Tzaveas A. Left common carotid artery arising from the brachiocephalic trunk: a case report. Cases J. 2008;1(1):83.
12. Ogeng'o J, Olabu, BO., Gatonga, PM. and Munguti, JK. Branching pattern of aortic arch in a Kenyan population. J Morphol Sci. 2010;27(2):51-5.
13. Jakanani GC, Adair W. Frequency of variations in aortic arch anatomy depicted on multidetector CT. Clin Radiol. 2010;65(6): 481-7.
14. Patil ST, Meshram MM, Kamdi NY, Kasote AP, Parchand MP. Study on branching pattern of aortic arch in Indian. Anat Cell Biol. 2012;45(3):203-6.
15. Ergun O, Tatar IG, Birgi E, Durmaz HA, Akcalar S, Kurt A, et al. [Angiographic evaluation of branching pattern and anatomy of the aortic arch]. Turk Kardiyol Dern Ars. 2015;43(3):219-26.
16. Vucurevic G, Marinkovic S, Puskas L, Kovacevic I, Tanaskovic S, Radak D, et al. Anatomy and radiology of the variations of aortic arch branches in 1,266 patients. Folia Morphol (Warsz). 2013;72(2):113-22.
17. Shaw JA, Gravereaux EC, Eisenhauer AC. Carotid stenting in the bovine arch. Catheter Cardio Inte. 2003;60(4):566-9.
18. Karkoulas KP, Efremidis GK, Tsiamita MS, Trakada GP, Prodromakis EN, Nousi ED, et al. Abnormal origin of the left common carotid artery by innominate artery: a case of enlargement mediastinum. Monaldi Arch Chest Dis. 2003;59(3):222-3.
19. Nizankowski C, Rajchel Z, Ziolkowski M. Abnormal origin of arteries from the aortic arch in man. Folia Morphol (Warsz). 1975;34(2):109-16.
20. Goray VB, Joshi AR, Garg A, Merchant S, Yadav B, Maheshwari P. Aortic arch variation: A unique case with anomalous origin of both vertebral arteries as additional branches of the aortic arch distal to left subclavian artery. Am J Neuroradiol. 2005;26(1):93-5.

How to cite this article: Bolatli G, Ulusoy M, Koplay M et al. Studying with multidetector computed tomography angiography techniques of aortic arch branching variation. Int J Health Sci Res. 2018; 8(7):63-67.
