

Case Report

Hemangiomas Liver

Dr. B. Ananda Rama Rao¹, Dr. Mohd Raheemuddinkhan², Dr. Pavan Kumar²

¹Professor, Surgery, SVS Medical College Mahabubnagar TS 509002

²Resident in Surgery, SVS Medical College Mahabubnagar TS 509002

Corresponding Author: Dr. B. Ananda Rama Rao

ABSTRACT

Here we present a case of 40-year-old female complaining of localised pain in right hypochondrium and epigastrium since 1 month. On clinical examination she was found to have lump in the epigastrium, firm in consistency, non-tender and continuous with liver. CT showed huge hemangioma in the right lobe, and a smaller one on left lobe of liver. Resection was done. Patient had uneventful recovery. Case is presented for rarity of multiple hemangiomas in liver

Key Words: Hemangioma Liver Hepatoma Benign tumours of liver

INTRODUCTION

Hemangioma is a benign tumor originating from hepatic blood vessels. It is the most common liver tumor, found in up to 20% of autopsy series. ⁽¹⁾ It occurs in all ages and is observed slightly more often in women than in men. ⁽²⁾ Most hemangiomas are well-defined solitary lesions and they vary in size from a few millimeters to more than 20 cm in diameter, with most measuring less than 5 cms and most of them are asymptomatic and rarely require intervention. Indications for treatment include rupture and hemorrhage, abdominal symptoms because of a mass effect, etc. Treatment options include hepatic arterial embolization and resection. The resection of large hemangiomas, located centrally in the liver hilum may be technically very demanding and sometimes impossible.

They consist of vascular channels lined by a single endothelial layer, supported by fibrous tissue. Hemangiomas tend to occur more frequently in women than men. They may be single or multiple and may vary in size from a few millimeters to 10 cm or more. The aetiology is unknown

but puberty, pregnancy and estrogens may cause an increase in tumour size. Most hemangiomas are well-defined solitary lesions and in about 20-30% of cases, there may be multiple lesions. ⁽³⁾ They are usually located beneath the liver capsule and are clearly differentiated from the parenchyma by a pseudocapsule. Hemangioma is a benign lesion, and malignant transformation is extremely rare. Most hemangiomas are asymptomatic and, as a rule, are discovered incidentally during a sonographic examination of the abdomen. Depending on their size and subcapsular location they may cause a vague discomfort in the right upper abdomen. Having reached a particular size, however, they may cause upper abdominal pain, nausea and anorexia. Acute pain results from bleeding in the tumour, thrombosis or rupture. A large hemangioma may also cause abdominal symptoms because of a mass effect leading to compression of bile ducts with consequent cholestasis. Occasionally giant hemangiomas may bleed, either into the liver, or into the peritoneal cavity. ⁽⁴⁾ Since the majority of hemangiomas are clinically

silent, they most commonly present as an incidental finding on an ultrasound done for unrelated purposes. The diagnosis of hemangioma can almost always be made radiologically. Different modalities of imaging, i.e., contrast ultrasound, CT scanning or MRI are quite sensitive for the detection of hemangioma. (5,6)

Most hemangiomas do not need treatment. Indications for treatment include rupture and hemorrhage, abdominal symptoms because of a mass effect, Kasabach-Merritt syndrome and a diagnostic inconsistency that can otherwise not be solved. A ruptured hemangioma requires immediate surgical intervention; it is often necessary to ligate the hepatic artery. Enucleation is sometimes possible. (7) Resection or arterial embolization is recommended for very large and symptomatic hemangiomas. The overall prognosis remains good. (8)

CASE REPORT

A 40 year old female presented with pain in the right hypochondrium and epigastrium

since last one month. The pain was dragging type and continuous in nature. There was no history of trauma, fever and weight loss. On examination, there was a palpable lump in the right hypochondrium and epigastrium extending below the costal margin and moving with respiration (fig-1). It was non-tender firm in consistency and continuous with liver. There was also a separate lump in the hypogastrium since last one year.

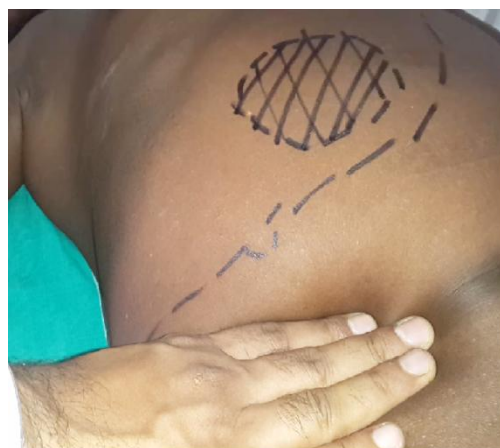

Fig-1, Enlarged liver & mass

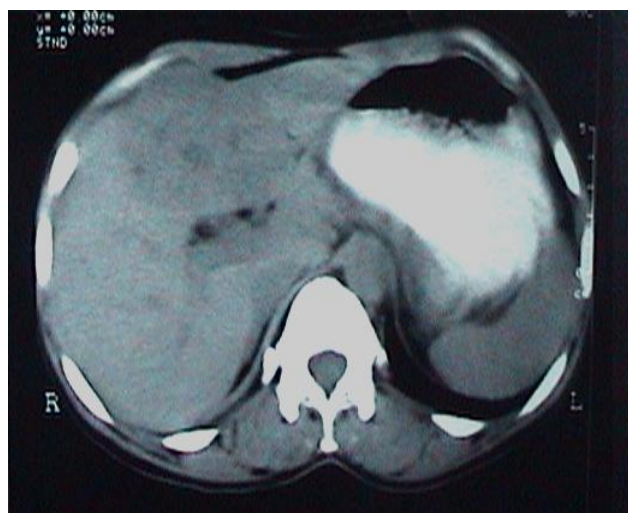

Fig-2(a) CT Hemangioma

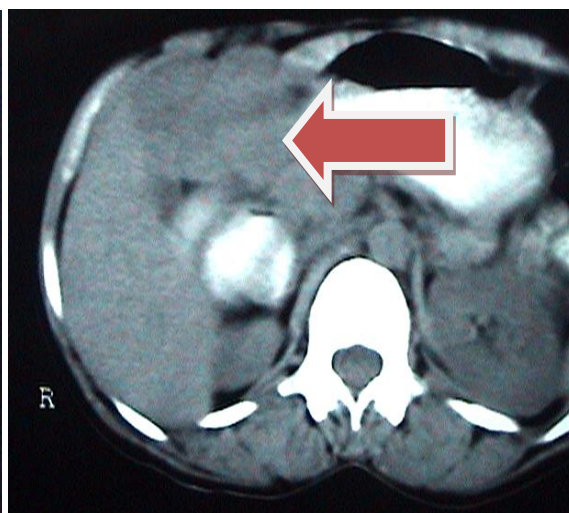


Fig- 2(b) CT Hemangioma

The patient took medical treatment elsewhere earlier where aspiration of the lesion yielded blood. On ultra sound evaluation, there was a hyperechoic space occupying lesion in the right lobe of liver of about 7 X 5 cm. A presumptive diagnosis of

hepatoma or hemangioma was made. On CT scan, there was a 6 X 6 cm hemangioma in the right lobe of the liver as pointed in figure 2(b), large fundal intra mural fibroid and bilateral small renal calculi. Rest of the investigations were within normal limits.

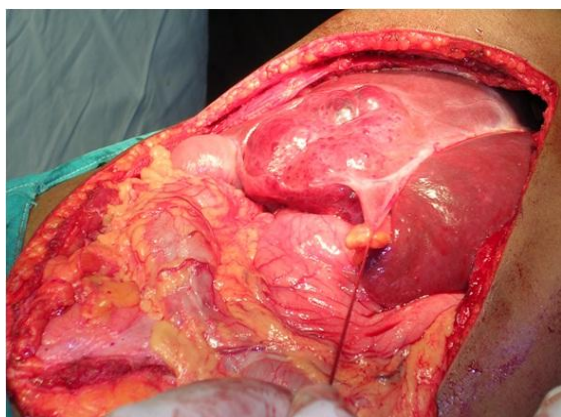


Fig-3(a) Hemangioma arising from Right lobe inferior surface

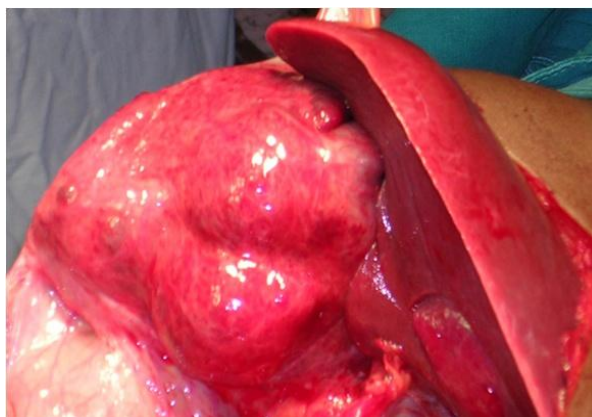

Fig-3(b)

After initial pre-operative work up, she was taken up for surgery. Roof-top sub-costal incision was taken and abdomen adequately exposed. There was a large hemangioma 18x20 cms in the right lobe of liver (fig-3a), subcapsular in location (fig-3b) and lateral to the falciform ligament. The peripheries were carefully cleared off the liver parenchyma with the harmonic scalpel and feeding vessels were ligated. The mass was removed in-toto. There was

also a small lesion 5x6 cms at the inferior surface of left lobe corresponding to segment III of liver (fig-4). Enucleation was done with harmonic scalpel and raw area approximated. The use of harmonic scalpel helped in en-masse removal of lesions in toto and acquiring relatively bloodless operative field (fig-5). The patient recovered subsequently and was discharged in a stable condition.

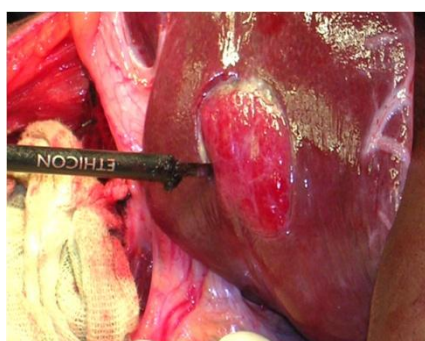


Fig -4 Hemangioma in Left lobe

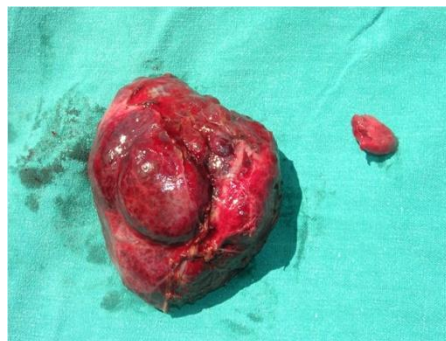

Fig-5 Resected specimen

DISCUSSION

F.Th. Frerichs described a hemangioma for the first time in 1861. Hemangiomas of the liver are the most common benign tumors containing clusters of blood-filled cavities, lined by endothelial cells, fed by the hepatic artery. (1,9) The arrangement and size of blood vessels is highly irregular and haphazard. They are mesenchymal in origin and usually solitary. There may be multiple lesions in about 20-30 % of the cases. (3,10)

The incidence of liver hemangiomas ranges from 0.4% to 20% of total

population, while at autopsy 0.4% to 7.3% (11) with a consensus of incidence being above 7 % by most authors. They have been reported in all ages with some of them being prenatally detected in a growing fetus, (12) though the frequency is higher among adults. Women are affected more commonly than men with a reported 4.5:1 to 5:1 ratio of female to male cases. The size varies from few millimeters to several centimeters. the majority of them measure below 3 cm in size and are called capillary hemangiomas while those between the range of 3 to 10 centimeters as medium hemangiomas and

those above 10 centimeters are termed giant hemangiomas or cavernous hemangiomas. There are reports of size about 40 cm being recorded in literature. ⁽¹³⁾

The aetiology of hemangiomas largely remains unclear. Several pharmacologic agents have been postulated to promote tumor growth. Steroid therapy, estrogen therapy, and pregnancy can increase the size of an already existing hemangioma. ⁽¹⁴⁾ Haemangiomas are usually asymptomatic and are discovered incidentally most of the times. However, having reached a particular size, they may cause symptoms like upper abdominal pain, nausea and loss of appetite. Physical examination may reveal hepatomegaly and very rarely a palpable mass.

They are usually diagnosed incidentally on imaging studies performed as routine examinations or for other reasons. Ultrasonography shows a hyperechoic structure with smooth boundaries and posterior acoustic enhancement. Sensitivity is about 80%. ⁽¹⁵⁾ Contrast-enhanced ultrasound is a good tool for a more specific diagnosis than conventional Ultrasound.

Computer tomography shows a hypodense tumour. After intravenous bolus contrast-medium injection, enhancement increases in a peripheral-central direction followed by a focal globular contrast and subsequently a rapid reduction of the contrast-rich zone (“iris diaphragm phenomenon”) with 90% sensitivity

MRI displays a low-signal T1 time and pronounced hyper intensity in the T2-weighted picture with well-defined margins, which means that even haemangiomas smaller than 1.0 cm can be detected. The “cotton wool sign” is followed by the “light bulb sign”. The heterogeneous structure points to thrombosis, fibrosis, etc. Both the specificity and sensitivity of MRI is 85-95%. ⁽¹⁶⁾

Tc-99m RBC scintigraphy is a noninvasive method, which provides the most specific diagnosis of hepatic hemangioma. The characteristic, diagnostic presentation on Tc-99 labeled RBC images

is perfusion/ blood pool mismatch: decreased perfusion on early dynamic images and a gradual increase in activity on blood pool images over time. Sensitivity is strongly size-dependent ranging from 17-20 % for the lesions less than one cm in size to almost 100% for those larger than two cm.

Other diagnostic modalities include angiography and explorative laparoscopy. Percutaneous fine needle biopsy is contraindicated because of risk of bleeding. The differential diagnosis of a hepatic hemangioma includes primary malignant liver tumors and hyper vascular metastases. The main complications of hemangiomas in liver include necrosis, thrombin, sclerosis or calcification. Blunt abdominal trauma increases the risk of rupture, which can also occur spontaneously. No malignant transformation has been reported.

Treatment is not warranted in most of the cases as they are asymptomatic. As hemangiomas grow during pregnancy or estrogen treatment, regular follow up by sonographic examinations in women receiving hormone therapy is advocated. Indications for surgery are rapid growth in size, pain despite analgesics or both. The absolute indications for surgery include dimensions, localization or risk of intra tumoral thrombosis, rupture or other complications. Surgical management includes segmental resections, lobectomy or enucleation of the hemangioma, by open surgery or laparoscopy. ⁽¹⁷⁾ Right or left hepatectomy is indicated for large masses that occupy the entire lobe. ⁽¹⁸⁾ Recurrence is rare after surgery. ⁽¹⁹⁾

Apart from surgical modalities, there are other options available to treat symptomatic Hemangiomas, such as arterial embolization or radiofrequency ablation. Orthotopic liver transplantation is indicated for large or diffuse bilateral lesions. Prognosis remains favorable in majority of the cases.

CONCLUSION

Hemangiomas of liver, even though most common, are largely asymptomatic.

Surgery is warranted only in a few selected cases. Enucleation of tumour with harmonic scalpel is preferred method as it facilitates complete removal as well as provides bloodless field of surgery.

REFERENCES

1. Karhunen PJ. (1986) Benign hepatic tumours and tumour like conditions in men. *J Clin Pathol.* 39:183–8.
2. Gandolfi L, Leo P, Solmi L, et al (1991) Natural history of hepatic haemangiomas: clinical and ultrasound study. *Gut* 32: 677–80.
3. Langner C., Thonhofer R., et al (2001): Diffuse hemangiomatosis of the liver and spleen in an adult. *Pathologe*;22:424-428.
4. Shimoji K, Shiraishi R, et al. (2004) Spontaneous subacute intratumoral hemorrhage of hepatic cavernous hemangioma. *Abdom Imaging*.29:443–5.
5. KimTK, JangHJ, WilsonSR. (2006) Benign liver masses: imaging with micro bubble contrast agents. *Ultrasound Q.* 22:31–9.
6. Peterson MS, Murakami T, Baron RL. (1998) MR imaging patterns of gadolinium retention within liver neoplasms. *Abdom Imaging*.23:592–9.
7. Gedaly, R., Pomposelli, J.J., et al: (1999) Cavernous hemangioma of the liver Anatomic resection vs. enucleation. *Arch. Surg.*; 134: 407-411
8. Yoon, S.S., Charny, C.K., et al: (2003) Diagnosis, management, and outcomes of 115 patients with hepatic hemangioma. *J. Amer. Surg.*; 197: 392-402.
9. Dickie B, Dasgupta R, Nair R, et al.(2009) Spectrum of hepatic hemangiomas: management and outcome. *J Pediatr Surg.* Jan. 44(1):125-33
10. <http://www.mayoclinic.org/diseases-conditions/liver-hemangioma/con-20034197>
11. <http://emedicine.medscape.com/article/177106>
12. Dong KR, Zheng S, Xiao X. (2009) Conservative management of neonatal hepatic hemangioma: a report from one institute. *Pediatr Surg Int.* Jun. 25(6):493-8
13. Koszka AJ, Ferreira FG, de Aquino CG, et al.(2010) Resection of a rapid-growing 40-cm giant liver hemangioma. *World Journal of Hepatology*.;2(7):292–294. .
14. Giannitrapani L, Soresi M, La Spada E, et al. (2006) Sex hormones and risk of liver tumor. *Ann N Y Acad Sci.* Nov. 1089:228-36
15. Quinn, S.F., Benjamin, G.G.(1992): Hepatic cavernous hemangiomas: simple diagnostic sign with dynamic bolus CT. *Radiology*; 182: 545-548
16. Yu, J.S., Kim, M.J., et al (1998): Hepatic cavernous hemangioma: Sonographic patterns and speed of contrast enhancement on multiphase dynamic MR imaging. *Amer. J. Roentgenol.* 171: 1021-1025
17. Seymour I, Schwartz MD, Husser CW.(1987) Cavernous Hemangioma of the Liver. *Ann. Surg*;205,5:456–463
18. Trastek VF, van Heerden JA, et al. (1984) Cavernous hemangiomas of the liver: resect or observe? *Am J Surg*;145:49–53
19. Jackson NR, Hauch A, et al. (2015) The Safety and Efficacy of Approaches to Liver Resection: A Meta-Analysis. *JSLs: Journal of the Society of Laparo endoscopic Surgeons*; 19(1):e2014.00186.

How to cite this article: Rao BAR, Raheemuddinkhan M, Kumar P. Hemangiomas liver. *Int J Health Sci Res.* 2018; 8(7):380-384.
