

Case Report

# Use of Hair Mount as an Aid to the Diagnosis of Griscelli Syndrome

Dr. Shantanu Roy, Dr. S. N. Pore, Dr. A.R. Joshi, Dr. R.S. Bindu

Department of Pathology, GMC Aurangabad, Maharashtra, India

Corresponding Author: Dr. S. N. Pore

## ABSTRACT

Griscelli syndrome (GS) is a rare autosomal recessive disorder caused by mutation in the *MYO5A* (GS), *RAB27A* (GS2) or *MLPH* (GS3) genes, characterized by generalized hypopigmentation of skin and hair. We present a case report of 1 year old female child presented with silver hair and infections. Microscopic examination of patient's hair shaft was used in diagnosis of Griscelli syndrome which showed hypopigmented areas. Thus, initial diagnosis can be made by using microscopic features, confirmation remains DNA analysis. Prognosis remains poor with fatal outcome if child remains untreated by Haematopoietic stem cell transplantation by the age of 5 years.

**Key words:** Griscelli syndrome, *RAB27A*, Immunodeficiency, Albinism, Hemophagocytic lymphohistiocytosis

## INTRODUCTION

Griscelli syndrome (GS, MIM 214450 and 607624) is a rare, autosomal recessive disorder first described by Griscelli et al in 1978 as an immunodeficiency syndrome associated with partial albinism. It is characterized by generalized hypopigmentation of the skin and the hair, the presence of clumps of pigment in the hair shafts and an accumulation of melanosomes in the melanocytes. [1]

GS was classified into three different subtypes- In addition to pigment problems, type 1 (GS1 [MIM 214450], Elejalde), caused by mutation in the *MYO5A* gene, is associated with severe primary neurological impairment such as developmental delay and mental retardation.

The second type (GS2 [MIM 607624]), caused by mutation in *RAB27A* gene, is associated with a primary immunodeficiency due to dysfunctional T cell and impaired natural killer cytotoxic activity, which can lead to increased

susceptibility to repeated infections, and culminates in a life-threatening condition known as hemophagocytic syndrome or hemophagocytic lymphohistiocytosis (HLH). It is usually triggered by viral infections, marked by periods of fever, hepatosplenomegaly and pancytopenia.

The third type (GS3 [MIM 609227]), caused by mutation in the melanophilin gene (*MLPH*), is restricted to hypopigmentation defects. [2]

Three proteins- myosin -Va, Rab27a and melanophilin, together form a heterotrimeric protein complex, in melanosome transport. Defect in any one of these proteins leads to pigmentary defect which is common to GS1, GS2, and GS3. [4]

## CASE REPORT

A female child, born out of consanguineous marriage, 1 year age, presented with complaints of silvery colored hairs in scalp and eyelashes, with history of repeated infections and ataxia. Her peripheral smear finding was that of

hemolytic anemia, C T Brain showed 1.3 x 1cm lesion in right parieto temporal region, CBC picture suggestive of pancytopenia, USG abdomen suggested mild splenomegaly.

Microscopic examination of patient's hair shaft was done and it showed irregular clumps of pigment along with hypo pigmented areas and pigment clumps, present at the periphery of shaft as compared with normal hair shaft. These features were suggestive of Griscelli Syndrome.

## DISCUSSION

The initial diagnosis of Griscelli Syndrome (GS) can be made without sophisticated tools but merely from microscopic examination of hair follicle for characteristic abnormal melanin clumps. The prognosis for long term survival of griscelli syndrome patients is relatively poor. It is caused by RAB27A defect, GS is usually rapidly fatal within 1 to 4 years without treatment at onset of an accelerated phase. The early recognition of GS is important because affected children are predisposed to recurrent, overwhelming infections and/or HLH, both of which may lead to a fatal outcome. [3] Haematopoietic stem cell transplantation is the only curative option in this condition. Patients with GS who fail to be transplanted usually die within 5 years after diagnosis. 5. Chemotherapy and allogenic bone marrow transplantation form a part of treatment. In the form with MYO-VA defect, no specific treatment can be proposed. The severe neurological treatment and retarded psychomotor neurological impairment and retarded psychomotor development do not improve with time. [1]

Hence the diagnosis of griscelli syndrome must be considered for any child with hypopigmentation accompanied by neurological abnormalities or signs of accelerated phase such as hepatosplenomegaly, jaundice or pancytopenia. Microscopic examination of the hair shaft provides strong support for the

diagnosis of griscelli syndrome. Confirmation can be provided by mutation analysis of the patient's DNA. [2]

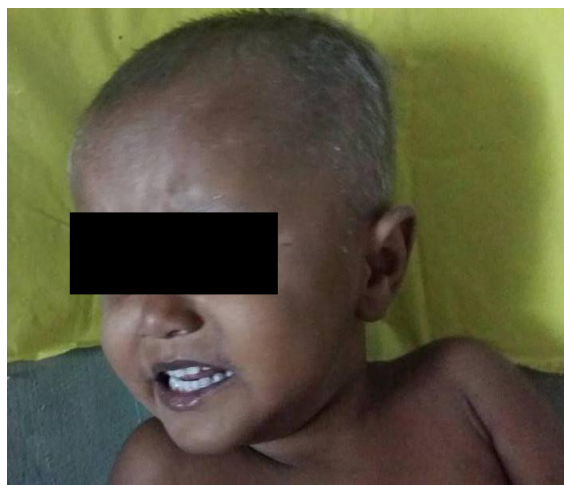

Fig. 1: Child presenting with grey colored hair.



Fig. 2: Microscopic features of a hair follicle demonstrating clumping of melanin pigment along the shaft.

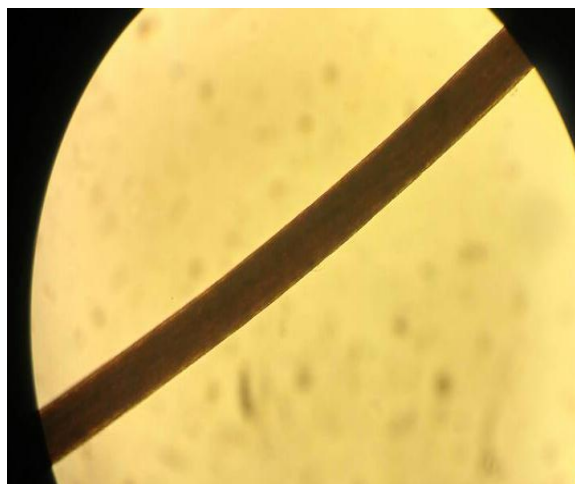


Fig. 3: Microscopic feature of a normal hair.

## REFERENCES

1. HaryAriffin, Anne Geikowski, Tong Foh Chin, ShekharKrishnan: Griscelli syndrome: case report. *Med J Malaysia* Vol 69 No 4 August 2014.
2. Meschede IP, Santos TO, Izidoro-Toledo TC, *et al.* Griscelli syndrome-type 2 in twin siblings: case report and update on RAB27A human mutations and gene structure. *Braz J Med Biol Res.* 2008; 41(10): 839-48.
3. Dr. Genevieve de Saint-Basile. Griscelli syndrome. Orphanet encyclopedia, May2003. <http://www.orpha.net/data/patho/GB/uk-griscelli.pdf>
4. Menasche G, Ho CH, Sanal O, Feldmann J, Tezcan I, Ersoy F, *et al.* Griscelli syndrome restricted to hypopigmentation results from a melanophilin defect (GS3) or a MYO5A F-exon deletion (GS1). *J Clin Invest* 2003; 112: 450-456.

How to cite this article: Roy S, Pore SN, Joshi AR *et al.* Use of hair mount as an aid to the diagnosis of griscelli syndrome. *Int J Health Sci Res.* 2018; 8(6):372-374.

\*\*\*\*\*