

Pyramidal Lobe: Existence and Role in Subtotal Thyroidectomy

Elghazaly A. Elghazaly

Department of Human Anatomy, Faculty of Medicine, University of AL.Baha. KSA.

ABSTRACT

The presences, position, extend and size of the pyramidal lobe of the thyroid gland was postmortem studied in 65 dissected cadaver neck specimens. The aim of this study is to study the anatomical relationship of the pyramidal lobe to the neck structures, and its clinical significance relevant to thyroid surgery. The pyramidal lobe was found in 55.4% of cases as a single projection extends upwards from the thyroid tissue, more common in males, and usually being situated on the left side of the isthmus of thyroid gland. The shape, size, position and extend of the pyramidal lobe was varied; depending on the presences of a fibrous or muscular band that may represent a remnant of the thyroglossal duct during the development of the thyroid gland. The dissection study of the pyramidal lobe shows more results than the imaging one, and most of pyramidal in dissection study were appeared connected superiorly by fibrous connective tissue, this indicates the anatomical and surgical importance of this structure in clinical practice of thyroid surgery. While dissection showed more results, we believed that our data can be used to perform safer and more effective of partial thyroidectomy in order to preserve thyroid function after surgical treatment.

Key words: thyroidectomy, pyramidal lobe, anatomy of the thyroid gland.

INTRODUCTION

The pyramidal lobe (PL) sometimes present as a narrow conical projection of thyroid tissue extending upwards from the upper border of the thyroid isthmus, lying on the right or left of the prominence of thyroid cartilage, more common to the left side. ^(1,2) It is vestige as embryonic remnants of the thyroglossal duct during the development of the thyroid gland. The PL is connected by a fibromuscular band (levator glandulae thyroidae) to hyoid bone and acquires different shapes, positions and extends. Incidence of the PL is varied, depending on the incomplete obliteration of the distal part of the thyroglossal duct, and should therefore be regarded as a normal component of the thyroid gland and not as a congenital abnormality. ⁽²⁾ Any pathologic process that is raised from thyroid gland may involve the PL, example (Grave's disease), thus it becomes of diagnostic

importance in thyroid surgery. ^(3,4) The importance of the PL is associated with anatomical relation to developmental anomalies and its attachment to superior neck structures, and also in its propensity to undergo hypertrophy when the rest of the gland has been removed in subtotal thyroidectomy and PL left behind. In this case the PL moves superiorly and situate sublingually, this may produces gagging, nausea, recurrent hyperthyroidism, origin of a thyroid cancer and multifocal disease in cases of Papillary Carcinoma. ⁽⁴⁻⁶⁾ To avoid these complications, PL should be removed during subtotal thyroidectomy. The aim of this study is to study incidence, size, location, connection and shape of the PL of the thyroid gland using dissection cadavers and its important anatomical relationship of surgical significance relevant to thyroid surgery in the neck region.

MATERIALS AND METHODS

The PL of the thyroid gland was studied in 65 thyroid specimens of both sexes, 45(69, 2%) males and 20(30, 8%) females in 2016. The specimens were studied from formalin fixed necks cadavers in dissection rooms. The specimens were obtained from dissected cadavers used for anatomical courses, using natural anatomical dissection tools and methods. The study was carried in five dissection rooms in science Faculties of Medicine and healthy Sciences, in Khartoum State, Sudan. The dissection was evaluated for the presence, location, length, connection, shape and any others additional comments of the PL. The thyroid gland was full examined to investigate the percentages and common anatomical variations in the origin of the pyramidal lobe in order to determine their incidence, location, size and extend in the Sudanese subjects

RESULTS

Out of 65 dissected neck specimens, the PL was found in 36(55.4%), 24 in the male specimens and 12 in female specimens. In 18 (50%) PL were found originated from left lobe, in 11 (30.6 %) were originated from right lobe and 7 (19.4 %) were originated from isthmus of the thyroid gland, (table 1). Out of all PL specimens, 23 (63.9%) were appeared typically shaped pyramidal, 8 (22%) were appeared cone shaped lobes and 5 (13.9 %) were irregular shaped lobes, (table 2). The length of the PL varied; in 5 (13.9%) specimens the PL were short extending to lower border of the cricoid cartilage, in 11 (30.4%) specimens extends over upper border of cricoid cartilage and 20 (55.6%) specimens the PL was found extending over the thyroid cartilage (table 3) (figure2). Most PL were found connecting with thyroglossal duct, (table 3) (figure 2).

(Table 1) –shows the origin of the pyramidal lobe

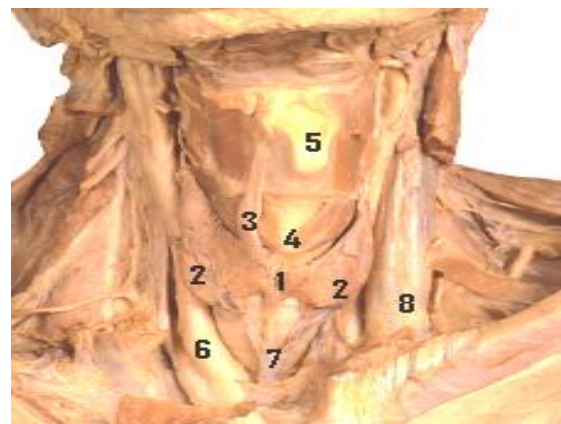
Side of the origin	Incidence	Percentages
from left lobe	18	50%
From right lobe	11	30.6%
from isthmus	7	19.4%
Total	36	100%

(Table 2) –shows the shape of the pyramidal lobe

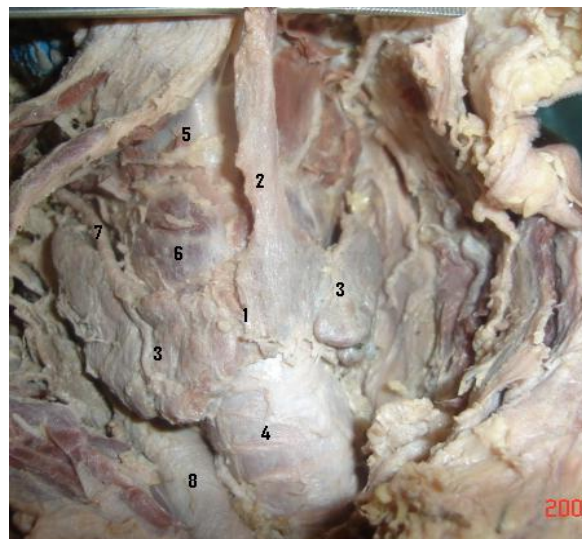
Shape of pyramidal lobe	Incidence	Percentages
Typically pyramid shaped	23	63.9%
cone shaped	8	22%
Irregular shaped	5	13.9%
Total	36	100%

(Table 3) –shows the size of pyramidal lobe, and it is connection with thyroglossal duct

length of pyramidal lobe in (cm)	Incidence	Percentages
long (more than 2 cm)	20	55.6%
Medium (arranged between 1-2 cm)	11	30.4
short (less than 1 cm)	5	13.9%
Total	36	100%
Connection of pyramidal lobe	Incidence	Percentages
Connected with thyroglossal duct	29	80.6%
Not connected with thyroglossal duct	7	19.4%
Total	36	100%



(Figure1). Dissected neck shows thyroid gland with pyramidal lobe originated from right side of the isthmus. 1- Isthmus. 2- Lateral lobe. 3- Pyramidal lobe. 4- Cricoid cartilage. 5- Thyroid cartilage. 6- Common carotid artery. 7- Inferior thyroid vein.



(Figure2). Dissected neck shows thyroid gland with pyramidal lobe originated from left side of the isthmus. Isthmus. 2- Pyramidal lobe. 3- Lateral lobe. 4- Trachea. 5- Thyroid cartilage. 6- Cricoid cartilage. 7- Superior thyroid artery. 8- Common carotid artery.

DISCUSSION

The pyramidal lobe is varied in shape, position as well as appearance and size. These variations occur during the development and migration of the thyroid gland from its origin in the tongue downwards to the neck, then the gland retains connected to the pharynx by a narrow epithelial stalk known as the thyroglossal duct, which usually becomes obliterated by the eighth to 10th weeks of gestation, the remnants of the thyroglossal duct form the variations in the pyramidal lobe of the thyroid gland. While the PL is considered a part of the thyroid tissue, it must be studied with the anatomy of the thyroid gland. Siraj⁽³⁾ in 1989 studied thyroid gland scintigraphically in 207 patients, found that the PL was visualized in (41%) of cases, he established that PL arise from the isthmus or right lobes of the gland was about the same, and Bergman⁽¹⁾ in 1992 studied thyroid gland variations, he found that there were many anatomical variations in the thyroid gland, due to a partial persistence of the thyroglossal duct, he published that most obvious examples of this persistence is the PL which found in about 40% of cases. Levy⁽⁷⁾ in 1997 used Gamma Camera scan in patients with diffuse toxic goiter, found that PL was appeared in about (43%) cases of thyroid images. Ryu⁽⁸⁾ in 2014⁽⁹⁾ and Kim in 2013 studied thyroid gland ultrasound and found similar results of the Siraj.⁽³⁾ But in 2007 Braun⁽²⁾ studied PL in cadaver specimens; he reported that, the prevalence is about 55% of the cases. In this study PL was appeared in (55.4%) specimens, more common arises from the left side of the isthmus of the thyroid gland, this study confirmed the study of Braun. There is difference in the incidences of the PL in the studies which used images and the studies which use dissection cadavers, referred to the differences in the methods and technique use of the studies, the dissection studies give more results than images. The present study shows small size and irregular shapes PL arising from the upper border of the

isthmus, which difficult to be detected or visualize by the images. Most of PL in this study were found connecting superiorly by band of fibrous connective tissues with floor of the mouth, and therefore it may move up by its attachment and locate sublingual after thyroid surgery, thus it may become item for complications after thyroid surgery. Conclusion: as a part of the thyroid tissue, PL is important in diagnostic of thyroid surgery. Surgeons should put in mind the presence of PL in case of subtotal thyroidectomy because if the PL is left behind, it will be under hypertrophy and moves superiorly by its attachment to become sublingual producing gagging, nausea. Recommendation: that to avoid these complications after thyroid surgery, the surgeons should remove PL during the thyroidectomy especially if connected superiorly by any connection.

REFERENCES

1. Bergman R AN and Afifi A K. Compendium of Human Anatomic variation Text, Atlas and World Literature 1st ED. Urban & Schwarzenberg. 1992; Pp (175, 530-537).
2. Braun EM, Windisch G, Wolf G, Hausleitner L, Anderhuber F. The pyramidal lobe: clinical anatomy and its importance in thyroid surgery. *Surg Radiol Anat.* 2007;29:21–27.
3. Siraj QH, Aleem N, Inam-Ur-Rehman A, Qaisar S, Ahmad M. The pyramidal lobe: a scintigraphic assessment. *Nucl Med Commun.* 1989;10:685–693.
4. Milojevic B, Tosevski J, Milisavljevic M, Babic D, Malikovic A. Pyramidal lobe of the human thyroid gland: an anatomical study with clinical implications. *Rom J Morphol Embryol.* 2013;54(2):285-9.
5. Blumberg N A. S. Observations on the pyramidal lobe of the thyroid gland. *Afr Med J.* 1981; 20; 59(29):949-50
6. Arzu Cengiz, Hatice Şakı, and Yakup Yürekli. Scintigraphic Evaluation of Thyroid Pyramidal Lobe. *Mol Imaging*

- Radionucl Ther. 2013; 22(2): 32–35.
7. Levy HA, Sziklas JJ, Rosenberg RJ, Spencer RP. Incidence of a pyramidal lobe on thyroid scans. Clin Nucl Med. 1997; 22 (8):519-22.
 8. Ryu JH, Kim DW, Kang T. Pre-operative detection of thyroid pyramidal lobes by ultrasound and computed tomography. Ultrasound Med Biol. 2014;40(7):1442-6.
 9. Kim DW1, Jung SL, Baek JH, Kim J, Ryu JH, Na DG, Park SW, Kim JH, Sung JY, Lee Y, Rho MH. The prevalence and features of thyroid pyramidal lobe, accessory thyroid, and ectopic thyroid as assessed by computed tomography: a multicenter study. Thyroid. 2013;23(1):84-91

How to cite this article: Elghazaly EA. Pyramidal lobe: existence and role in subtotal thyroidectomy. Int J Health Sci Res. 2018; 8(6):56-59.
