

High Origin of Radial Artery: An Anatomical Variation with Its Embryological Basis & Clinical Significance

Kusum R Gandhi¹, K.Naga Vidya Lakshmi²

¹Assistant Professor, Department of Anatomy, All India Institute of Medical Sciences, Bhopal

²Associate Professor, Department of Anatomy, St. Joseph's Dental College, Eluru, Andhra Pradesh

Corresponding Author: K.Naga Vidya Lakshmi

ABSTRACT

BACKGROUND: Radial artery is the smaller terminal branch of brachial artery. Abnormal variations in the anatomy of radial artery may produce an iatrogenic injury leading to undesired complications.

MATERIALS & METHODS: Study was carried out on 18 formalin fixed cadavers i.e. 36 limbs of adult age in the Department of Anatomy. Arm and forearm of both upper limbs were carefully dissected to note the variation in the origin of Radial artery.

RESULT: Unilateral Variations of high origin of Radial artery were observed in two cases (5.55%). In first case, radial artery was originated from right brachial artery 13.5 centimetre above the intercondylar line while in second case it was 19 centimetres above the intercondylar line.

CONCLUSION: In recent times, there has been an increase in the use of radial artery for various diagnostic & invasive procedures which requires the qualified apprehension of the variant anatomy to avoid iatrogenic injury and perform safe procedures.

Key Words: Superficial Radial artery, High origin, Invasive procedures

INTRODUCTION

The insight of the course and the relationships of upper limb vasculature accounts for a lot of diagnostic measures and handful surgical approaches. [1] Variations in the vasculature of the upper extremity are due to defects in embryonic development of the vascular plexus of upper limb bud. [2] The present study was performed to find the origin of radial artery and evaluation of the data by correlating with the existing literature along with its embryological explanation and clinical significance.

Classically, the radial artery arises as a smallest terminal branch from brachial artery at the level of the neck of radius, 1

centimeter below the bend of elbow. It traverses deep to the brachioradialis muscle in the forearm and terminates in the hand by forming the deep palmar arch after anastomosing with the deep branch of the ulnar artery. [3] A high origin of the radial artery is the most common vascular pattern variation of the upper extremity which evokes various clinical interests. [4,5] Incidence of high origin of radial artery varies from 4.17% to 15.60% in cadavers and embryos, [6] whereas in angiographic images, the incidence varies from 8.00% to 24.40%. [7]

MATERIALS & METHODS

The Current study was done in the Department of Anatomy, Rural Medical College, Loni, and Maharashtra, India on 18 formalin fixed cadavers of both sexes i.e.36 limbs of adult age as a part of routine dissection programme for undergraduates. Armand forearm of both sides were carefully dissected to note the variation in the origin of Radial artery. Photographs were taken using a digital camera. Limbs with the mark of any pervious surgeries or any mode of damage in that area were excluded from the study.

OBSERVATIONS AND RESULTS

Unilateral variations in the origin of radial artery with an incidence of 5.55% were observed in the right upper limbs of two cadavers.

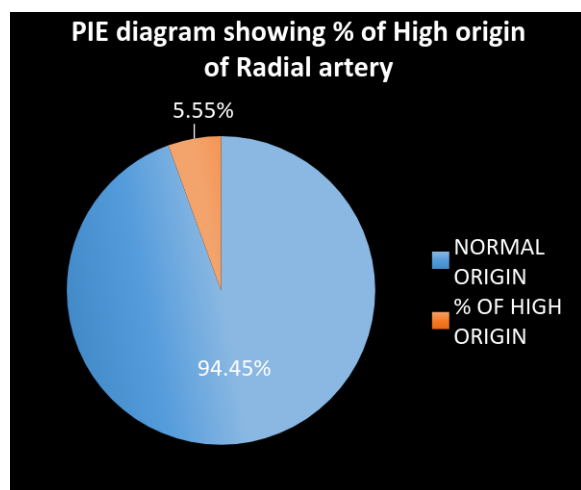


Table 1: Comparison of incidence of High origin of Radial artery with previous literature.

Name of the Author	Year	Incidence of HORA
Dubreuil and Chamberdel	1906	13.97%
McCormack et al	1953	2.13%
Rodriguez-Niedenfuhr et al	2001	6.25%
Yang et al	2008	2.30%
Agarwal S et al	2016	3.12%
Present study	2017	5.55%

FIRST CASE(Fig:1) The radial artery originated from the anteromedial surface of the right brachial artery 13.5 centimeter above the intercondylar line just inferior to the insertion of the coracobrachialis muscle. The artery was tortuous and first traversed along the medial border of biceps muscle

along with brachioulnar artery and medial nerve then at a distance of 10 centimeters above the intercondylar line it crossed superficially the brachioulnar artery and median nerve.

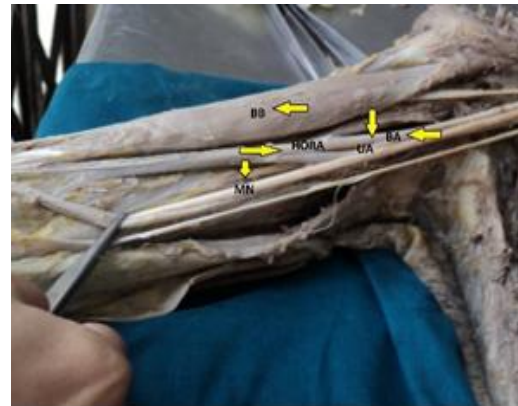

Fig: 1 HORA 13.5cm above the intercondylar line

SECOND CASE(Fig:2) The radial artery originated from the anteromedial surface of the right brachial artery 19 centimeter above the intercondylar line after giving the profunda brachii artery. In the arm initially the radial artery traversed medial to the median nerve along with the brachioulnar artery. In the middle third of arm the brachioulnar and radial artery adapted a superficial oblique course covered only by the brachial fascia. In the lower third of the arm at the distance of 8 centimeters above the intercondylar line the radial artery crossed over the median nerve to its lateral side.

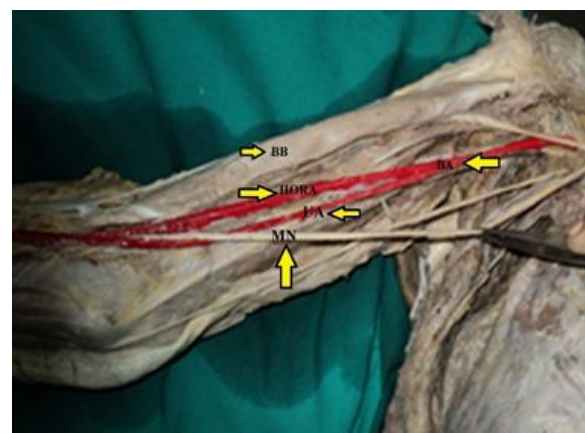


Fig: 2 HORA 19cm above the intercondylar line

DISCUSSION

Normally an anatomist focuses on the rare anatomical variations but the arterial variations that occur frequently have a greater clinical significance as they are more likely to be encountered. Most of the times radial artery is used in surgical procedures such as when raising a radial forearm flap, as graft for coronary bypass and intransradial approach during coronary interventions (Valsecchi et al [7] 2006, Funk et al [8] 1995, Pelin et al [9] 2006). For coronary procedure the trans radial approach is widely accepted then the trans femoral and/or trans brachial techniques because it reduces the site complications. [10] Furthermore, the radial artery is chosen because it is not accompanied by major veins or nerves.

As shown in Table 1 Dubreuil and Chamberdelhas reported 72 cases of high origin of radial artery out of 136 cases in which 19 arose from the axillary artery. [11] McComark et al has studied 750 extremities of cadavers and noted high origin of radial artery in 16 of 750 arms i.e.2.13% of cases. [12] Yang et al studied 304 Korean cadavers and found high origin of radial artery in 2.3% of cases. [13] Waghmare J E et al, 2009 described a case of high origin of radial artery with asymmetric vasculature of upper limbs. [14] Agarwal et al in the year 2016 reported this incidence in 3.12% of cases. [15] The present study depicts an incidence of high origin of radial artery in 5.55% cases which can be correlated with the study made by Rodríguez-Niedenführ M et al who reported the same in 6.25% of the cases. [16] According to literature the variant artery often arises from the proximal third of the brachial artery but in our case it was arising from the middle third of the brachial artery 13.5 and 19 cm above the intercondylar line.

Embryological basis of the present cases can be explained if we look at the developmental stages of the upper limb arteries. The axis artery of the upper limb is derived from the lateral branch of seventh intersegmental artery (subclavian).It gives the superficial brachial artery a consistent embryonic vessel situated anterior to the

cords of brachial plexus. The superficial brachial artery has two terminal branches above the elbow joint; lateral of which continued in the forearm as a part of the definitive radial artery and medial one termed as superficial antebrachial artery.

Rodriguez- Baeza et al emphasized on the fact that normal vascular development including the patterning of blood vessels is influenced greatly by local hemodynamic factors. Altered hemodynamic environment may give rise to variant patterning of blood vessels. [17]

THE EMBRYOLOGICAL EXPLANATION OF THE PRESENT FINDINGS

The superficial antebrachial artery formed and crossed anterior to the brachial plexus (median nerve). Lateral communicating branch of the primitive axial artery or the anastomotic channel between it and superficial brachial artery did not form. There after the latter had attained the hemodynamic predominance and persisted as the radial artery as a branch of brachial artery high unpins the upper limb. [11,18-20] It ran anterior to median nerve. The rest of the development of upper limb vasculature was normal.

CONCLUSION

All these anatomic variations theorize that each individual is and must be considered as a particular entity. Any arterial variation can have both morphological and clinical significance. Cardiologists, radiologists or vascular surgeons involved in the diagnostic and operative procedures should be vigilant of these possibilities of anatomical alterations and in case of any doubt a color Doppler ultrasound of the limb has to be carried out.

Abbreviations:

BB: Biceps Brachii muscle
BA: Brachial artery
HORA: High origin of Radial artery
UA: Ulnar artery
MN: Median nerve

REFERENCES

1. Jurjus A, Sfeir R, Bezirdjian R. Unusual variation of the arterial pattern of the human upper limb. *Anat Rec.* 1986;215:82-3
2. Hollinshead WH. Anatomy for Surgeons. The back and limbs. In: Pectoral region, axilla and shoulder: The axilla. 1958;3:290-300
3. David Johnson Gray's Anatomy. Pectoral Girdle and Upper Limb, 40th Ed., London, Churchill Livingstone. 2008; 815–817.
4. Compta XG. Origin of radial artery from the axillary artery and associated hand vascular anomalies. *Journal of Hand Surgery.* 1991;16(A):293-6
5. Harbans Singh, Neena Gupta, Bargotra RN, NP. Singh, Higher Bifurcation of Brachial Artery with Superficial Course of Radial Artery in Forearm; *JK Science* Vol.12 No.1, January-March 2010
6. Quain R. Anatomy of the arteries of the human body. Taylor and Walton, London. 1844;326-37
7. Valsecchi O, Vassileva A, Musumeci G, Rossini R, Tespili M, Guagliumi G, Mihalsik L, Gavazzi A, Ferrazzi P. Failure of transradial approach during coronary interventions: anatomic considerations. *Catheter Cardiovasc Interv.* 2006;67:870-8
8. Funk GF, Valentino J, McCulloch TM, et al. Anomalies of forearm vascular anatomy encountered during elevation of the radial forearm flap. *Head Neck* 1995;17:284–292
9. Pelin C, Zagypapan R, Mas N And Karbay G (2006). An unusual course of the radial artery *Folia Morphologica* 65(4) 410-413
10. Konstantinos Natsis, Anastásia L. Papadopoulou, Efthymia Papathanasiou, George Noussios, George Paraskevas, Nikolaos Lazaridis (2009) Study of two cases of high-origin radial artery in humans; *Eur J Anat* 13 (2): 97-10.3
11. Dubreuil-Chambradrel L. L'Arteremediane. *Gazette Medieale du centre*, Cited by Singer E. Embryological patterns persisting in arteries of the arm. *Anat Rec.* 1933;55:406-13
12. McComarck LJ, Cauldwell EW, Anson J. Brachial and antebrachial arterial patterns. *SurgGynecolObstetr.* 1953;96:43-54
13. Yang HJ, Gil YC, Jung WS, Lee HY. Variations of the superficial brachial artery in Korean cadavers. *J Korean Med Sci.* 2008;23:884-7. 11
14. Waghmare JE, Tarnekar AM, Sonatakke BR, Bokariya P, Ingole IV. A high origin of radial artery with asymmetrical vasculature of upper limbs: a case report. *Nepal Med Coll J.* 2009; 11: 284–286.
15. Agarwal S et al. High origin of radial artery: a comparative, anatomical and embryological consideration. *Int J Res Med Sci.* 4(8):3295-3298
16. Rodríguez-Niedenführ M, Vázquez T, Nearn L, Ferreira B, Parkin I, Sañudo JR. Variations of the arterial pattern in the upper limb revisited: a morphological and statistical study, with a review of the literature. *J Anat.* 2001;199:547-66
17. Rodriguez-Baeza A, Nebot J, Ferreira B, Reina F, Perez J, Sanudo JR. An anatomical study and ontogenic explanation of 23 cases with variations in the main pattern of the human brachio-antebrachial arteries. *Journal of Anatomy.* 1995;187:473-9
18. Balchandra N et al, (2011) Unusual origin of Radial artery *International Journal of Anatomical Variations* 4: 101–103
19. Namani Satyanarayan, P Sunitha, M M Shaik, PSV Devi, Brachial artery with high up division with its embryological basis and clinical significance; *International Journal of Anatomical Variations* (2010) 3: 56–58
20. Konstantinos Natsis, Anastásia L. Papadopoulou, Efthymia Papathanasiou, George Noussios, George Paraskevas, Nikolaos Lazaridis (2009) Study of two cases of high-origin radial artery in humans; *Eur J Anat* 13 (2): 97-10.3

How to cite this article: Gandhi KR, Lakshmi KNV. High origin of radial artery: an anatomical variation with its embryological basis & clinical significance. *Int J Health Sci Res.* 2018; 8(6):52-55.
