

Case Report

Fabrication of Complete Dentures Using Neutral Zone Technique in a Patient with Severely Resorbed Alveolar Ridges - A Case Report

Dr. Kumari Deepika¹, Dr. Atul Bhatnagar², Dr. Ankita Singh³, Dr. Aprajita¹

¹Junior Resident, Prosthodontic Unit, FODS BHU, Varanasi, India

²Professor, Prosthodontic Unit, FODS BHU, Varanasi, India

³Assistant Professor, Prosthodontic Unit, FODS BHU, Varanasi, India

Corresponding Author: Dr. Aprajita

ABSTRACT

Completely edentulous patients wearing dentures since long time have a problem with decreased stability of their mandibular complete dentures because of severe resorption of lower edentulous ridge and altered neuromuscular control. This problem can be overcome by incorporating neutral zone technique in complete denture fabrication. In this case report, the steps of recording the influence of neutral zone in both maxillary & mandibular complete dentures are described using condensation silicone material.

Keywords:- Condensation Silicone, Neutral Zone, Denture stability.

INTRODUCTION

In edentulous patients, ridge resorption continues with advancing age. The greater the ridge resorption, the smaller the denture base area, that leads to reduced stability and retention of the denture. To overcome this problem, dentures are fabricated with their contours harmonizing neutral zone. [1] According to GPT- 9, "The neutral zone is the potential space between the lips and cheeks on one side and the tongue on the other, that area or position where the forces between the tongue and cheeks or lips are equal." [2] Many materials have been suggested for shaping the neutral zone namely modeling plastic impression compound, [1,3] soft wax, [4] impression plaster, [5] a polymer of dimethyl siloxane filled with calcium silicate, [6] silicone, [7] tissue conditioners and resilient lining materials. [8,9] Many techniques have also been suggested using the materials in conjunction with movements including sucking and pursing the lips along with

phonetics & swallowing. [10] In this case report, condensation silicone was used to record neutral zone.

CASE REPORT

A completely edentulous 71 years old male patient with severely resorbed mandibular ridge reported in the Department of Prosthodontics. Patient was denture wearer since 5 years & presented with complain of ill-fitting lower denture.

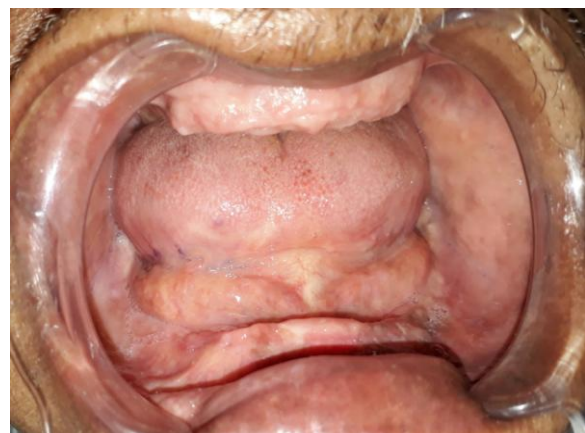

Figure 1: Lower Resorbed Mandibular ridge.

Primary impressions of the upper jaw and lower jaw was made in irreversible hydrocolloid (Alginate) impression material using previous denture and the model was poured in Type-II Gypsum Product(Dental Plaster).



Figure 2: Jaw relation & articulation in mean value articulator.

Upper and lower special trays were constructed by autopolymerising acrylic resin material and border moulding was done using low fusing green stick compound. After that secondary impression was made using Zinc-oxide eugenol paste and poured in Type-III Gypsum Product (Dental Stone).

Temporary denture bases were constructed using autopolymerising acrylic resin on master cast. Wax occlusal rims were fabricated and jaw relation was made using tentative method & articulated. After establishing tentative vertical dimension and centric relation record, new denture bases were fabricated with acrylic stops in molar region that engaging the orthodontic stainless steel wire to it for retention of the moulding material while recording neutral zone. Over posterior acrylic stops, vertical stops were established at the level of vertical dimension using low fusing green stick compound. (Figure 3 &4)

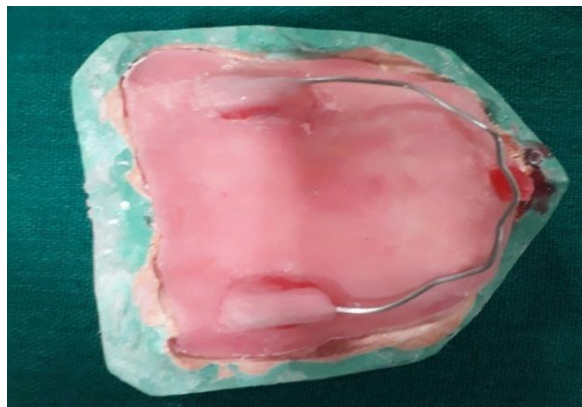
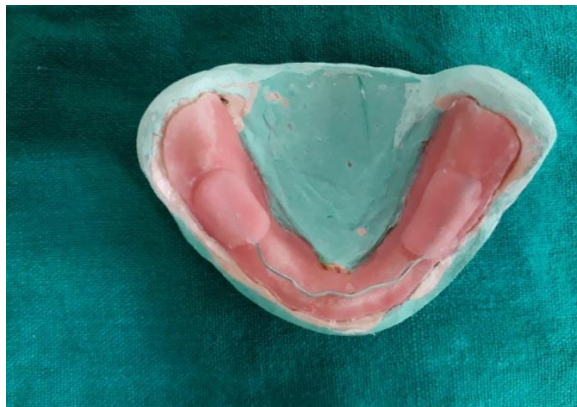

Figure 3: Temporary Denture Base with posterior acrylic stop engaging retentive wire.





Figure 4: Establishing vertical stop using green stick compound over acrylic stop.

Universal tray adhesive was applied over temporary denture base. After that Condensation silicone (Poly-Dimethyl Siloxane) putty impression material was adapted over the modified denture base at

established vertical dimension & moulded according to the muscle action in neutral zone by asking the patient to do actions like swallowing & saying words like “oo”, “eee”.

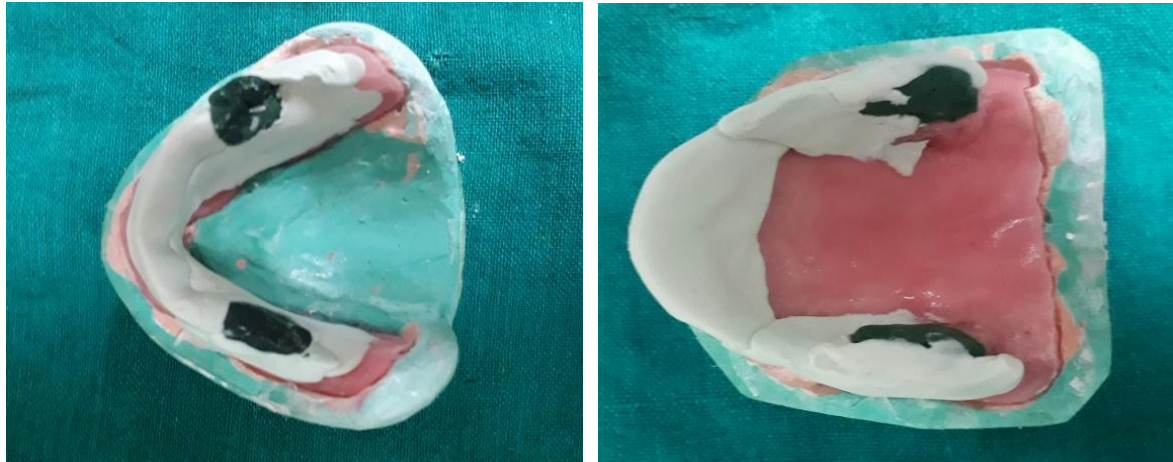


Figure 5: Moulded condensation silicone material in neutral zone.

The internal (Tongue musculature) and external muscle groups (Buccinator & Orbicularis group of muscles) have been brought into action, moving them through their respective action paths. In doing so, reciprocating pressures have been exerted upon the heavy body condensation silicone impression material, which had gradually moulded into a state of neutral balance and

become centrally inert in relation to all of the complex forces acting upon it. (Figure 5) The neutral zone impression so obtained was placed on master model, location grooves were cut on the master cast and was covered with Type-II Dental Plaster index around the impression on both the labial and lingual sides. (Figure 6)

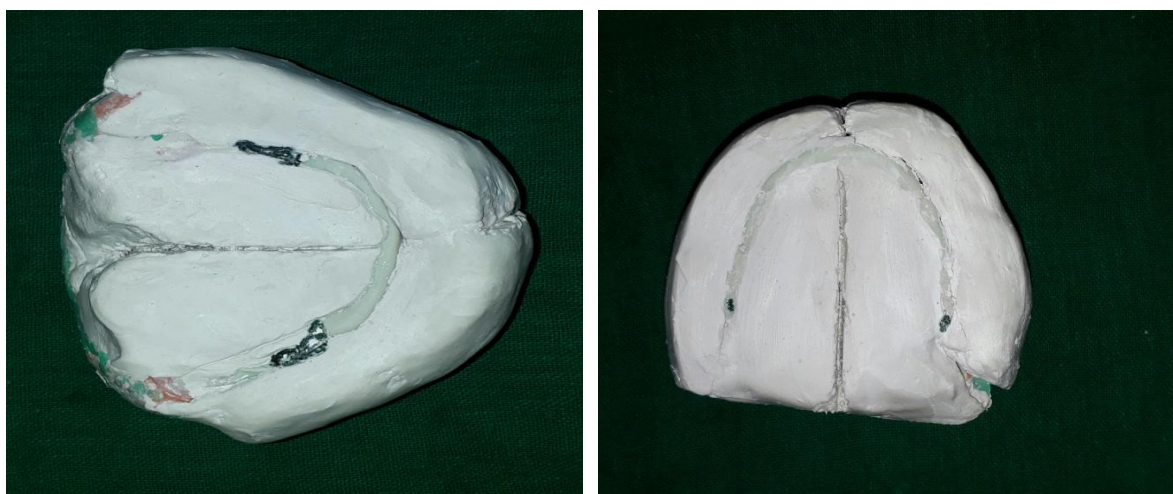


Figure 6: Dental Plaster index with mandibular & maxillary record base .

The condensation silicone impression material was then removed from the base plate, the neutral zone space can be preserved using plaster index and molten modelling wax was flowed into the space

created between the index that will take the shape of the moulded occlusal rim in neutral zone. (Figure 7) Similar procedure was done for moulding maxillary counterpart.

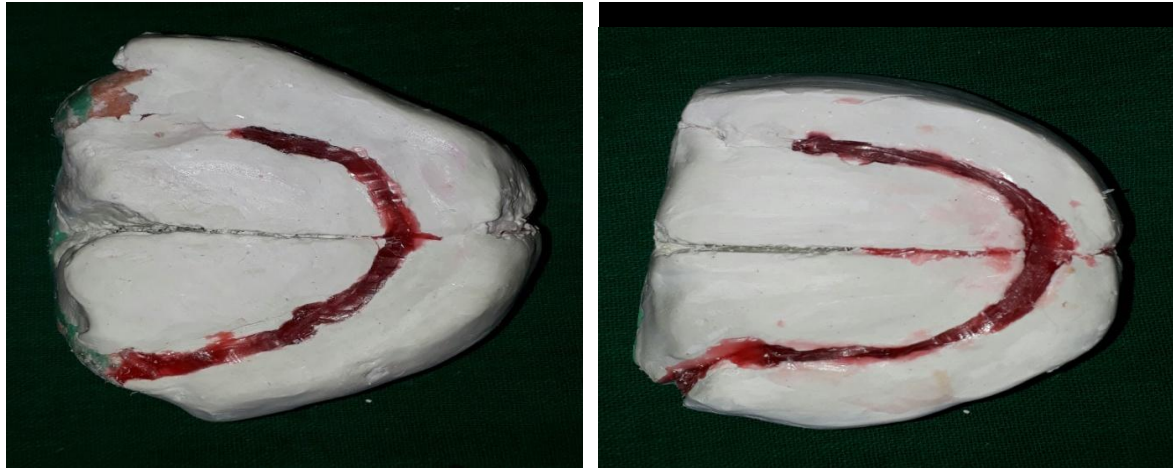


Figure 7: Moulded wax occlusal rim.

After that teeth arrangement was done and the position of the teeth was checked by placing the index around the wax try-in. As there was class-III relation posteriorly. Teeth arrangement was done in cross-bite cross-arch relation posteriorly. Once the waxed up dentures were ready,

they were checked in the patient's mouth for esthetics, phonetics and occlusion. (Figure 8 & 9) Once the try in was deemed satisfactory, the influence of the external & internal group of muscles once again recorded using light body condensation silicone. (Figure 10)

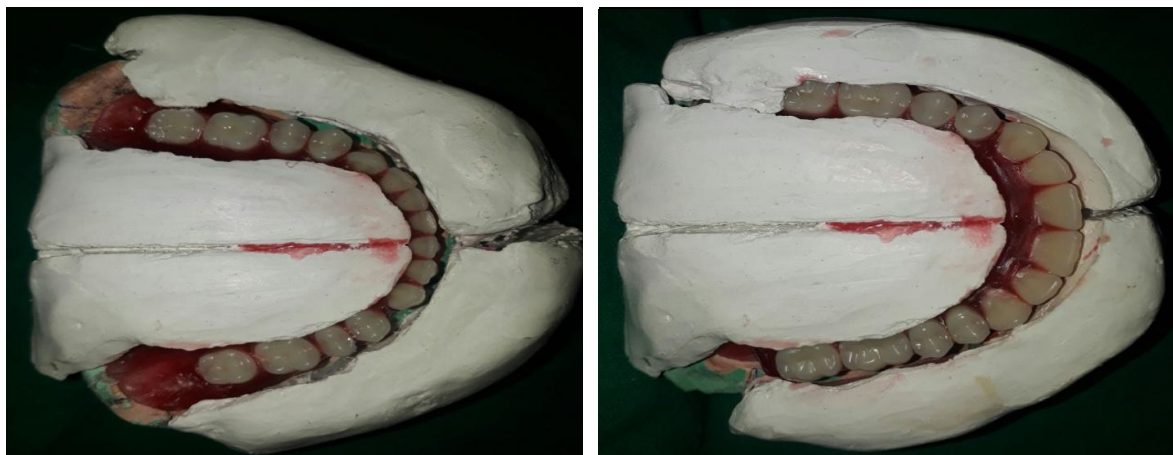


Figure 8: Positioning of Teeth checked within index.

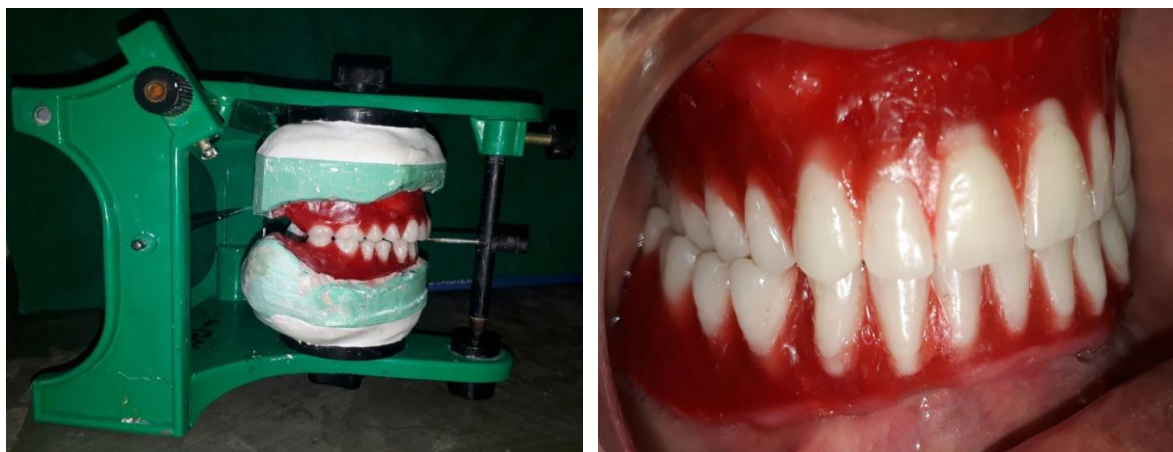
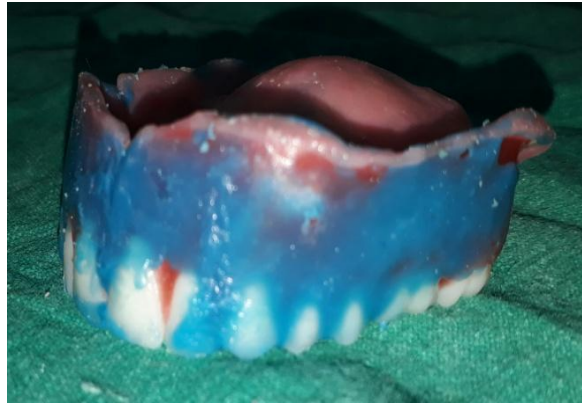


Figure 9: Cross-arch Cross-bite teeth arrangement & try-in .

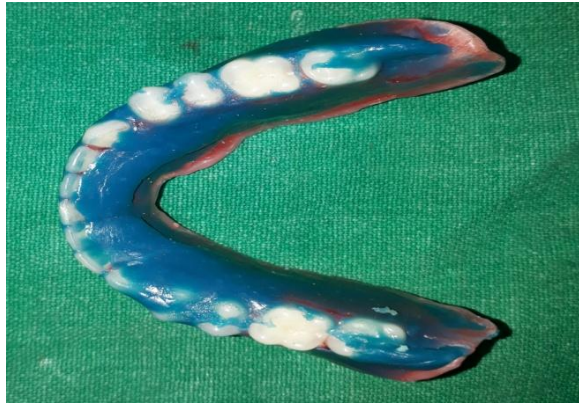

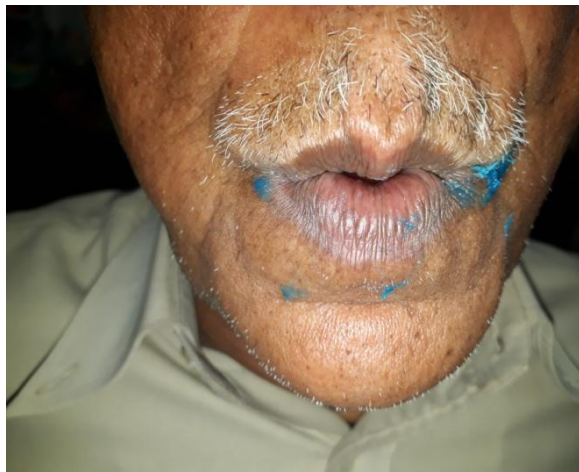Figure 10(a)



(b)



(c) Recording of influence of external & Internal group of muscles during Try-in.

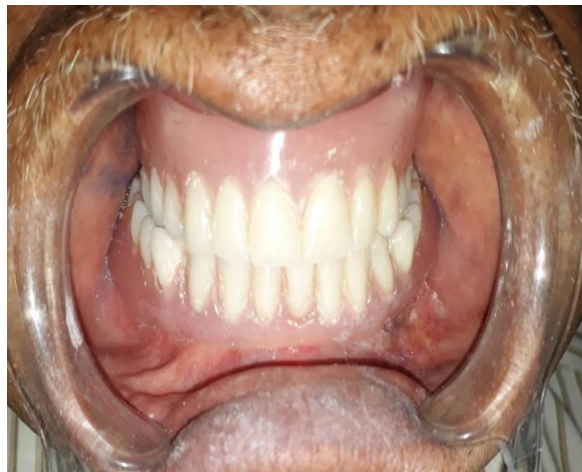

Figure 11: Complete denture in patient's mouth

After completion of try-in, denture fabrication was done in heat cure acrylic resin. Finished and polished complete denture was inserted in patient's mouth after doing minor occlusion correction. (Figure 11) Post denture instructions given to the patient and recall after 24 hours for checkup. Regular follow-up was done in 3 months interval upto 1 year.

DISCUSSION

Fish and other researchers emphasized on the concept of neutral zone that is the zone of equilibrium in which the outward forces exerted by tongue counterbalance the inward forces of lips and cheeks in complete denture construction. Fish pointed that out of the three surfaces of the denture the polished surface is bounded by the tongue and the cheeks. These are involved in normal physiologic movements such as speech, mastication, swallowing, smiling, and laughing. [1,10] Hence, the

fabrication of the denture must be in harmony with these functions. Maxillary ridge resorption occurs from buccal to palatal side whereas mandibular ridge resorption occurs from the lingual plate towards the buccal side results in more space for tongue movement leading to tongue enlargement over the years. On the other side, the cheek and lip muscles lose their tonicity with aging. This results in a shift of the neutral zone more towards the buccal and labial sides. Accurate recording of this zone and arranging the teeth in this zone is very important in increasing the denture stability. In this case report, the influence of neuromuscular action on both upper & lower complete dentures was recorded. Technique used here describes the fabrication of denture in coordination with neuromuscular action to develop proper complete denture contours and denture tooth positions. [1,11]

CONCLUSION

Neutral zone should be recorded in severely resorbed mandibular ridge with altered neuromuscular control which involves only one extra clinical step in conventional denture making that is easy to manipulate. This will help in improving denture stability and will provide more comfort to the patient.

REFERENCES

1. Beresin VE, Schiesser FJ. The neutral zone in complete dentures. *J Prosthet Dent* 1976;36(4):356-67.
2. The glossary of prosthodontic terms. *J Prosthet Dent* April 2017, Vol 117 issue 5S
3. Alfano, Leupold. Using the neutral zone to obtain maxillomandibular relationship records for complete denture patients. *J Prosthet Dent* 2001;85:621-3
4. Lott F, Levin B (1966) Flange technique: an anatomic and physiologic approach to increased retention, function, comfort and appearance of dentures. *J Prosthet Dent* 16:394–4135.
5. Johnson A, Northeast SE (1989). The unstable lower full denture- a practical and simple solution. *Restor Dent* 5:82–90
6. Miller WP, Monteith B, Heath MR. The effect of variation of the lingual shape of mandibular complete dentures on lingual resistance to lifting forces. *Gerodontology* 1998;15:113-9.
7. Barrenas L, Odman P. Myodynamic and conventional construction of complete dentures: a comparative study of comfort and function. *J Oral Rehabil* 1989;16:457-65.
8. Ohkubo C, Hanatani S, Hosoi T, Mizuno Y. Neutral zone approach for denture fabrication for a partial glossectomy patient: a clinical report. *J Prosthet Dent* 2000;84:390-3.
9. Kursoglu P, Ari N, Calikkocaoglu S (2007) Using tissue conditioner material in neutral zone technique. *N Y State Dent J* 73(1):40–42
10. Fish, E. W.: Principles of Full Denture Prosthesis, cd. 3, London, 1937, John Bale Medical Publication, Ltd.
11. Joseph E. Makzoume. Morphologic comparison of two neutral zone impression techniques: A pilot study. *J Prosthet Dent* 2004;92:563-8.

How to cite this article: Deepika K, Bhatnagar A, Singh A et al. Fabrication of complete dentures using neutral zone technique in a patient with severely resorbed alveolar ridges - a case report. *Int J Health Sci Res.* 2018; 8(4):227-232.
