

Case Report

Unification or Fusion of Mandibular Central and Lateral Incisor: Case Report

Dr. Srikanth. T^{1*}, Dr. Bala Saraswathi. K^{2**}, Dr. Dilip Chakravarthy^{2**},
Dr. Dhara Dwivedi³

¹Assistant Professor, Department of Conservative Dentistry and Endodontics,

^{*}Ayder Referral Hospital Mekelle, Ethiopia

^{**}C.K.S Teja Institute of Dental Sciences and Research, Tirupathi

³Assistant Professor, Department of Oral and Maxillofacial Pathology, Ayder Referral Hospital Mekelle, Ethiopia

Corresponding Author: Dr. Srikanth. T

ABSTRACT

Fusion is defined as two separately forming teeth joined together while gemination refers to partial development of two teeth from a single tooth bud. Fusion may be either complete or incomplete depending on the stage of development. The overall prevalence of the tooth fusion is approximately 0.5% -2-5% in deciduous teeth and 0.1% in permanent dentition. The exact aetiology is not clear, but it is thought that some pressures or physical forces may cause the contact of developing teeth. The case report presented here highlights a case of fusion between permanent mandibular central incisor with lateral incisor in a male patient.

Key words: Fusion, Gemination, unification, Developmental anomaly, Morphological, Tooth germs

INTRODUCTION

Dental abnormality of the structure and number of teeth can occur in the primary and permanent dentition. ^[1] Knowledge of internal morphology of human teeth is essential for the success of endodontic treatment. It's important to identify the possible anatomic variations and different anomalies present in all tooth groups. Anomalies originate in tooth development and cause alteration in the number and shape of the affected teeth. ^[2] Double tooth is the most common term that has been used to describe anomalies (Fusion or Gemination) in which one tooth is conjoined with another. The exact etiology of fusion is not completely clear; major factor thought to be causative factor of

fusion is the pressure and the physical forces which produce close contact between two developing tooth buds. Other than that, trauma, environmental factors and genetic factors are also assumed to be the contributing factors. Grover and Lorton claimed that local metabolic interferences that occur during tooth germ morpho-differentiation could be a cause. There is some evidence that the condition has a familial tendency. It may also be associated with syndromes such as achondroplasia and chondroectodermal dysplasia. ^[1]

Prevalence of fusion and gemination is of 0.23% and 0.07%, for fusion and gemination respectively. ^[1] The prevalence of fusion in primary teeth is 0.4%-0.9% and in permanent dentition it has been reported

to be 0.2% only and bilateral fusion in permanent is even more rare and reported to be 0.05%. [3]

Tooth gemination is an anomaly where two teeth attempt to develop from a single tooth bud, but without complete separation; thus, resulting in a larger tooth than normal but without alterations in the number of teeth in the affected dentition. The geminated tooth may present two crowns, together or separate, sharing a single root canal. Fusion, unlike gemination, occurs due to the union of two or more separately developing tooth buds at dentinal level, presenting with one single large tooth structure with a decrease in tooth number of the affected dentition, especially when it takes place between normal and supernumerary teeth. Fusion etiology is uncertain and may be associated to genetic predisposition, racial differences and impact and/or trauma during tooth bud development. [2]

Fusion is a morphological dental anomaly that arises when two normally separated tooth germs fuse or join together during the initiation or the morphodifferentiation stage of tooth development resulting in a single enlarged tooth structure with confluence of dentin, instead of two normal teeth. Depending upon the stage of development of the teeth at the time of this embryologic union, fusion may be either complete (true) or incomplete (partial) with fused or separate root canals. [3] Fused teeth are present asymptotically but may create concerns related to aesthetic or malalignment or malocclusion in the arch that may predispose to dental caries and periodontal problems and usually require multidisciplinary approach with expertise in various areas of dentistry to achieve functional and aesthetic success. [3]

CASE REPORT

30 year old male patient reported to the department of conservative dentistry and Endodontics with the chief complaint of decayed tooth since six months. The history of the patient did not reveal any associated

symptoms. On general examination, the patient was well oriented to time, place and person. On intra oral examination, it was noticed that only 3 incisors were present in the mandibular arch and 32 was found to be missing. It was also observed that left permanent mandibular central incisors were abnormally large in size with increased width mesio-distally. (Fig: 1) The patient's medical history was uneventful and was unaware of this dental irregularity and gave no history of any pain or discomfort associated with it. Thorough family history did not reveal any congenital dental anomalies and the accompanied parent had a normal permanent dentition. On the basis of the clinical findings, a preliminary diagnosis of fusion was made i.r.t 31 and 32.

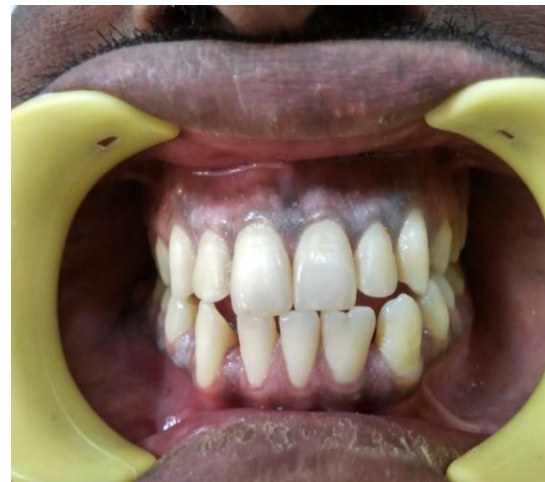

Fig 1: clinical image

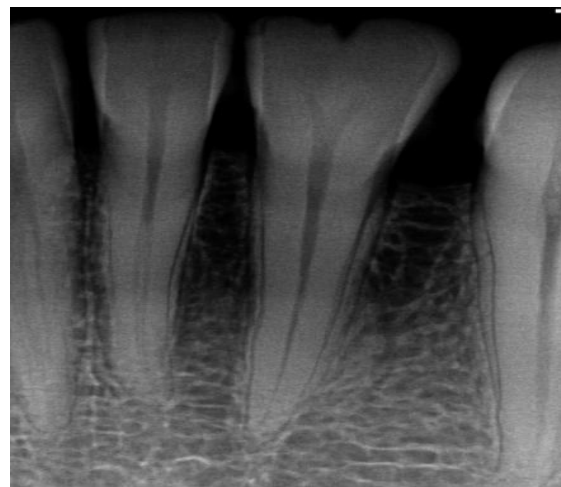


Fig 2: radiographic image

The diagnostic criterion was based on the fact that there were two teeth less than

normal complement when the double teeth were counted as one. Radiographic examination (fig: 2) revealed complete fusion of permanent central and lateral incisors with a single crown and a single root which is an uncommon finding. A confirmed diagnosis of fusion of mandibular permanent central and lateral incisors was made following the radiographic findings. The fused teeth were caries free and hence no treatment was carried out on them. The patient was informed about the existence of the dental aberration and oriented about the increased risk for development of dental caries and periodontal problems because of local conditions favoring plaque accumulation.

DISCUSSION

The terms Twinning, Joined tooth or Double tooth, is used to describe both fusion and gemination. [4] Fusion and gemination are two separate clinical entities describing two different morphological and developmental anomalies involving a characteristic large crown that may appear clinically similar. [3]

Despite considerable amount of reported cases of fusion and gemination, many researchers find the differential diagnosis between these two anomalies very difficult and confusing, and disagreement exists regarding the nomenclature. [3] The etiology of fusion remains unclear. Some authors claim that local metabolic interferences which occur during morphodifferentiation of the tooth germ may be the cause. Other etiological factors suggested are physical forces or pressure causing the contact of developing teeth, trauma and viral infection during pregnancy, or genetic basis possibly autosomal dominant with reduced penetrance. Environmental factors have also been implicated in the etiology. The differential diagnosis for fused teeth includes gemination and macrodontia. Fusion and gemination are usually mistaken while diagnosing. Therefore, careful clinical and radiographical examinations are required to

distinguish between these two entities. [5] Fused teeth are usually larger than normal size with total or partial union of dentin and with two separate root canals. Mandibular anterior teeth are affected more frequently than maxillary, depending upon racial, genetic or geographic factors. Fusion is observed to occur unilaterally and can be suspected when the number of teeth in the arch is found to be reduced and radiographically two roots are seen in relation to one crown. On the other hand, gemination is defined as incomplete division of one tooth germ, resulting in the formation of two partially or completely separated crowns formed on a single root, [1] According to Song et al., teeth affected with gemination have a single pulp canal and root, whereas fused teeth have separate pulp canals with combined dentin. [6] On the other hand, macrodontia is a condition in which the teeth are larger than usual and exhibit normal crown, root, and pulpal morphology. [5]

Introduced in 1979, Mader's "two tooth" rule is a popular way of identifying the difference between fusion and germination. [6] If the fused tooth is considered as one and the number of teeth in the dental arch is less, then the term fusion is considered. If the number of teeth in the dental arch is normal then it is termed as gemination or it is a case of fusion between normal and supernumerary tooth. But supernumerary tooth has conical in shape so it shows difference in the two halves of the joined crowns. [4] In our case, the number of teeth in the dental arch is less. These abnormal teeth have a high affinity to dental caries, periodontal problems, and spacing between teeth can also be an issue that needs to be addressed in such cases. [6] Its presence can lead to tooth size discrepancy and may influence teeth alignment, occlusion and arch symmetry. Morphology of double tooth is not aesthetically pleasing as very deep defects, in the form of groove or fissure occurs at the junction between the two teeth involved. Extension of these fissures or groves subgingivally makes the

tooth susceptible to accumulation of bacterial plaque in these defects leading to caries and periodontal problems. Strict maintenance of oral hygiene is essential to maintain good periodontal health while resin restorations or sealants can be used in deep fissures and grooves to reduce caries risk in these teeth. [1]

Endodontic treatment of fused teeth maybe a challenge, since localization and access to the canals might pose additional difficulties. Internal morphology of fused teeth varies and pulp chambers may be together or separated and a radicular area can be found. [2]

Among the various radiological techniques, conventional intraoral periapical views have a limited use in diagnosis since they usually cause superimposition of 2-dimensional images of a 3-dimensional object. Although the communication between pulp chambers of fused teeth is common. CBCT scans and an operative microscope may help the diagnosis and facilitate root canal localization in cases of complex and varied morphology. [2] The conventional multi detector computed tomography (CT) imaging was introduced to dental practice in the early 1990s, it is more recently that a new diagnostic imaging modality, CBCT, started to be used in dentistry as a preferred mode of radiological investigation due to its low radiation dose and effective maxillofacial imaging. Matherne et al. reported that CBCT imaging is highly effective in identifying the root canal systems and morphology of teeth. In endodontic management, periapical radiographs are mandatory for diagnosis, treatment, and follow-up, but the conventional intraoral periapical views provide only a two-dimensional view of the object. CBCT was suggested for the complex bizarre anatomy of the root canals for its useful diagnostic value with three-dimensional imaging, as this technology can provide an excellent visualization of the fused teeth, and the shape and number of the root canal system. Also, it provides the clinician with guidance for diagnosis and

presence of any tooth damage and is a highly useful aid for a successful endodontic treatment. CBCT scans and an operative microscope may help the diagnosis and facilitate root canal localization in cases of complex and varied morphology.

As morphology of the double tooth varies greatly, so will be its management. Bicuspidization could be considered as one of the treatment options for the fused teeth. Different treatment modalities like orthodontic correction, selective grinding and surgical separation followed by pulp therapy of the retained segment are available for double tooth. [1] Previously reported treatment options include bicuspidization upon completion of endodontic treatment for the fused tooth, orthodontic treatment for alignment, and extraction of the unwanted part. Due to the abnormal size and shape of crown and root as well as misalignment, both endodontic and esthetic issues should be addressed. This usually requires a multidisciplinary approach to the treatment. [6]

CONCLUSION

For every patient, after correct diagnosis, best treatment modality needs to be selected, so that excellent results can be achieved in restoring form, function and aesthetics. [1]

REFERENCES

1. Qutub Khan S, Agha D, Zafar S, Ashraf B: Double tooth: report of two unique clinical cases. *Pakistan Oral & Dental Journal* April-June 2016 ;36(2)
2. Baratto-Filho F, Leonardi D P, Crozeta B M, Baratto S P, E A Campos Tomazinho F S F, Delibeador T M: The Challenges Of Treating A Fused Tooth: *Braz Dent J* 2012; 23(3): 256-262.
3. Sultan A, Juneja A, Bhatnagar S: Bilateral fusion of permanent mandibular central and lateral incisors: A case-report of a rare developmental anomaly: *International Journal of Oral Health Dentistry*; July-September 2017;3(3):192-194.

4. Rao PK, Mascarenhas R, Anita A and Devadiga D: Fusion in Deciduous Mandibular Anterior Teeth - A Rare Case: ISSN: 2161-1122 Dentistry.
5. Castelino R L, Babu S G, Shetty S R, Laxmana A R, Balan P, Fazil KA: Syndontia of permanent mandibular central and lateral incisor- A rare entity: Balkan Military Medical Review 2015; 18(4):144-146.
6. Min Zhu¹, Chao Liu, Shuangshuang Ren, Zintong Lin, Leiying Miao, Weibin Sun: Fusion of a supernumerary tooth to right mandibular second molar: a case report and literature review: Int J Clin Exp Med 2015;8(8):11890-11895.

How to cite this article: Srikanth T, Saraswathi BK, Chakravarthy D et al. Unification or fusion of mandibular central and lateral incisor: case report. Int J Health Sci Res. 2018; 8(3):282-286.
