

# Clinical Applications and Therapeutic Outcomes of Scleral Contact Lenses- A Retrospective Study

Archana Preethi C<sup>1</sup>, Pallavi Joshi<sup>2</sup>, Umesh Y<sup>3</sup>

<sup>1</sup>Fellow, <sup>2</sup>Consultant, <sup>3</sup>Chief Medical Officer & Senior Consultant,  
Department of Cornea and Refractive Surgery, Sankara Eye Hospital, Bangalore.

Corresponding Author: Archana Preethi C

## ABSTRACT

**Objective:** To evaluate the indications and efficacy of semi and mini scleral contact lenses.

**Materials and Methods:** A total database of 45 eyes of 38 consecutive patients fitted with semi scleral or mini scleral lenses between January 2015 and December 2016, was retrospectively analyzed. All lenses were fitted by a preformed protocol. Ocular indications included keratoconus, pellucid marginal degeneration (PMD), post radial keratotomy (RK), Stevens-Johnson syndrome (SJS), post traumatic corneal scars, chronic blepharokeratoconjunctivitis and high refractive errors. National Eye Institute Visual Function Questionnaire (VFQ-25) was used to measure quality of life among patients wearing scleral lenses (n= 16).

**Results:** 79% of the patients were male. Maximum (34.2%) cases were seen in the age group 21 to 30 years. The mean follow up was 12 months (range 4-18 months). Major indications for the use of scleral contact lens was keratoconus (53.3%) followed by post radial keratotomy (17.8%), SJS (15.6%), post traumatic corneal scar (6.7%), PMD (2.2%), pathological myopia with aphakia (2.2%) and chronic blepharokeratoconjunctivitis (2.2%). Overall, mean visual acuity before using scleral lenses was LogMAR 0.59±0.32, which improved to 0.24±0.19 after using scleral lenses, which was statistically significant (p<0.001). Among individual etiologies, significant improvements in visual acuity was seen in patients with keratoconus, post radial keratotomy and SJS. Quality of life as assessed by Visual Function Questionnaire (VFQ-25) showed significant improvement in all the vision specific parameters like social functioning, mental health, role difficulties and dependency (p<0.001).

**Conclusion:** Scleral contact lenses are effective in the management of various degrees of irregular corneas of different etiologies which couldn't be managed with conventional lenses. These lenses have become a useful tool in ocular surface abnormalities as a protective interface in addition to providing significant improvement in visual acuity and quality of life. Thus scleral contact lenses have emerged as an effective option as well as a bridge to prevent or postpone surgeries and their associated irreversible complications.

**Key words:** scleral lenses; therapeutic lenses; visual acuity; irregular cornea; quality of life

## INTRODUCTION

Scleral lenses were actually the first contact lenses described in medical literature in the late 1800's. Adolf Fick first described use of blown glass "vesicles" in 1888. Eugene Kalt demonstrated improvement of vision in a patient with

keratoconus with glass "contact shell". In 1889 August Mueller used ground glass lenses to correct his own high myopia. Although these early lenses did improve vision, the manufacturing process necessary to create these early lenses was challenging,

and wearing the lenses caused symptoms of oxygen deprivation. [1]

In the mid-1900's, corneal contact lenses were introduced. The lenses were easier to fit than scleral lenses. Development of corneal lenses with rigid gas permeable materials reduced complications related to lack of oxygen to the cornea. When hydrogel (soft) lens materials were introduced in the 1960's and 1970's, demand for contact lenses as a means for correcting vision increased even further. [1]

In spite of the vast improvements in both corneal rigid gas permeable lenses and hydrogel lenses, several eye care providers saw a continued need for large-diameter lenses. Originally scleral contact lenses were primarily used for severely compromised eyes. Corneal ectasia and exposure conditions were the primary indications. However, currently these are used for managing less severe and even non-compromised eyes. [2]

Use of Scleral contact lenses can be broadly divided into two major indications [3]

1. Vision improvement
  - a. Primary ectasia - keratoconus, keratoglobus and pellucid marginal degeneration
  - b. Secondary ectasia - post-refractive surgery (post-laser assisted in-situ keratomileusis, post-laser assisted epithelial keratoplasty, post

photorefractive keratectomy and postradial keratotomy

## 2. Corneal protection

- Stevens-Johnson syndrome, graft versus host disease, ocular cicatricial pemphigoid, neurotrophic corneal disease, atopic keratoconjunctivitis, Sjögren's syndrome, persistent epithelial corneal defects.

More recently, scleral contact lenses have also been applied to deliver pharmaceuticals to the anterior surface. [3]

The present retrospective study was conducted to evaluate the indications and efficacy of semi and mini scleral contact lenses.

## MATERIALS AND METHODS

A total database of 38 consecutive patients fitted with semi scleral or mini scleral lenses between January 2015 and December 2016, was retrospectively analyzed to determine the indications for lens fitting and visual outcomes.

These patients had been referred to the contact lens clinic at Sankara Eye Hospital - Bangalore, due to severe corneal irregularities or corneal surface disorders.

Ocular pathologies included: keratoconus, pellucid marginal degeneration (PMD), post radial keratotomy, Stevens-Johnson syndrome, post traumatic corneal scars, chronic blepharokerato conjunctivitis and high refractive errors.

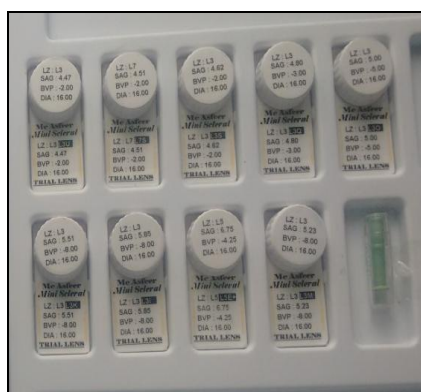

Figure 1: Miniscleral Lens

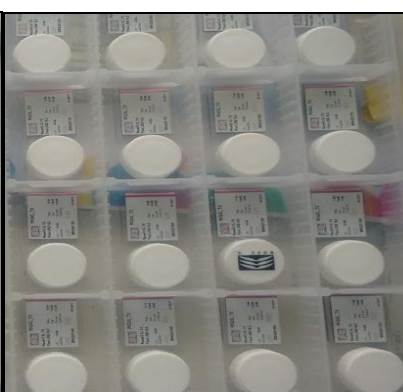

Figure 2: Semiscleral Lens

All lenses were fitted by a preformed technique. The following semiscleral and mini scleral lenses were used.

- Miniscleral Lens- Pureconlenses (Hesafocon B) of diameter 15-18 mm made of fluorosilicon acrylate

of oxygen permeability 161 (Figure 1).

- Semiscleral Lens – Rose K2 XL of diameter 13.6-15.6 mm made of Manicon Z, Boston XO, Optimum Extra (Figure 2).

**Successful scleral contact lens wear was confirmed with fluid venting test.**

*Fluid-Venting Test Procedure* – After placing the contact lens on the eye with sterile saline and keeping it in position for at least 2 hours, fluorescein dye was instilled. After 5 minutes, a slit lamp examination with cobalt blue filter or optic section was performed. In cases where fluorescein diffused under the lens haptic and reached the pre-corneal liquid chamber spontaneously or by gentle palpation, the

test was considered positive (Figure 3). If no fluorescence was seen – the test was considered negative. A Positive fluid venting test correlates well with successful scleral contact lens wear.

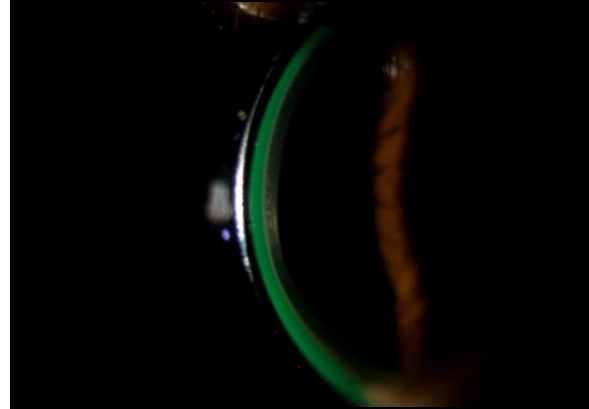

Figure 3: Positive Fluid-Venting Test

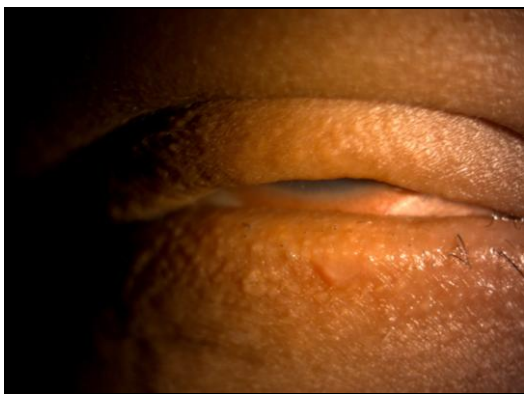


Figure 4: Before fitting scleral contact lens

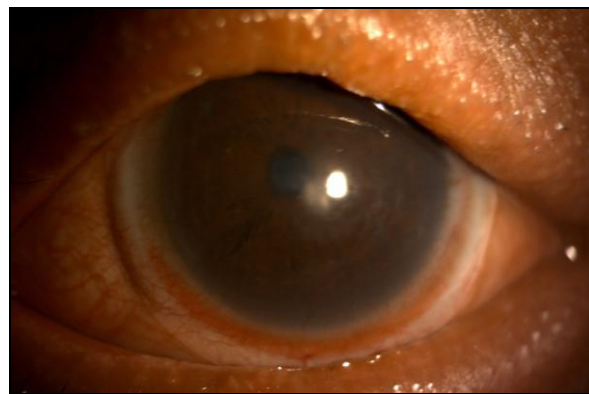

Figure 5: After fitting scleral contact lens

Figure 4: Extreme photophobia and irritation in patient with SJS – before fitting scleral contact lens. Figure 5: Symptomatic relief after scleral contact lens wear.

Best manifest refraction at consultation, and contact lens, at dispensing, visual acuities were recorded in the decimal equivalent of the Snellen ratio.

National Eye Institute Visual Function Questionnaire (VFQ-25) [4] was used to measure quality of life. Vision specific parameters like social functioning, mental health, role difficulties and dependency was assessed and scored before and after scleral contact lens wear for a minimum of 4 months.

**Statistical Analysis:**

Descriptive statistics were calculated initially. The mean, standard deviation, minimum and maximum statistics were derived for continuous parameters and proportion statistics were calculated for categorical data parameters. Paired sampled t-test was used to compare the preoperative versus postoperative parameters. Wilcoxon-signed rank test was used to compare the preoperative versus postoperative non-normally distributed data. A two-sided p value less than 0.05 was considered to be statistically significant. All analysis was carried out by using the SPSS 17.0 version (SPSS, Chicago, IL, USA) software for windows.

**RESULTS**

Majority of the patients (79%) were male (Table 1). Maximum (34.2%) cases were seen in the age group 21 to 30 years followed by the 31 to 40 years group (31.6%) [Graph 1]. Mini-scleral lens was inserted in 82% of patients (Table 2) and rest 18% received Semi scleral lenses. 31 patients had scleral contact lens fitted for one eye and 7 patients for both eyes.

**Table 1: Distribution of Patients by SEX**

| SEX    | Number | %    |
|--------|--------|------|
| Male   | 30     | 78.9 |
| Female | 8      | 21.1 |

**Table 2: Type of Lens**

| Type of Lens | Number | %    |
|--------------|--------|------|
| Mini Scleral | 37     | 82.2 |
| Semi Scleral | 8      | 17.8 |

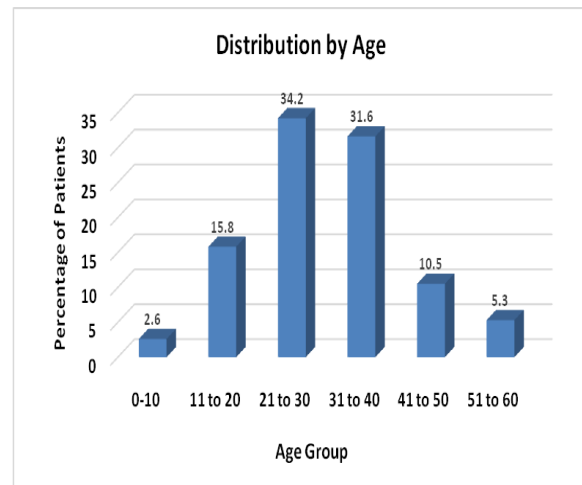
Major Indications for the use of scleral contact lens included keratoconus– 24 eyes (53.3%), followed by post Radial Keratotomy – 8 eyes (17.8%), Steven Johnson Syndrome – 7 eyes (15.6%), corneal scar – 3 eyes (6.7%), PMD – 1 eye (2.2%); pathological myopia with aphakia –

**Table 3: Improvement in visual acuity after scleral contact lens**

|      | Mean   | N  | Std. Deviation | Std. Error Mean | Sig  |
|------|--------|----|----------------|-----------------|------|
| Pre  | 0.5924 | 45 | .32461         | .04839          | .001 |
| Post | 0.2467 | 45 | .19725         | .02940          |      |

In the Keratoconus group, mean best spectacle corrected visual acuity before fitting contact lenses was  $0.61 \pm 0.31$ . Visual acuity improved to  $0.20 \pm 0.16$  after fitting scleral lenses which was statistically significant ( $p < 0.01$ , Wilcoxon signed rank

1 eye (2.2%) and chronic blepharokeratoconjunctivitis (2.2%).



**Graph 1: Distribution of Patients by Age**

**Visual Outcomes:**

Best Corrected Visual Acuity before and after fitting scleral contact lens was compared and analyzed. Mean best spectacle corrected visual acuity (VA) before fitting scleral contact lenses was  $0.59 \pm 0.32$ . After fitting scleral contact lenses, there was significant improvement in VA to  $0.24 \pm 0.19$  ( $p < 0.01$ , paired t test) [Table 3].

test). Significant improvements in visual acuity were also seen in patients with Post Radial Keratotomy ( $p < 0.041$ , Wilcoxon signed rank test) and Stevens- Johnsons Syndrome ( $p < 0.026$ , Wilcoxon signed rank test).

**Table 4: Best Corrected Visual Acuity, Before and After Fitting Contact Lens**

| Etiology                       |      | Mean (LogMAR) | N  | Std. Deviation | Std. Error Mean |
|--------------------------------|------|---------------|----|----------------|-----------------|
| Keratoconus                    | Pre  | .6192         | 24 | .31554         | .06441          |
|                                | Post | .2000         | 24 | .16940         | .03458          |
| Post Radial Keratotomy         | Pre  | .4750         | 8  | .33274         | .11764          |
|                                | Post | .2750         | 8  | .21213         | .07500          |
| Steven Johnsons Syndrome       | Pre  | .5571         | 7  | .39940         | .15096          |
|                                | Post | .3571         | 7  | .25728         | .09724          |
| Post traumatic Corneal opacity | Pre  | .8333         | 3  | .28868         | .16667          |
|                                | Post | .3333         | 3  | .23094         | .13333          |
| Others*                        | Pre  | .5333         | 3  | .25166         | .14530          |
|                                | Post | .2000         | 3  | .17321         | .10000          |

\* Others included Pellucid Marginal Degeneration, chronic blepharokeratoconjunctivitis and pathological myopia with aphakia, one patient each.



Though improvement in mean best spectacle corrected visual acuity was seen in patients with post traumatic corneal opacity, the difference was not statistically significant ( $p = 0.109$ , Wilcoxon signed rank test). Similar results were seen in the patients with PMD, chronic blepharokeratoconjunctivitis and pathological myopia with aphakia.

### Improvement in Quality of Life

Response to vision specific parameters of VFQ25 questionnaire, before and after fitting scleral contact lens was available for 16 patients. There was significant improvement in scores ( $p < 0.001$ ) of all the assessed vision specific parameters including social functioning, mental health, role difficulties and dependency [Table 4].

**Table 4: Improvement in vision specific parameters of VFQ25**

| Parameter         | SCL use | Mean Score | Std. Deviation | Std. Error Mean | Sig     |
|-------------------|---------|------------|----------------|-----------------|---------|
| Social function   | Before  | 46.8750    | 18.54050       | 4.63512         | < 0.001 |
|                   | After   | 98.4375    | 4.26956        | 1.06739         |         |
| Mental health     | Before  | 50.0000    | 21.28673       | 5.32168         | < 0.001 |
|                   | After   | 100.0000   | .00000         | .00000          |         |
| Role difficulties | Before  | 26.5625    | 28.09026       | 7.02256         | < 0.001 |
|                   | After   | 96.8750    | 8.53913        | 2.13478         |         |
| Dependency        | Before  | 55.7250    | 21.89205       | 5.47301         | < 0.001 |
|                   | After   | 100.0000   | .00000         | .00000          |         |

### Complications

Three patients (8%) developed corneal infiltration, among them one also developed afocal scleral abscess. Cultures were positive in one patient which showed growth of klebsiella species.

### DISCUSSION

This retrospective study demonstrates medical applications of semi and mini scleral contact lenses for managing a range of complicated corneal and ocular surface conditions for which treatment by other methods is either unsuitable or less effective.

The Indications for the use of scleral contact lenses may be categorized into four main groups: primary or induced keratectasia post penetrating keratoplasty, ocular surface diseases and high refractive errors. In the present study, patients with keratoconus formed the largest group (55%), followed by Post Radial Keratotomy (16%) and Stevens- Johnsons Syndrome (13%).

An improvement in VA was the primary indication for fitting scleral contact lenses in nearly 87% of the fitted eyes, and was achieved in most instances by neutralizing the corneal irregularities or correcting existing refractive errors.

Visual outcomes varied according to the preexisting ocular status. The best visual results were obtained in patients with keratoconus, post Radial Keratotomy and Stevens- Johnsons Syndrome which were statistically significant. For other conditions like corneal scar, PMD, pathological myopia with aphakia and chronic blepharokeratoconjunctivitis, though improvement was seen, it was found to be statistically insignificant.

Quality of life assessment for vision specific improvements done using VFQ25 showed significant improvement in all the assessed parameters which included social functioning, mental health, role difficulties and dependency. Quality of life improvement was more significant in patients with ocular surface disorders such as Stevens- Johnsons Syndrome when compared with the other groups.

### Review and comparison with published studies

A Study by Tan et al, analyzed the outcomes of scleral contact lenses in various indications in 517 eyes of 343 patients during a 5-year period. In this study, the major indication for scleral contact lens use was for vision correction (94%) which includes keratoconus, aphakia, post-penetrating keratoplasty, irregular

astigmatism secondary to corneal disease and high myopia. [5]

In a similar study by Segal o et al, Keratoconus was the major indication (75% of cases) for scleral contact lenses, followed by extreme corneal irregularity after penetrating Keratoplasty and non healing corneal ulcer. [6]

Results of our study are in agreement with earlier published indications for scleral contact lenses. As in previous studies, keratoconus was the most common indication. Keratoconus patients are commonly adolescents or young adults and may require corneal surgery during their lifetime. The risks associated with the keratoplasty procedure, which include infection, rejection, and severe astigmatism, may be greater than those attributed to scleral contact lens wear. [7]

Our study concurred with other reports in improvement of the visual acuity in patients with irregular or severe astigmatic topography. Studies that included indications other than visual correction, as in the treatment of ocular surface disease for example, showed less significant improvement in VA. The reason for sub optimal visual results in this group was that the aim of fitting scleral lenses in these cases was primarily therapeutic, aimed at corneal protection, tear conservation, or pain relief. [8-11]

A Study by Picot et al [12] demonstrated improvement in quality of life in patients wearing scleral lenses and our study also showed similar results. When compared with earlier study which evaluated quality of life improvement in few conditions like keratoconus and keratoplasty, our study evaluated improvements in variety of ocular surface disorders including keratoconus, post Radial Keratotomy, Stevens- Johnsons Syndrome, corneal scar, PMD, chronic blepharokeratoconjunctivitis etc.

## CONCLUSION

Scleral contact lens (GP-SCL) can provide visual and therapeutic benefits

primarily in ocular surface disorders and corneal astigmatism in which conventional management may not provide desired benefits. The main indication for scleral contact lens is optical correction of an irregular corneal surface, especially due to keratoconus. In the keratoconus group, scleral contact lens serves as an alternative to surgery. In the post-PKP group GP-SCL provided an alternative to refractive surgery or repeat corneal transplantation. Scleral lenses were found to be beneficial in several forms of ocular surface diseases. Therapeutic benefits of GP-SCL enhance the management of ocular surface diseases when medical treatments have failed and surgery is undesirable. Our study highlights the tremendous benefits of scleral contact lenses in a range of indications, providing visual benefits and /or ocular comfort and significantly improving the quality of life in these patients. Scleral lenses are a valuable addition to our management protocols for keratoconus and other conditions.

## ACKNOWLEDGEMENT

We would like to thank Dr. S. Krishnaiah, statistician, Sankara eye hospital, Bangalore for helping in devising statistical analysis plan and analyzing data. We are grateful to Dr. Jeena Mascarenhas, Senior Consultant, Goa for reviewing the manuscript and providing expert guidance. We also thank Department of contact lens clinic, Sankara eye hospital, Bangalore for their help extended towards the study.

## REFERENCES

1. Scleral Lens Education Society. A Brief History of Scleral Lenses[Internet]. 2017 [cited: 2017 Aug 26]. Available from: <http://www.sclerallens.org/history>
2. Van der Worp E, Bornman D, Ferreira DL, Faria-Ribeiro M, Garcia-Porta N, González-Meijome JM. Modern scleral contact lenses: A review. *Cont Lens Anterior Eye*. 2014 Aug;37(4):240-50.
3. Nidhi Gupta, Minal Kaur, Abhilek. Scleral Contact Lenses. *Delhi J Ophthalmol* 2013; 24 (1): 51-57
4. National Eye Institute Visual Functioning Questionnaire – 25 [Internet]. 2000 [cited: 2017 Nov 30].

- Available from:  
[https://nei.nih.gov/sites/default/files/nei-pdfs/vfq\\_ia.pdf](https://nei.nih.gov/sites/default/files/nei-pdfs/vfq_ia.pdf)
5. Tan DTH, Pullum KW, Buckley RJ. Medical applications of scleral contact lenses: A retrospective analysis of 343 cases. *Cornea* 1995; 14:121-9.
  6. Segal O, Barkana Y, Hourovitz D, Behrman S, Kamun Y et al. Scleral contact lenses may help where other modalities fail. *Cornea* 2003; 22:308-10.
  7. Stechschulte SU, Azar DT. Complications after penetrating keratoplasty. *Int Ophthalmol Clin*. 2000;40:27-43
  8. J Pecego M, Barnett M, Mannis MJ, Durbin-Johnson B. Jupiter Scleral Lenses: the UC Davis Eye Center experience. *Eye Contact Lens* 2012; 38:179-82.
  9. Romero-Rangel T, Stavrou P, Cotter J, Rosenthal P, Baltatzis S, Foster CS. Gas-permeable scleral contact lens therapy in ocular surface disease. *Am J Ophthalmol* 2000; 130:25-32.
  10. Rosenthal P, Cotter JM, Baum J. Treatment of persistent corneal epithelial defect with extended wear of a fluid-ventilated gaspermeable scleral contact lens. *Am J Ophthalmol* 2000; 130:33-41.
  11. Jacobs DS, Rosenthal P. Boston scleral lens prosthetic device for treatment of severe dry eye in chronic graft-versus-host disease. *Cornea* 2007; 26:1195-9.
  12. Picot C et al. Quality of life in patients wearing scleral lenses. *J Fr Ophtalmol*. 2015 Sep;38(7):615-9

How to cite this article: Preethi CA, Joshi P, Umesh Y. Clinical applications and therapeutic outcomes of scleral contact lenses - a retrospective study. *Int J Health Sci Res*. 2018; 8(2):60-66.

\*\*\*\*\*