

Case Report

Cutaneous Anaplastic Meningioma: A Rare Case

Dr Rajesh Y Shenoy¹, Dr C S Supreeth², Dr Darshan Rajput³,
Dr Kumar Vinchurkar⁴

¹Professor & Consultant Neurosurgeon, JNMC College Belgaum.

²Neurosurgery Resident, JNMC College Belgaum.

³Professor & Consultant Plastic Surgeon, JNMC College Belgaum.

⁴Professor & Consultant Oncosurgeon, JNMC College Belgaum.

Corresponding Author: Dr C S Supreeth

ABSTRACT

Meningiomas are common benign intracranial tumors, but may show a histological progression to malignancy. They rarely present as extracranial soft tissue mass. Compared to benign, anaplastic meningiomas have a significantly higher recurrence rate after both surgical and radiotherapy managements. We present a patient with intracranial anaplastic meningioma that presented as a mass on the scalp. He also gives history of operation for meningioma 4 years back. Near total excision was done and part of it was left which was involving superior sagittal sinus. On examination patient also had enlarged bilateral neck lymph nodes. Patient underwent CT and MRI brain plain with contrast, showed a large heterogeneously enhancing extra axial mass lesion suggestive of high grade cellular lesion. Complete excision of the growth with left side modified radical neck dissection and the defect was covered with anterolateral thigh free flap, along with onco and plastic surgery team. postoperatively patient was conscious, oriented and ambulatory with no neurological deficits. postoperative MRI brain with contrast showed no evidence of mass.

Key words: Cutaneous anaplastic meningioma, Meningioma.

INTRODUCTION

Meningiomas are common benign intracranial tumors, but may show a histological progression to malignancy. These neoplasms account for 24-30% of primary intracranial tumors. The mechanisms of malignant transformation remain unclear and rarely present as extracranial soft tissue

Mass^[1] as they may be associated with intracranial lesions, intracranial masses should also be investigated in patients presenting with cutaneous meningioma of the scalp. The WHO classifications defined the subtype atypical and anaplastic neoplasms as grade II and III meningiomas.^[2,3] Surgical resection is considered to be the best treatment for most patients with

meningioma.^[4] Compared to WHO grade I meningioma, WHO grade II and III meningiomas have a significantly higher recurrence rate after both surgical and radiotherapy managements.^[3]

In the current case report, we present a patient with intracranial anaplastic meningioma that presented as a mass on the scalp.

CASE REPORT

A 53 year male, presented with history of large ulceroproliferative, foul smelling growth over the scalp for the past 5months, slowly progressing in nature. He also complained of hemicranial headache, present throughout the day. Relatives also noticed aggressive behaviour since 2

months. He gave history of operation for meningioma 4 years back. Near total excision was done and part of it was left which was involving superior sagittal sinus. On examination patient also had enlarged bilateral neck lymph nodes. Patient underwent CT and MRI brain plain with contrast which showed a large heterogeneously enhancing extra-axial mass/lesion with irregular margins, significant extra calvarial spread and mushrooming into the brain parenchyma in the temporal and parietal regions. On MRS, significant choline, lipid and lactate peaks with near total dampening of NAA, Cr, Mi

peaks were seen. The mean ADC value $[0.5-0.8 \times 10^{-3} \text{mm}^2/\text{s}]$ was suggestive of high grade cellular lesion. Complete excision of the growth with left side modified radical neck dissection was done and the defect was covered with anterolateral thigh free flap, along with oncosurgery and plastic surgery team. Postoperatively, patient was conscious, oriented and ambulatory with no neurological deficits. Postoperative ct brain showed no evidence of mass. Histopathology confirmed the lesion as anaplastic meningioma-WHO grade III scalp. Three of six from level III lymph nodes were involved by tumour.

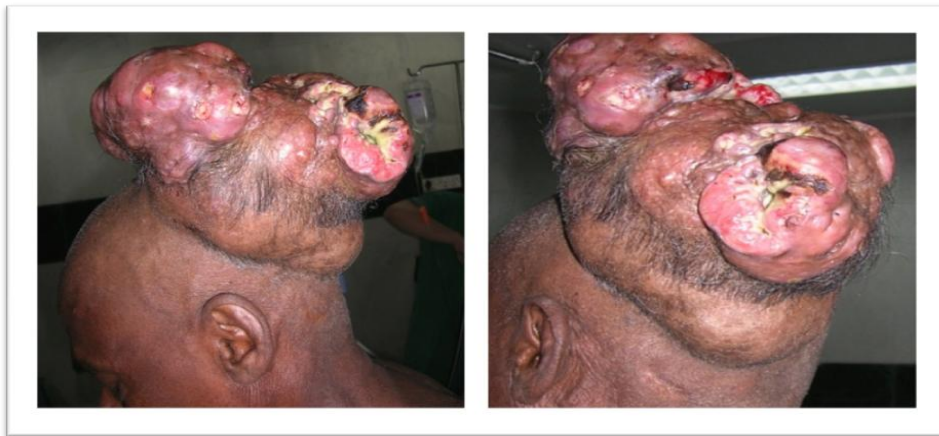

Fig 1:preoperative mass.

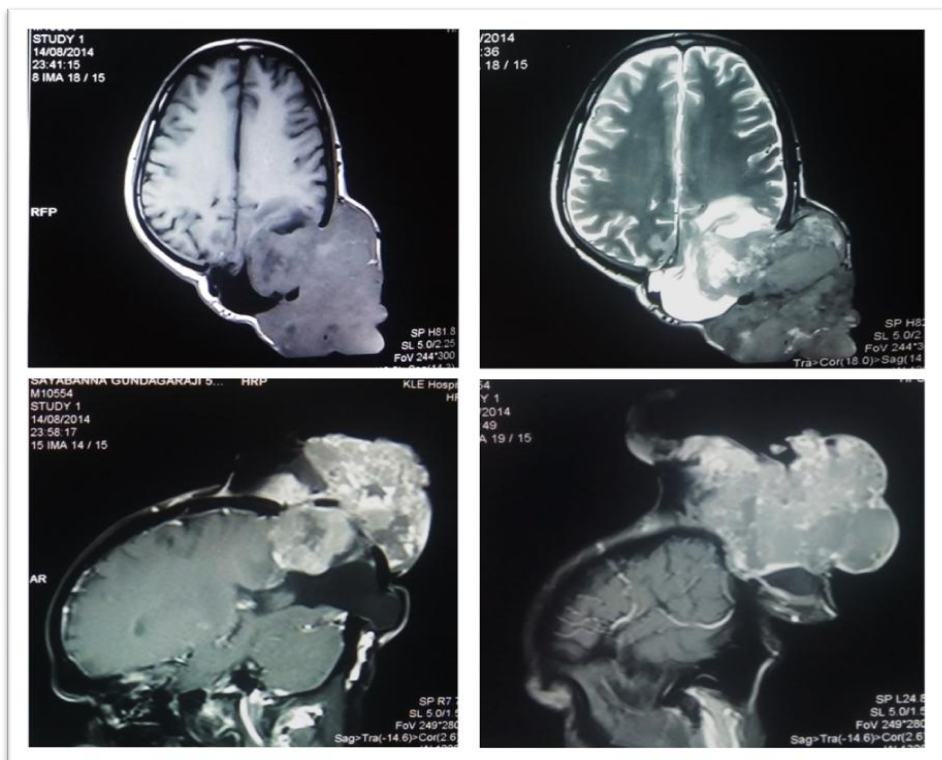


Fig 2:preoperative MRI with contrast.

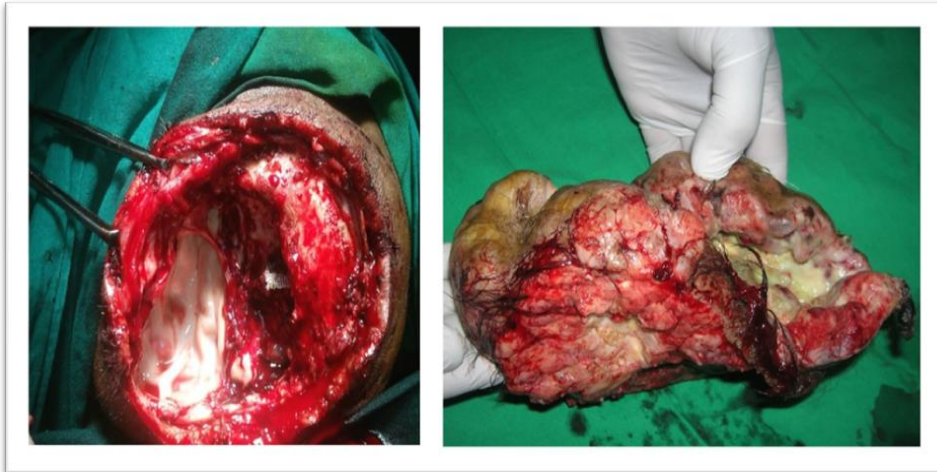

Fig 3:Intra operative complete excision of tumor.

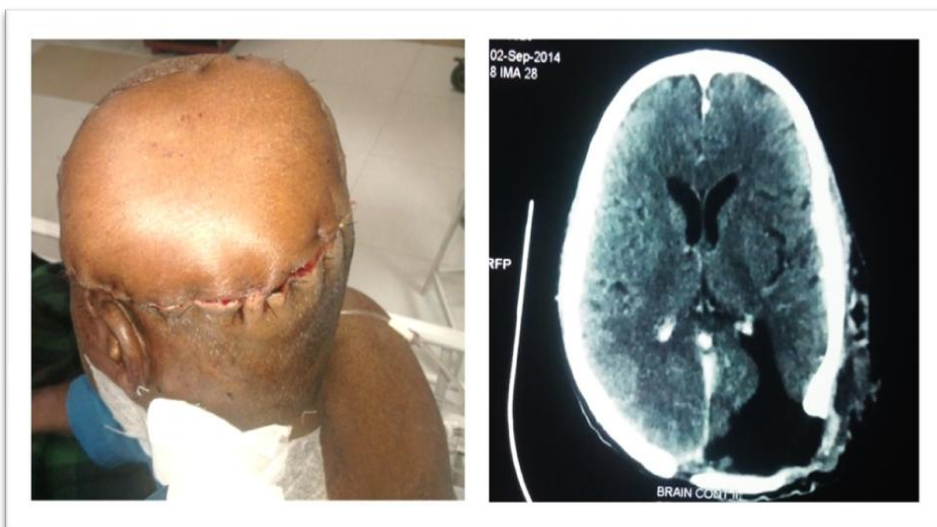


Fig 4: Postoperative picture showing free thigh flap.

DISCUSSION

Arachnoid cells (arachnoid granulations, meningiocytes, meningotheelial cells, pacchionian bodies) are thought to arise from neural crest. They normally line the inner aspect of the arachnoid membrane, and fill the cores of the arachnoid villi that project into the lumens of dural veins and venous sinuses. Increasing evidence supports the development of meningiomas from arachnoid cap cells, with different mechanisms to suggest how extracranial meningiomas arise:

1. Arachnoidal cells are present in the sheaths of nerves or vessels where they emerge through the skull foramina.
2. Displaced pacchionian bodies become detached, pinched off, or entrapped

during embryologic development in an extracranial location.

3. A traumatic event or cerebral hypertension that displaces arachnoid islets.

An origin from undifferentiated or multipotential mesenchymal cells, such as fibroblasts, Schwann cells, or a combination of these, perhaps explains the diverse pathologic spectrum found in meningiomas. Consequently, by one mechanism or another, arachnoid cells are identified outside the neuraxis and give rise to meningiomas in extracranial locations, including ear, sinonasal tract, scalp and soft tissues. [4,5] The majority of meningiomas are benign. However, atypical and anaplastic meningiomas are more aggressive, especially anaplastic

meningiomas, which are rare but bear a high recurrence rate and unfavourable prognosis. [3] Because meningiomas originate from the arachnoid villi, the location of tumor mass can be in any part of skull. [7] Thus, the symptoms can be various accordingly, including headache, seizure, hemiparesis, and even cranial neuropathy such as vision loss. [8] Meningiomas are usually located in the skull vault and the skull base; to be specific, the parasagittal area is the most frequent, followed by the falx, the cavernous sinus, the tuberculum sellae, the lamina cribrosa, the foramen magnum, and the torcular zones. [9] Parasagittal meningiomas make up 17% to 20% of all the subtypes and most often involve the frontal lobe. [4] They can be asymptomatic for a long time and grow to a considerable size. And when the symptoms show, jacksonian seizures of the lower limbs and headache are most apparent. If the meningioma advance, papilledema and homonymous hemianopia may occur. [10] There is more serious situation that tumor mass can invade directly into the posterior segment of eye and terminate its vision.

Up to 20% of intracranial meningiomas may have extraneuraxial extension, [6-8] including the skull, scalp (all cutaneous sites), orbit, upper airway involvement (nasal cavity, paranasal sinuses, nasopharynx), soft tissues, and ear and temporal bone. However, when the scalp, orbit, sinonasal tract, oral cavity, and soft tissues are excluded, the incidence decreases to less than 1%. [8] It is important to exclude an intracranial component radiographically or during surgery to yield the best possible management and follow-up. The possibility of an intracranial tumor must always be considered if long term management is to achieve its intended goal. [6,9]

In general, the prognosis of extracranial meningiomas appears to be excellent, with an overall median survival of 28 years. This is tempered by the specific anatomic site, histologic type, tumor grade, gender, and age of the patient. The

recurrence rate for meningiomas after total excision varies from 7% to 84% depending upon the number of years of followup. [10,8,11] This is similar to intracranial meningiomas which have a recurrence rate of up to 20% and a mean survival around 7 years. [11,12]

While surgery is the treatment of choice, there are a number of challenges due to the invasiveness of the tumors and the complexity of the anatomy within the sinonasal tract and ear and temporal bone, although scalp and soft tissues lesions are no less difficult to remove if they are adjacent to vital structures. It may be necessary to utilize a multidisciplinary approach with a combination of intracranial, temporal bone, maxillofacial, and skull base techniques to achieve total resection, possibly including widely exenterative procedures to achieve this end. [6] Radiation therapy has been suggested to yield a possible improvement in survival in meningiomas of the central nervous system. [10]

REFERENCES

1. Fung MA, Grekin RC, Odom RB. Intracranial malignant meningioma mimicking frontalis-associated lipoma of the forehead. *J Am Acad Dermatol.* 1996; 34: 306-7.
2. Moradi A, Semnani V, Djam H, Tajodini A, Zali AR, Ghaemi K, Nikzad N, Madani-Civi M. Pathodiagnostic parameters for meningioma grading. *J Clin Neurosci.* 2008;15:1370-1375.
3. Durand A, Labrousse F, Jouvet A, Bauchet L, Kalamarides M, Menei P, Deruty R, Moreau JJ, Fevre-Montange M, Guyotat J. WHO grade II and III meningiomas: a study of prognostic factors. *J Neurooncol.* 2009;95:367-375.
4. Chang CY, Cheung SW, Jackler RK. Meningiomas presenting in the temporal bone: the pathways of spread from an intracranial site of origin. *Otolaryngol Head Neck Surg.* 1998;119:658-664. doi: 10.1016/S0194-5998(98)70030-0.
5. Batsakis JG. Pathology consultation. Extracranial meningiomas. *Ann Otol Rhinol Laryngol.* 1984;93:282-283.

6. Friedman CD, Costantino PD, Teitelbaum B, Berktold RE, Sisson GA., Sr Primary extracranial meningiomas of the head and neck. *Laryngoscope*. 1990;100:41–48.10
7. Nager GT, Heroy J, Hoeplinger M. Meningiomas invading the temporal bone with extension to the neck. *Am J Otolaryngol*. 1983;4:297–324. doi: 10.1016/S0196-0709(83)80018-0. 14
8. Thompson LD, Bouffard JP, Sandberg GD, Mena H. Primary ear and temporal bone meningiomas: a clinicopathologic study of 36 cases with a review of the literature. *Mod Pathol*. 2003;16:236–245. doi: 10.1097/01.MP.0000056631.15739.1B 19
9. Batsakis JG. Pathology consultation. Extracranial meningiomas. *Ann Otol Rhinol Laryngol*. 1984;93:282–283.8
10. Maniglia AJ. Intra and extracranial meningiomas involving the temporal bone. *Laryngoscope*. 1978;88:1–58 13
11. Civantos F, Ferguson LR, Hemmati M, Gruber B. Temporal meningiomas presenting as chronic otitis media. *Am J Otol*. 1993;14:403–406. 25
12. Louis DN, Ohgaki H, Wiestler OD, Cavenee WK. World Health Organization classification of tumours of the central nervous system. 4. Lyon: IARC Press; 2007. 1

How to cite this article: Shenoy RY, Supreeth CS, Rajput D et al. Cutaneous anaplastic meningioma: a rare case. *Int J Health Sci Res*. 2018; 8(1):283-287.
