

# Association between Sella Turcica Bridging and Canine Impaction in Skeletal Class III Malocclusion

Dr. Rasitha V<sup>1</sup>, Dr. Dharma RM<sup>2</sup>, Dr Manjunath Hegde<sup>3</sup>

<sup>1</sup>Post Graduate, <sup>2</sup>Professor and HOD, <sup>3</sup>Reader,  
DAPM RV Dental College, Bangalore

Corresponding Author: Dr. Rasitha V

## ABSTRACT

**Objective of study:** The association of sella turcica bridging and various dental anomalies has been an area of interest for researchers. The objectives of this study is to test whether an association exist between sella turcica bridging and canine impaction in skeletal class III malocclusion

**Methodology:** Orthodontic records comprising standard quality lateral cephalograms and dental panoramic radiographs were selected. Twenty cases with skeletal class III malocclusion and canine impaction (mean age 15.2 yrs) and twenty controls with skeletal class III, without canine impaction (mean age 14.7 yrs) were included in the study. Skeletal class III were selected based on ANB  $< -1^{\circ}$ , Wits appraisal  $< -2\text{mm}$  and  $\beta > 35^{\circ}$  angle and canine impactions were selected based on sector analysis, power and short analysis. Comparison and association of sella turcica bridging and canine impaction was carried out by chi -square test and Odds ratio.

**Results:** The frequency of partial and complete calcification in study groups were 80% , where as in controls more than 55% are without calcification which shows it is a statistically significant ( $p=0.02$ ) result .The odds ratio of partial and complete bridging among study group was 5 times greater than controls shows strong association.

**Conclusion:** The result of this study shows that there is a strong association between sella turcica bridging and canine impaction in skeletal class III malocclusions. Hence sella bridging can be used as a diagnostic parameter for canine impactions.

**Keywords:** Sella Turcica Bridging, Canine Impaction, Skeletal Class III Malocclusion

## INTRODUCTION

The sella turcica is an important structure in radiographic analysis of the neurocranial and craniofacial complex. The sella turcica is situated on the intracranial surface of the body of the sphenoid bone. The anterior border of the sella turcica is represented by the tuberculum sellae and the posterior border by the dorsum sellae. [1-3] The pituitary gland is surrounded by the sella turcica, whereas two anterior and two posterior clinoid processes project over the pituitary fossa. During embryological development, the sella turcica area is a key point for the migration of the neural crest

cells to the frontonasal and maxillary developmental fields. [4-6]

The morphology of the sella turcica is accordingly important, not only in evaluating cranial morphology, but also when later growth changes and treatment results are to be evaluated. [7]

Sella turcica has a major importance in the field of orthodontics. The anterior contour of sella turcica is useful in predicting patient growth and in assessing the craniofacial morphology and superimposing serial cephalograms. [8-10] Orthodontists should be familiar with the morphologic variations of sella turcica that will aid in diagnosing any underlying

pathologies associated with it. One common morphologic variation of sella turcica is the Sella Bridge. [11]

Exaggerated ossification of the duramater between the anterior and posterior clinoidal processes of the sphenoid bone or abnormal embryologic development of the sphenoid bone results in irregular bridge formation. The association of sella turcica bridging and various dental anomalies has been an area of interest for researchers. since sella bridging is considered as a developmental and genetic anomaly, variations in the genetic makeup of different populations might lead to different results. [12-14]

A statistically higher incidence of sella bridging was found in Individuals with skeletal class III compared with class I and II malocclusions. [15,16] Association of sella turcica bridging and maxillary canine impactions showed positive results on a study done in Pakistani population. Hence to establish authentic results, the findings of previous studies need to be replicated in different populations with varying racial backgrounds.

## MATERIALS AND METHODOLOGY

### SUBJECTS

#### Study population

The clinical records of 20 subjects (12 females, 8 males, mean age 15.2 yrs, SD  $\pm 2.1$  yrs) was collected from department of orthodontics and dento facial orthopedics.

The inclusion criteria were,

- 1) Skeletal class III jaw base
- 2) Maxillary canine impaction

The exclusion criteria were,

- 1) Skeletal class I and II jaw base
- 2) Subjects with erupted canines
- 3) Age  $\leq 13$  yrs
- 4) History of cleft lip/palate, syndromes
- 5) Severe craniofacial deviations
- 6) Multi reagent chemotherapy

#### Controls

The control group comprised of another 20 subjects (9 females, 11 males, mean age 14.7 yrs, SD  $\pm 1.8$  yrs) who were randomly selected from those referred for

orthodontic treatment within the same departments during the previous 5 years.

The inclusion criteria were

- 1) Skeletal class III jaw base.
- 2) Erupted maxillary canines.

The exclusion criteria were

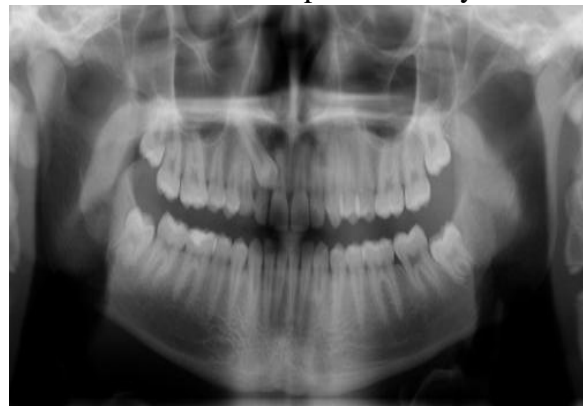- 1) Skeletal class I and II jaw base.
- 2) Canine impactions .Other criteria were similar to the study population.

Skeletal class III malocclusions were selected based on three cephalometric readings from lateral cephalogram.

- 1) ANB angle less than  $-1^\circ$
- 2) Wits appraisal less than  $-2$ mm
- 3)  $\beta$  angle more than  $35^\circ$

Fig1: Panoramic radiographs with maxillary canine impaction

Maxillary canine impaction were selected based on two canine impaction analysis



- 1) Sector analysis (Impacted canines which were in sector III and IV is selected because it is difficult for the canines in these sectors to come out without external force application)
- 2) Power and short analysis (inclination angle of canine to midline more than  $31^\circ$ )

Orthodontic records comprising of standard quality pre treatment panoramic radiographs (fig 1) and lateral cephalograms (fig2) were collected from department of orthodontics and dento facial orthopedics for diagnosing canine impactions and linear measurements of sella turcica.

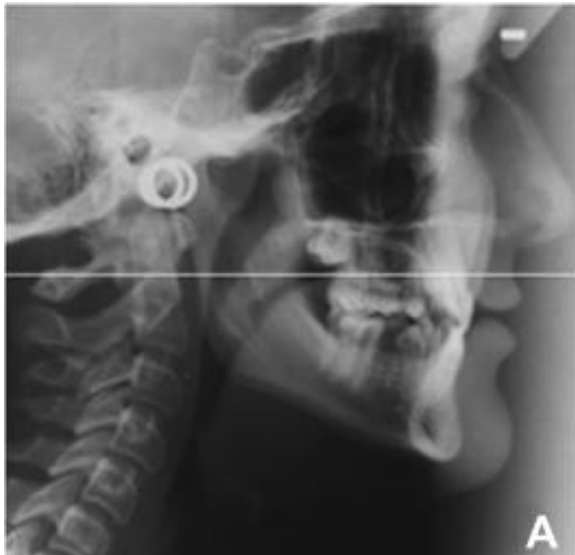

Fig 2: Lateral cephalograms of skeletal class III patients with canine impaction

### Cephalometric tracing of sella turcica

Only lateral cephalograms that had the clearest reproduction of the sella turcica were selected, in order to quantify the extent of a sella turcica bridge from each radiograph. The contour of the pituitary

fossa from the tip of the dorsum sella to the tuberculum sella was traced on ultra thin transparent acetate sheets using a Pentel 0.5mm lead pencil and measured manually by one observer. The sella turcica length and antero-posterior greatest diameter were measured. It should be emphasized that the length measurement is representative of inter clinoidal calcification, and as such, is not a real bone measurement but a measurement between calcified areas. All measurements were made to the nearest 0.1mm using a caliper. Sella turcica length and diameter were compared using a standardized scoring scale (Leonardi et al, 2006).<sup>[3]</sup> The greatest antero-posterior sella turcica diameter measurement was divided by four and the value obtained is compared with sella turcica length.

The linear dimensions of sella turcica is measured in the lateral cephalogram ([fig 3](#))

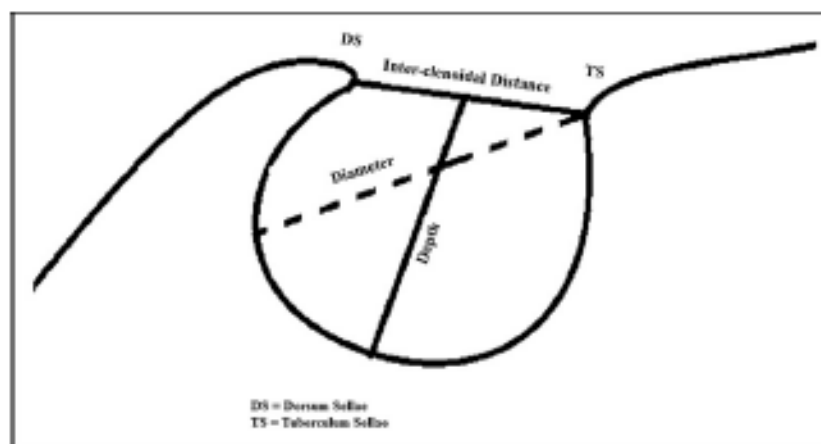


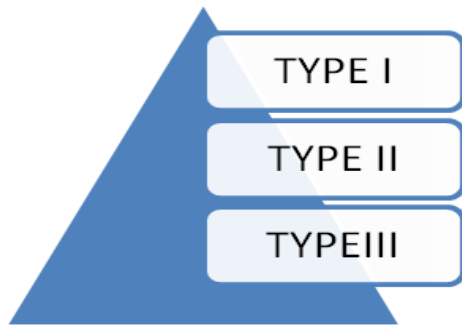
Fig 3: Linear dimensions of sella turcica 1) interclinoidal distance,2)sella depth,3)sella diameter

DS=DORSUM SELLAE  
TS=TUBERCULUM SELLAE

- 1) *Interclinoidal distance*: distance from the tip of the dorsum sellae to that of the tuberculum sellae.
- 2) *Depth of sella turcica*: distance of a line dropped perpendicular from the line above to the deepest point on the sella floor.
- 3) *Anteroposterior diameter of sella turcica*: distance from the tip of the tuberculum sellae to the farthest point on the inner wall of the hypophyseal fossa.

To evaluate and quantify the level of bridging, the standard scoring scale developed by Leonardi et al was used.<sup>[3]</sup>

The bridging was classified to 3 groups ([Fig 4](#)):



- 1) Type I/no calcification–length (interclinoid distance) equal to or more than diameter of sella
- 2) Type II/partial calcification-length less than  $\frac{3}{4}$  th of diameter
- 3) Type III/complete calcification –only diaphragm sella is visible.

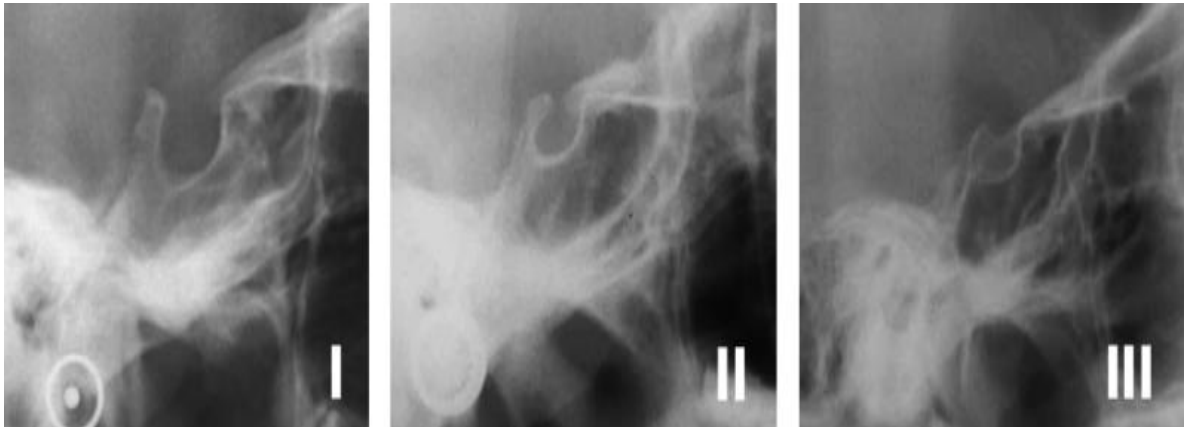


Fig 4: Type I [No calcification of interclinoid ligament (ICL)], type II (ICL partially calcified), and type III (ICL completely calcified)

### Reliability of the measurements

Duplicate tracings of 10 radiographs were made on two separate occasions by the same observer with a two week interval between tracings and the random error was assessed. Sella measurement error for length and diameter were considered minor as they ranged from 0.15 to 0.25mm.

### STATISTICAL ANALYSIS

SPSS (Statistical Package for Social Sciences, V.22, IBM, and Corp) software for windows is used for the statistical analysis of the data. Chi-square test was performed to test the degree of calcification in both groups and the strength of association between sella turcica bridging and skeletal class III jaw base with and without canine impaction was estimated by calculating odds ratio.

### RESULTS

#### According to the study results,

Out of 20 case samples, with skeletal class III and max canine impaction, 16 patients are having partial (type II) and

complete (type III) calcification and 4 patients are without bridging/calcification.

Type I calcification = 4

Type II calcification = 10

Type III calcification = 6

Out of 20 controls, skeletal class III and without canine impaction, 9 patients are with type II and type III calcification and 11 patients are without sella turcica bridging.

Type I calcification = 11

Type II calcification = 7

Type III calcification = 2

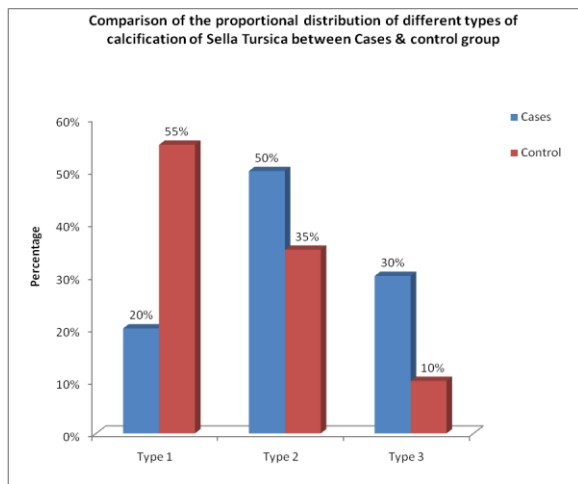
The statistical analysis compared the proportional distributions of different types of calcification in cases and controls using chi square test (Table 1 and graph 1). Type I calcification or without sella bridging in cases is only 20% and remaining 80%(type II is 50% and type III 30%) cases are with sella bridging, but in controls more than 55% are type I or without bridging and 45% are with sella turcica bridging (type II 35% and type III 10%). The chi square value is 5.227 and p value is 0.02 which means that there is significant difference in skeletal

class III patients with canine impaction and without canine impaction.

**Table 1: comparison of proportional distribution of types of calcification between cases & controls.**

Comparison of the proportional distribution of different types of calcification of Sella Turcica between Cases & control group using Chi Square test						
Sella Turcica	Cases		Control		x <sup>2</sup> Value	P-Value
	n	%	n	%		
Type 1	4	20%	11	55%	5.227	0.02 <sup>†</sup>
Type 2	10	50%	7	35%		
Type 3	6	30%	2	10%		

\*Statistically significant



**Graph 1: comparison of proportional distribution of different types of calcification of sella turcica between cases and control group.**

This graphical representation shows the comparison of proportional distribution of different types of calcification of sella turcica between cases and control group.

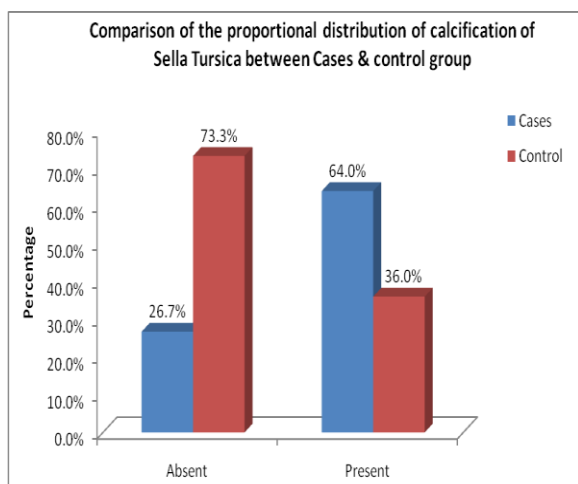
Type 1 calcification is seen at a highest frequency of 55% in controls and lowest frequency of 20% in cases. The highest frequency of type II calcification was reported 10 patients (50%). Type III calcification is seen at a frequency of 30% of the total case samples. In controls, only 10% of the patients are having type III calcification.

The strength of association between sella bridging and canine impaction was estimated by calculating odds ratio between cases and controls (table 2).

The odds ratio of presence of calcification among the cases was 4 to 5 times greater than in control group (Odds Ratio of 4.92, 95% confidence interval, Lower interval = 1.19, Upper interval = 19.94).

**Table 2: Estimation of odds ratio on distribution of calcification between cases and control.**

Comparison of the proportional distribution of calcification of Sella Turcica between Cases & control group							
Calcification	Cases		Control		OR	95% Conf. Interval	
	n	%	n	%		Lower	Upper
Absent	4	26.7%	11	73.3%	4.92	1.19	19.94
Present	16	64.0%	9	36.0%			



**Graph 2: comparing proportional distribution of calcification (Absent/Present) of sella Turcica between cases and control group**

Comparison of proportional distribution (graph 2) of calcification of sella turcica between cases and controls shows that 64% patients are with sella bridging in cases and only 26.7% are without sella bridging. In controls 73.3% patients are without bridging and 36% are with bridging. This shows that there is a strong association between sella bridging and canine impaction in skeletal class III patients.

## DISCUSSION

In this study we focused on the linear dimensions of sella turcica and the association of sella turcica bridging in

skeletal class III jaw base with maxillary canine impaction and without impaction. Altered morphology of anterior wall of sella, anterior clinoidal process, and sella length plays a pivotal role in bridge formation. True bony union occurs at an early age. [1-3]

The anterior part of sella turcica, the pituitary gland, and the dental epithelial progenitor cells share a common embryologic origin, which is the predominant derivative of neural crest cells. The sella turcica is the prime area for the migration of neural crest cells to maxillary, Palatinal, and frontonasal developmental fields. Alteration at the developmental level can result in a sella bridge that can simultaneously lead to impacted canines. [4,5]

According to this study, the interclinoidal distance is reduced in patients with impacted canines and skeletal class III malocclusion. A study conducted by Jones et al (2005) on a sample of fixed orthodontic and surgical –orthodontic patients showed a reduced sella length in the surgical orthodontic group. A study done in Caucasian individuals on bridging of sella turcica in class III patients found significantly higher rate of bridging in class III than class I patients. Kader (2007) found a higher percentage of sella turcica bridging in orthognathic-surgical patients with a skeletal class III malocclusion (10.71 per cent) as well as in orthodontic patients with a class III malocclusion (7.14 per cent). [6-9]

The result of this study also demonstrated an increased frequency of sella bridging in patients with skeletal class III and impacted canines. The 80 % frequency of partial and complete bridging in this study compared favorably with the 70% frequency reported by Najim and Nakib. The 30% frequency of complete calcification of sella in this study is higher than that reported by Leonardi et al, who found complete sella bridging in only 16.7% in their studies on palatally impacted canines. [3] Similarly, studies reported incidence of 16.7% in patients undergoing

combined surgical orthodontic treatment, 18.6% in patients with craniofacial deviations. [10,11]

The increased frequency of complete and partial calcification of sella in subjects with canine impaction provides further evidence of a genetic basis for these conditions and some commonality in the molecular pathways involved. Mutations in the homeobox, HOX, or sonic hedgehog genes negatively influence the development of the midface, the teeth, and parts of sella turcica. [3] Sella Turcica Bridge could be a malformation from prenatal life. The entire cranial base is cartilage-preformed from about the 5<sup>th</sup> foetal week (kjaer, 1990; kjaer and Fischer –Hansen, 1995). [14] Both Muller (1952) and Platzer (1957) reported the presence of a cartilage primordial in connection with a sella turcica bridge. Lang (1977) described a sella turcica bridge in a newborn and in a 9-year-old child. [12-14]

Platzer (1957) observed an association between the course of the internal carotid artery and the occurrence of a sella turcica bridge, which might indicate that these individuals could have been predisposed to the formation of a sella turcica bridge. [15]

Carstens (1949) also studied the occurrence of a sella turcica bridge in patients with various diseases, of whom 8 percent had a sella turcica bridge. He considered that chronic infections may have an effect on the sella turcica on the pituitary gland and, thereby, also on the pituitary gland and thereby, also on the sella turcica, so that focal infections which are not yet clinically manifest may be visible in the sella turcica region, both in the form of a sella bridge and as enlargements of the sella turcica. [16]

Thus, sella bridging highlights the risk of future canine impactions, especially in children with skeletal class III malocclusion with a history of canine impaction in their parents or siblings and who are undergoing phase 1 orthodontic treatment. The results this study suggests that careful monitoring is needed for the

eruption timing of the maxillary canines in children diagnosed with complete or partial calcification of sella turcica.

## CONCLUSION

The result of this study shows, that there is a strong association between sella turcica bridging and skeletal class III jaw bases with canine impaction. The frequency of sella turcica bridging is increased (80%) in patients with canine impactions or the chance of having partial or complete bridging in subjects with impacted canines is approximately 5 times greater than those with erupted canines. Early diagnosis of calcification of sella turcica, using lateral cephalometric radiographs helps to prevent possible tooth impaction or dental transposition in the future, particularly where there may be a family history of skeletal class III malocclusion with tooth impaction or craniofacial anomalies. Hence, sella turcica bridging can complement other diagnostic parameters in confirming the status of canine impaction.

## REFERENCES

1. Marcotty, Reuther, Eisenhauer. Bridging of the sella turcica in skeletal class III subjects'. *Eur J Orthod* 2010; 32:148-53
2. Becker JP, Einersen S, Kjaer I. Sella turcica bridge in subjects with craniofacial deviations. *Eur J Orthod* 2000;22:69-74.
3. Batool Ali, Attiya S, Mubassar F. Association between sella turcica bridging and palatal canine impaction. *Am J Orthod Dentofacial Orthop* 2014; 146:437-41.
4. Jones RM, Faqir A, Millet D. Bridging and dimensions of sella turcica in subjects treated by surgical-orthodontic means or orthodontics only. *Angle orthod* 2005; 75:714-8.
5. Leonardi R, Farella M, Cobourne MT. An association between sella turcica bridging and dental transposition. *Eur J Ortho* 2011; 33:461-5
6. Alkofide EA. The shape and size of the sella turcica in skeletal class I, class II and class III Saudi subjects. *Euro J Orthod* 2007 ;29:457-6
7. Najim AA, Nakib LA. A cephalometric study of sella turcica size and morphology among young Iraqi normal population in comparison to patients with maxillary malposed canine. *J Baghdad Coll Dent* 2011; 23:53-8.
8. Leonardi R, Barbato E, Vichi M, Caltabiano M. Skeletal anomalies and normal variants in patients with palatally displaced canines. *Angle Orthod* 2009; 79:727-32.
9. Leonardi R, Barbato E, Vichi M, Caltabiano M. A sella turcica bridge in subjects with dental anomalies. *Eur J Orthod* 2006; 28:580-5.
10. Schoenwolf GC, Bleyl SB, Brauer PR, Francis-West PH. *Larsen's human embryology*. Philadelphia: Churchill Livingstone; 2009.
11. Duverger O, Morasso MI. Role of homeobox genes in the patterning, specification and differentiation of ectodermal appendages in mammals. *J Cell Physiology* 2008; 216:337-46.
12. Camp J D the normal and pathologic anatomy of the sella turcica as revealed at necropsy. *Radiology* 1923;1: 65-73
13. Taveras J M, Wood E H *Diagnostic neuroradiology*. Williams and Wilkins Co., Baltimore 1964
14. Kjaer I ossification of the human fetal basicranium. *Journal of craniofacial Genetics and Developmental Biology* 1990; 10:29-38
15. Lang J. Structure and postnatal organization of heretofore uninvestigated and infrequent ossifications of the sella turcica region. *Acta Anatomica*. 1977; 99:121-139
16. Carstens M. Die selladiagnostik. *Fortschritte auf dem Gebiete der Roentgenstrahlen und der Nuklearmedizin* 1949; 7:257-272.

How to cite this article: Rasitha V, Dharma RM, Hegde M. Association between sella turcica bridging and canine impaction in skeletal class III malocclusion. *Int J Health Sci Res*. 2018; 8(1):94-100.

\*\*\*\*\*