

Case Report

Epidermoid Cyst of the Buccal Mucosa Presenting as an Odontogenic Abscess in an 82 Year Old Man: An Unusual Presentation

Dr. Partha S Chakraborty¹, Dr. Subhas C Debnath², Dr. Apurba Adhyapok³

¹Senior Lecturer, ²Reader, ³Head of the Department,
Department of Oral and Maxillofacial Surgery, Regional Dental College, Guwahati, Assam, India

Corresponding Author: Dr. Partha S Chakraborty

ABSTRACT

Epidermoid cysts present intraorally in the floor of mouth, and in the 3rd and 4th decades of life. Only a few case reports mention the presence of this cyst in the buccal mucosa. We report a case of epidermoid cyst in buccal mucosa in a 82 year old male, mimicking as odontogenic abscess. The patients with oral epidermoid cyst require periodic follow-up for recurrence.

Key words: Epidermoid cyst, buccal mucosa, odontogenic abscess

INTRODUCTION

Epidermoid and dermoid cysts, lined by stratified squamous epithelium, are rare entities in the oral cavity. [1] When there are no skin adnexa, these cysts are termed epidermoid. [2] The common intraoral location is the submental area, and the common age group affected is 3rd and 4th decades of life. Buccal mucosa is a rare location for the occurrence of an epidermoid cyst.

Here, we report an unusual case of an epidermoid cyst in the buccal mucosa in an 82 year old male patient. To our knowledge, this is the oldest patient presenting with an epidermoid cyst in the oral cavity.

CASE REPORT

An 82 year old male presented to our Outpatient Department with the chief complaint of progressive slow growing swelling on the left cheek of 1 year duration. It was accompanied with toothache in the upper molar region since

the past one week. There was no history of previous surgery or trauma in that region. The case was initially misdiagnosed as an abscess originating from an infected maxillary second molar and was referred to our department for drainage of the same with extraction of the offending tooth.

On intraoral examination, there was a smooth, well defined, swelling on the left buccal mucosa at the level of occlusal plane near the region of the first maxillary molar. The overlying mucosa over the swelling was intact. The swelling was soft and fluctuant in consistency and nontender. There were no palpable neck nodes.

Dental examination showed periodontally compromised teeth with attrition and sharp buccal cusp edges. Computed Tomography (CT scan) showed a well-defined cystic lesion, of approximately 4.5 X 2 cm size in the left buccal space without any infiltration or origin from the adjacent structures. There was no solid component or calcification within the cyst. [Fig 1(a),(b)]

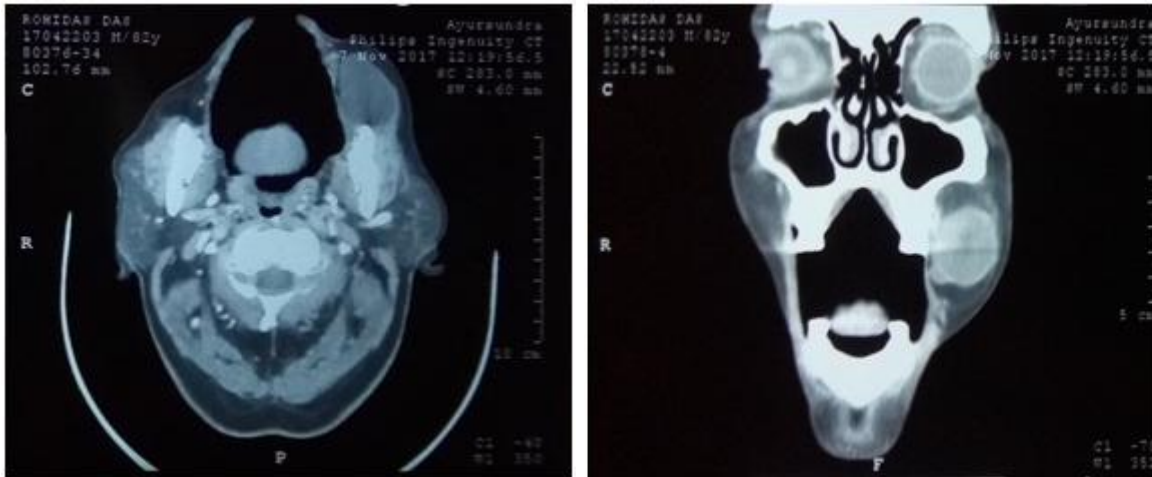


Figure1(a) & (b) - Computed tomogram scan (CT scan) axial and coronal section showing a well defined cystic lesion in the buccal space on left side

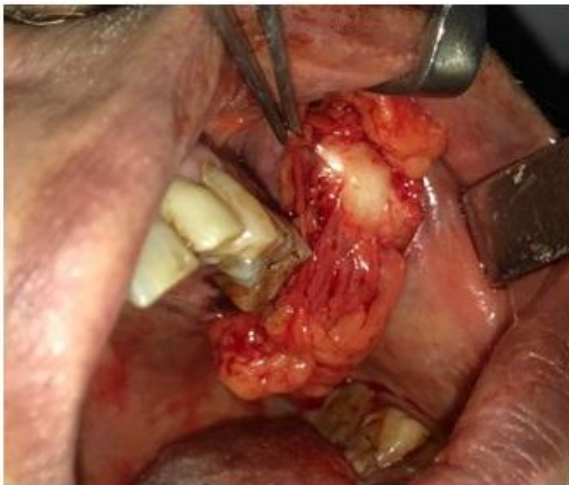

Figure 2 - Intraoperative picture showing the exposure for removal of the the cyst

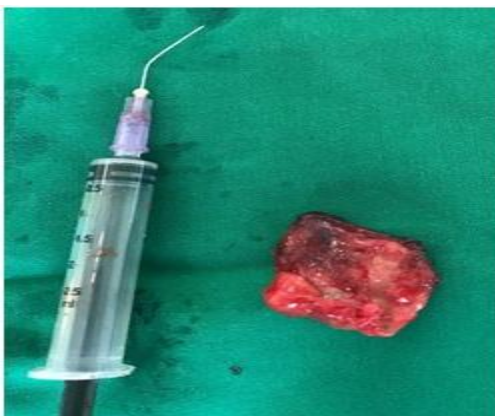

Figure 3 - Post operative Specimen after enucleation in toto

Fine needle aspiration cytology (FNAC) of the lesion was done. The contents of the aspirate yielded a cheesy white material. FNAC revealed squamous cells and cholesterol clefts without any inflammation or atypical cells, which

established the benign nature of the lesion. Intra-operatively the lesion was limited to the buccal space only without extension to adjacent structures. Hence, enucleation of the cyst was done intraorally under general anaesthesia. A cyst of 4.5 × 2 cm in size was removed in toto [Figure 2,3].

After excision of the cyst the cavity was repaired in layers to obliterate the dead space and the specimen was sent for the final histopathological examination. Post operative histopathological examination (HPE) revealed cystic wall lined by stratified squamous epithelium. No skin adnexa were seen, which was in favour of epidermoid cyst. [Fig4].

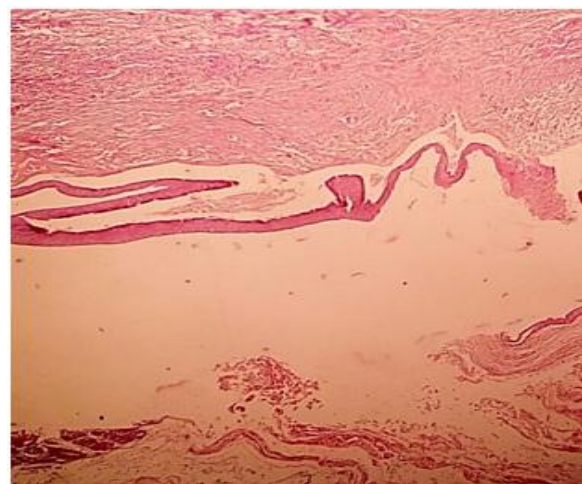


Figure 4 - Photomicrograph of H and E,10 ×40 showing features of cystic wall lined by stratified squamous epithelium

Local recurrence is the most common complication of epidermoid cyst and in the

present case there was no local recurrence at the follow-up of 1 year after treatment. [Fig5]

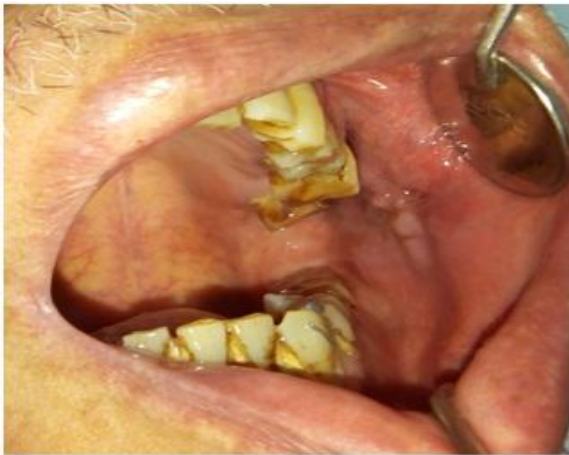

Figure 5- Intraoral picture at the 1 year post excision follow-up

DISCUSSION

Epidermoid cysts are benign lesions, predominantly seen in areas where embryonic elements fuse together. The cases reported account for only 1.6-7 % of cysts in head and neck area and 0.01 % of all oral cysts. [3]

Epidermoid cyst shows preponderance for 3rd and 4th decades of life and is more common in men. [3] However, in our case it was a 82 year old male without any history of trauma or previous surgery.

Within the oral cavity, the most common location is the floor of mouth in the midline. [2] Previously, similar cases in buccal mucosa have been reported by Schneider et al, [4] Rajayogeswaran et al, [2] Ozan et al, [5] Kini et al, [6] Costa et al. [7] In our case also the site is the buccal mucosa.

The etiology of these cysts is essentially unknown. The most popular theory of implantation of sequestered epithelium in lines of fusion of embryonic processes [2] does not explain its presence in buccal mucosa. The term “Implantation” epidermoid cyst is used for post traumatic cysts where previous history of trauma was present. Trauma or injury may act as a triggering factor which may drive the growth of epithelial cells into the dermis. [6] Rajayogeswaran et al and Costa et al had reported previous history of trauma in their case reports. [2,7] Ozan et al had attributed that unnoticeable trauma during mastication to be one of the causative factor. [5] In our case we have observed that presence of sharp cusps in the adjacent area and consumption of areca nut may be the factors leading to unnoticeable trauma leading to cyst formation. Majority of the reported cysts have occurred on left side, which could indicate self-inflicted trauma like from tooth brushing by right handed individuals. [Table 1]

Author	Patient details	Site	Size	History of trauma	Treatment
Schneider et al	36 yr old female	Right	1 cm	None	Surgical enucleation
	30 yr old female	Left	3 cm	None	Surgical enucleation
Rajayogeswaran et al	25 yr old male	Left	2*1.5 cm	Present	Surgical enucleation
Ozan et al	38 yr old female	Left	2*3*4 cm	None	Surgical enucleation
Kini et al	25 yr old male	Left	1.5*1.5*1.5 cm	None	Surgical enucleation
Costa et al	29 yr old male	Right	3.5 cm	Present	Surgical enucleation
Present case	82 yr old male	Left	4.5*2*2 cm	Absent	Surgical enucleation

These cysts may remain asymptomatic for years until they become big enough to interrupt with the patient’s speech, esthetics, mastication and breathing. In long term cases they may become infected.

The differential diagnosis would include a wide variety of lesions, including those of infectious, neoplastic and developmental origin. [6]

CT, MRI and Ultrasonography (USG) can be performed to aid in diagnosis. USG is the first choice because of its feasibility, low cost and efficacy. To arrive at a definitive diagnosis incisional biopsy is the standard tool. However, while doing such biopsies it may damage the cyst wall, resulting in adhesion of the cyst to the surrounding tissues. Fibrosis and adhesions will further obliterate the planes of resection

thus making complete resection difficult and increasing the chances of recurrence.

Complete surgical removal of the lesion is unanimously considered to be the treatment of choice. [7] Malignant transformation of these cysts has been reported by Ikeda et al, [8] Lopez-Rios, [9] and Devine et al. [10] Follow-up for 10 years to detect local recurrence following simple excision of oral epidermoid cyst has been suggested. In the present case, only surgical excision was done, and there was no local recurrence at the follow-up of 1 year after treatment.

CONCLUSION

Authors would like to add an unusual presentation of epidermoid cyst of larger size in the buccal mucosa of a 82 year old patient to the literature. Though epidermoid cysts of the buccal mucosa are extremely rare, it should be considered in the differential diagnosis of lesions in the oral cavity.

REFERENCES

1. Gulati U, Mohanty S, Augustine J, Gupta S. Potentially Fatal Supramylohyoid Sublingual Epidermoid Cyst. *J. Maxillofac. Oral Surg* 2015;141:355–359.
2. Rajayogeswaran V, Eveson JW. Epidermoid cyst of the buccal mucosa. *Oral Surg Oral Med Oral Pathol* 1989; 67: 181-4.
3. Nair R, Shameena PM, Sudha S. unusual presentation of epidermoid cyst of the oral cavity- A case report. *Oral Maxillofac Path J* 2012; 3: 221-223.
4. Schneider LC, Mesa ML. Epidermoid cysts of the buccal mucosa. *Q Natl Dent Assoc* 1978; 36:39–42.
5. Ozan F, Polat HB, Ay S, Goze F. Epidermoid cyst of the buccal mucosa: a case report. *J Contemp Dent Pract.* 2007; Mar 1;8:90-6.
6. Kini YK, Kharkar VR, Rudagi BM, Kalburge JV. An Unusual Occurrence of Epidermoid Cyst in the Buccal Mucosa: A Case Report with Review of Literature. *J Maxillofac Oral Surg.* 2013;12:90-93.
7. Costa FWG, Carvalho FSR, Chaves FN. Epidermoid Cyst Arising in the Buccal Mucosa: Case Report and Literature Review. *Acta Stomatologica Croatica.* 2015;49:65-73.
8. Ikeda I, Ono T. Basal cell carcinoma originating from an epidermoid cyst. *J Dermatol* 1990;17:643–646.
9. Lopez-Rios F, Rodriguez-Peralto JL, Castano E, Benito A. Squamous cell carcinoma arising in a cutaneous epidermal cyst: case report and literature review. *Am J Dermatopathol* 1999;21:174–177.
10. Devine JC, Jones DC. Carcinomatous transformation of a sublingual dermoid cyst- a case report. *Int J Oral Maxillofac Surg* 2000;29:126–127.

How to cite this article: Chakraborty PS, Debnath SC, Adhyapok A. Epidermoid cyst of the buccal mucosa presenting as an odontogenic abscess in an 82 year old man: an unusual presentation. *Int J Health Sci Res.* 2018; 8(11):307-310.
