

Case Report

A Static Progressive Splint for Knee Flexion and Hip Adduction Contracture in Quadriplegia: A Case Study

Sarath Kumar¹, Saroj Kant Behura², Chinmayee Subhasmita Panda³

¹Final year BPO, S.I.H.R&LC, Karigiri

²Asst. Professor, S.I.H.R&LC, Karigiri

³Lecturer, ISHWAR Institute of Prosthetic and Orthotics, Chennai, Tamil Nadu, India.

Corresponding Author: Chinmayee Subhasmita Panda

ABSTRACT

Background: Due to Hyper tonicity or due to postural fault different contractures get developed in quadriplegics, which becomes a main reason for ambulatory as well as functional problem in these patients.

Case Description and Methods: The contractures in lower extremity were treated by an indigenous design of static progressive splint in this case. The subject was a 19 yr old male suffering from quadriplegia. In lower extremity knee and hip contractures were addressed by a static progressive splint. Angle of the knee flexion was measured before the application as well as after 3 months of use.

Findings and outcomes: The flexion contracture was decreased from 68 to 45 degree in right leg and from 55 to 35 degree in left knee joint.

Conclusion: The static progressive splint can be considered as a new, effective and low cost method for treatment of knee flexion contracture as well as hip adduction contracture.

Clinical Relevance: This splint can effectively reduce the flexion contracture of knee along with adduction contracture of hip due to multiple aetiologies.

Key words: Static Progressive Splint, Knee Flexion contracture, Hip Adduction Contracture, Quadriplegia

INTRODUCTION

Quadriplegia is a profound impairment of mobility manifested by paralysis of all four extremities as a consequence of cervical spinal cord injury. About 250,000 to 500,000 people worldwide affected by SCI every year. Out of that 50% occurs at cervical level which leads to quadriplegia. [1-3]

This may be the result of physical trauma due to RTA, fall, sports and leisure activities. Non-traumatic causes include tumour, vascular disorder, infection etc.

In quadriplegics, spasticity and lack of sufficient functioning musculature often leads to joint contracture. Contractures in lower extremities mainly knee flexion, hip

adduction and ankle joints contractures become an obstacle for ambulation and mobility in these patients. Joint contractures in upper extremities as elbow and wrist lead to upper extremity functional loss. [4-6]

A knee flexion contracture is the inability to fully extend the knee. Severe knee flexion contracture can be treated with surgical as well as non-surgical methods. Non-surgical method includes passive stretching, joint mobilization, traction and serial casting. In non-surgical method various static progressive splints are there which increases the ROM. But there is no such splint which acts both at knee and hip joint.

In this study a static progressive splint was designed to provide low load and gradual stretching at knee joint and at the same time maintains the hip joint in abducted position and gradually increases the abduction angle.

MATERIALS AND METHODS

A 3 months trial was conducted to evaluate the development in case of knee flexion contracture with the use of a static progressive orthosis. The knee flexion angle was measured in order to find out the effectiveness of the orthosis.

Subject was a 19 yr old male, referred to hospital for multiple bed sores on gluteal region, trochanteric region and bilateral knee region. Patient was suffering from Quadriplegia after falling in to ditch with heavy weight. He was having c₆ burst fracture and L₁ fracture. Immediately after that the patient was undergone posterior stabilization surgery at c₅-c₇ level as well as anterior corpectomy at c₆, anterior stabilization and fusion at c₅-c₇ level.






He was presented with both the upper limbs in functional condition and with spastic paraplegia in both lower limbs. Muscle wasting was noticed in bilateral arm, forearm and palm. Lower limb muscle spasticity resulted knee flexion contracture and hip adduction contracture in that patient.

The patient was undergone head of femur (left) excision in order to permit abduction of hip. Adductor Magnus tendon was shaved from the pubis both the sides. In order to reduce the knee flexion contracture hamstring tendon was tenotomised. Post surgically the patient was needed to be fitted with one orthosis which will keep the hip in abduction at the same time increase the knee range of motion.

During the study period patient wore the orthosis for 3 months. Immediately after the surgery the patient was provided with the orthosis. The ROM of both the knee joints was measured at pre orthosis period. Then after 3 months of use, again it was measured to examine the effectiveness of the orthosis.

Static Progressive Orthosis Design:

TABLE-1: Components and Its Function of the Static progressive Orthosis

Sl No	Components	Figure	Location	Function
1	Thigh and Calf Shell		23 cm away from axis of mechanical knee joint along vertical axis	Eliminates tissue entrapment, Maximize contact area, Acts as a base for other components
2	Uprights		Along the lateral border of thigh and calf shell	Connects the thigh and calf shell
3	Nuts and Bolts		Middle of the abduction bar, Attachment point of spreader bar to upright	Fastens different components
4	Knee joint		Axis of anatomical knee joint keeping 2.5 inches clearance both the sides	Corrects the knee flexion contractures by gradually extending the knee
5	Abduction Bar		Connects both the thigh shells just distal to its lower border	Maintains the hip abduction position

The static progressive orthosis was a knee orthosis for knee flexion contracture as well as splint for maintaining the hip in abduction position. The conventional knee orthosis was modified according to the patients need. In order to maintain the hip in required abduction position an abduction bar was attached to both the thigh shells. An upright connected the thigh and calf shell in both the sides along with one knee joint which is adjustable in nature. Knee joint was having locking provision in each 20 degree interval which progressively increase the angle by 20° and reduces the flexion contracture of the knee and brings the knee in extension. (Table-1)

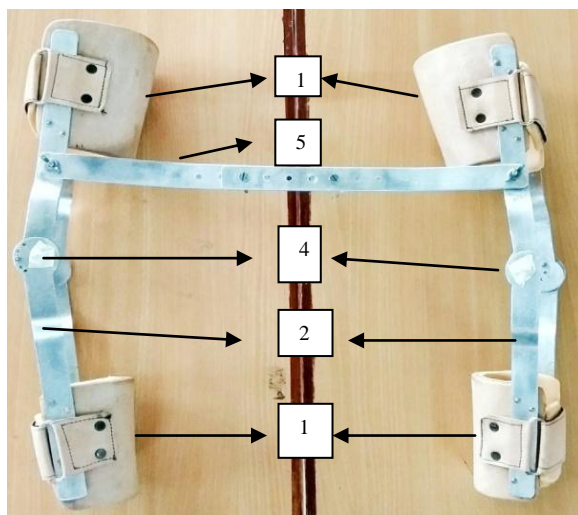


FIGURE 1: Static progressive splint with abduction bar

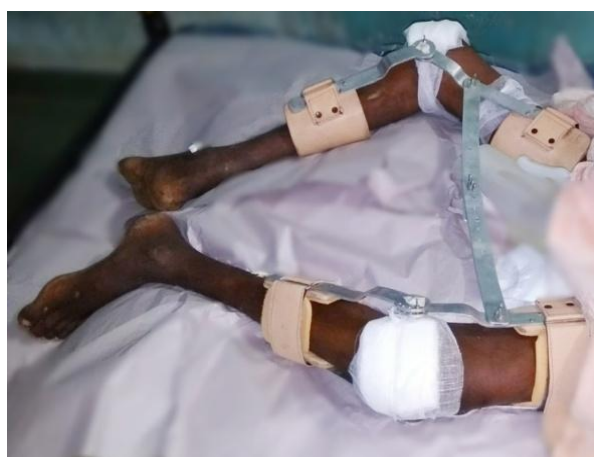

FIGURE 2: Position of knee after splinting

RESULT

A follow up after 3 months of use of the orthosis revealed the improvement of knee joint flexion contracture in right leg 68

to 45 degree and in left leg 55 to 35 degree. The brace was able to maintain the hip abduction position. The average hour of wearing the orthosis was 4 to 5 hours a day, due to skin complications.

DISCUSSION

The present static progressive splint is a low cost, made from locally available material and effective method for the flexion contracture. Previous designs of static progressive splint were prescribed only for one joint that may be knee, hip or elbow etc. But this design addresses both the knee flexion contracture as well as hip adduction contracture.

Some articles suggested that the long term aim of providing static progressive splint at upper extremity is achieving the lost function and at lower extremity is ambulation. [7,8] It is a unique case of therapeutic intervention in which positional splint is used to maintain the corrected abducted position of hip joint and corrective splint is used to regain the range of motion in knee joint flexion contracture. Correction was achieved by surgery i.e. tendon release of flexor muscles and adductor muscles of knee and hip respectively.

Fear of skin breakdown is a serious complication in quadriplegia due to insensate limbs. And the patient was prone to have pressure ulcers before. So, special care was taken during the application of orthosis. Before the application of orthosis limb was covered by gauze which is locally available to avoid direct contact of shells to the limb. It is a case of using hip and knee orthosis without any complications.

CONCLUSION

This case study brought to light a unique orthotic management for case of hip and knee contractures in case of quadriplegia. Through this study it has been proved that it is a new, effective and affordable method of treatment for low economic group. It is an appropriate option in choosing the best orthotic treatment for the patients with combination of knee

flexion and hip adduction contracture.

Conflict Of Interest

The author does not have any conflict of interest regarding research, authorship and publication of this article.

REFERENCES

1. Friden J, Gohritz A. Tetraplegia Management Update. J of Hand Surg Am. 2015(Dec); Vol. 40:2489-2500
2. Friden J, Gohritz A, Novel concepts Integrated in Neuromuscular Assessment for Surgical Restorations of Arm and Hand Function in Tetraplegia. Phys Med Rehabil Clin N Am. 2012;23(1):33-50
3. Brown JM. Nerve transfers in tetraplegia I: Background and technique. Surg Neurol Int. 2011(Aug); vol 2: 121
4. Bickenbach J, ed. International Perspectives on Spinal cord Injury. Geneva: World Health Organisation; 2013
5. Anderson K. D, Targeting Recovery: Priorities of the SCI population. J Neurotrauma. 2004; 21(4): 1371-1383
6. Suksathien R, Suksathien Y. A New Static Progressive Splint for Treatment of Knee and Elbow Flexion Contracture. J Med Assoc Thai. 2010; 93(7): 799-804
7. Yarkony G. M, Hedman G, Donnell O A. Jones-Hedman Walker Modification for C₇ Quadriplegic Patient: Case study in Team Cooperation. Arch Phys Med Rehabil. 1986(Jan); Vol. 67: 54-55
8. Jansen M. C, Windau E. J, Bonutti M. P, Brillhart B. M. Treatment of a Knee Contracture Using a Knee Orthosis Incorporating Stress Relaxation Techniques. Physical Therapy. 1996(Feb); Vol. 76(2): 182-186

How to cite this article: Kumar S, Behura SK, Panda CS. A static progressive splint for knee flexion and hip adduction contracture in quadriplegia: a case study. Int J Health Sci Res. 2018; 8(10):297-300.
