

Case Report

Orthokeratinized Odontogenic Cyst: A Case Report- A Milder Variant of OKC or an Independent Entity

Mariyam Nishana, Imran Mohtesham, Vishnudas Prabhu, Riaz Abdulla

Department of Oral Pathology and Microbiology, Yenepoya Dental College, Yenepoya University, Mangalore, Karnataka, India

Corresponding Author: Mariyam Nishana

ABSTRACT

Orthokeratinized odontogenic cyst (OOC) is a relatively uncommon developmental cyst, thought to be arising from the cell rests of the dental lamina. Orthokeratinized odontogenic cyst (OOC) was first described by Schultz in 1927 and in 1945 Philipsen considered it to be a variant of Odontogenic keratocyst (OKC). OOC exhibits distinctive clinical, pathologic, and behavioral features that varied substantially from KCOT and hence now it is considered as a separate entity. We present a rare case of OOC occurring in a female patient which was attached to the lateral aspect of the root apex of the impacted third molar giving a false gross and radiographic appearance of lateral variant of dentigerous cyst. The clinical, radiological, and histopathological features of this cyst and its surgical management are discussed.

Keywords: Odontogenic keratocyst, dentigerous cyst, orthokeratinization, granular cell layer

INTRODUCTION

Orthokeratinized odontogenic cyst (OOC) is a rare developmental cyst comprising about 10% of cases that had been previously coded as odontogenic keratocysts (OKCs). In 1927, Schultz first described the orthokeratinized odontogenic cyst, later in 1945, Philipsen considered OOC as a variant of an odontogenic keratocyst. The new World Health Organization classification for head and neck tumors has designated OKC as keratocystic odontogenic tumor (KCOT) and reclassified it as a neoplasm in view of its intrinsic growth potential and propensity to recur.^[1] According to this new classification, OOC should not be part of the spectrum of KCOT and should be considered as a separate entity.^[1,2,3,6,8] Odontogenic Kerato Cyst (OKC) (renamed as keratocystic odontogenic tumor [KCOT]) exhibits locally aggressive behavior and are prone to

recurrence where as OOC is milder variant of OKC. Therefore, the correct diagnosis of these lesions is essential for correct surgical treatment and ensuring adequate follow up.^[1,5] Here a case of OOC occurring in the mandible of 20 year old female patient is presented which on clinical and radiographically resembling lateral variant of dentigerous cyst as it was seen in relation to the lateral aspect of the impacted tooth root.

CASE REPORT

A 20-year-old female patient presented with the complaint of pain in the lower left jaw since 4 months. Pain was severe, gradual in onset and intermittent in nature. It was associated with a swelling and difficulty in mouth opening. Extra oral examination revealed slight facial asymmetry. Intra-orally mild swelling and tenderness present in relation to the alveolar

ridge distal to 37. Mild pus discharge noted from the overlying mucosa distal to 37. All

laboratory findings were within normal range.

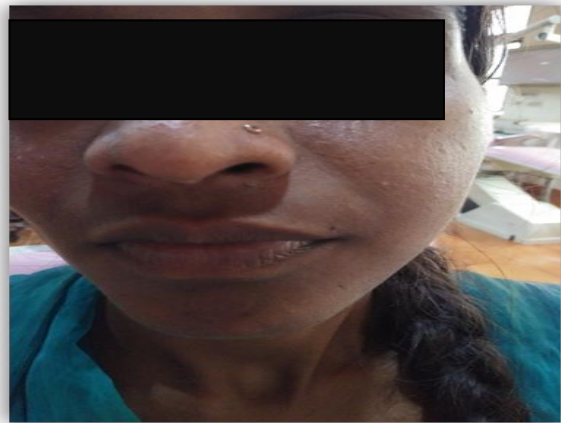

Figure 1. Extraoral photograph showing no visible changes.

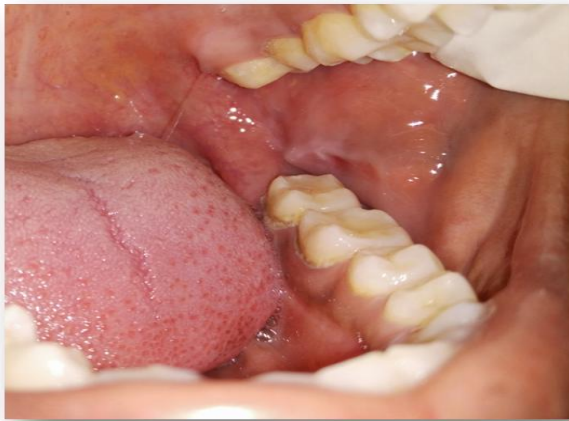
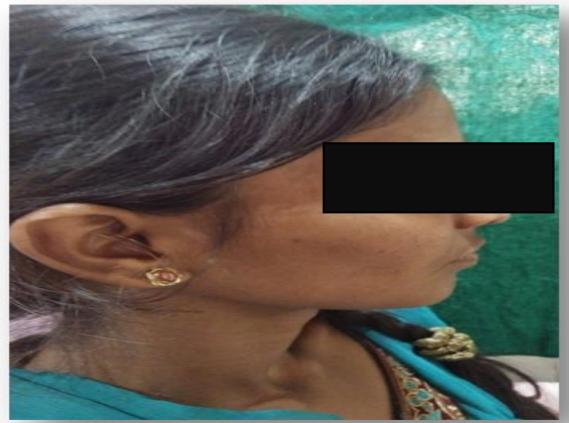
Figure 2. Intraoral photograph showing missing third molar.

taken and sent for histopathological examination using H&E stain.

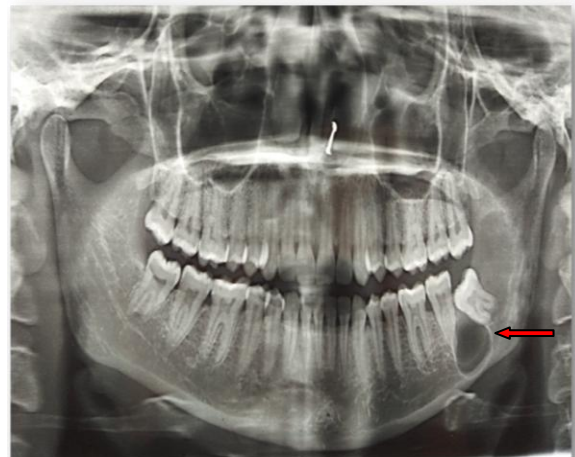

Figure 3. OPG showing presence of a well defined unilocular radiolucency irt to the lateral aspect of 38 approximating 2 cm in greatest dimension extending inferiorly upto 1mm above the inferior border of mandible and involving the distal aspect of the radicular portion of 37.

Orthopantomogram showed a well defined unilocular radiolucency seen in relation to the lateral aspect of mesioangularly impacted 38, measuring about 2 cm in greatest dimension extending inferiorly upto 1mm above the inferior border of mandible and involving the distal aspect of the radicular portion of 37. Provisional diagnosis of lateral dentigerous cyst with impacted 38 was suggested with differential diagnosis of orthokeratinized OKC, unicystic ameloblastoma and lateral periodontal cyst. Surgical enucleation of the lesion with chemical cauterization was done along with surgical removal of the impacted teeth.

Gross examination of the excised specimen revealed a cyst attached to the apical 3rd of tooth root, measuring about 10x8 mm in dimension, yellowish brown in colour. The cystic lumen was filled with white cheesy material. The sections where

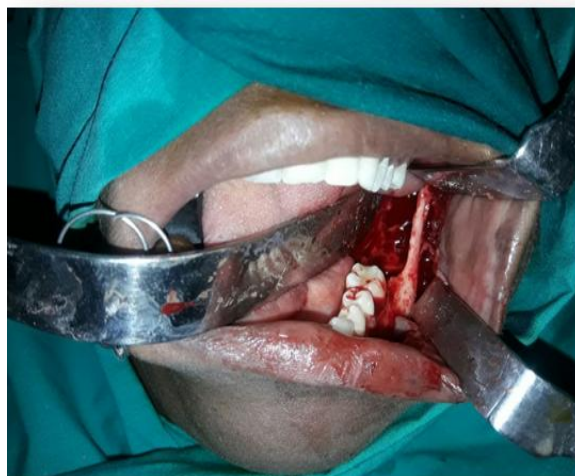

Figure 4. Intra operative picture taken during extraction of impacted 38

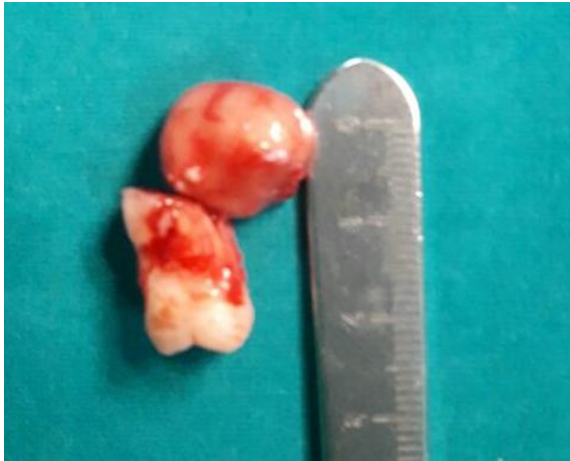

Figure 5. Gross picture of the excised specimen showing presence of a cyst attached to the apical 3rd of tooth root.

Microscopic examination of the specimen revealed a keratin filled cystic cavity lined by 4-6 layers of orthokeratinized stratified squamous epithelium with prominent granular layer and columnar basal cells having palisading arrangement of nuclei. The epithelial-connective tissue interface was rather flat and devoid of rete ridges. Connective tissue capsule showed parallelly arranged bundles of collagen fibres infiltrated with minimal

chronic inflammatory cells predominantly of lymphocytes was also evident in the section.

Based on the clinical, radiographic and histopathological features, the cyst was diagnosed as orthokeratinized odontogenic cyst.

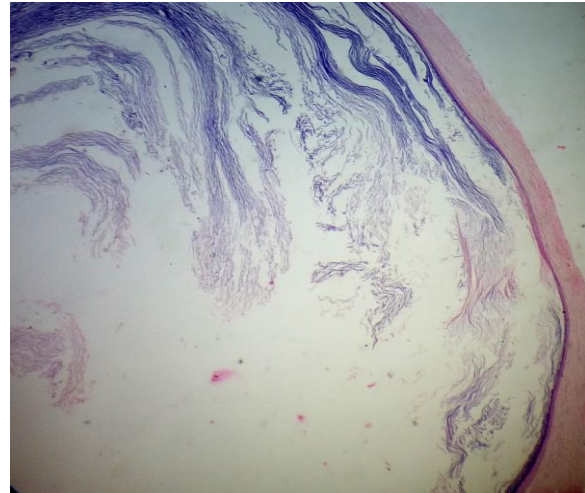


Figure 6. H&E stained sections showing keratin filled cystic cavity with cystic capsule composed of parallelly arranged bundles of collagen fibres.

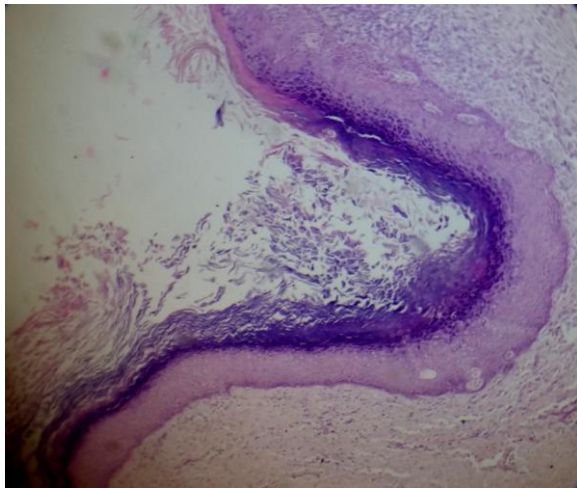


Figure 7 (a&b). H&E stained section under high power showing cystic cavity lined by 4-6 layers of orthokeratinised stratified squamous epithelium with prominent granular layer and columnar basal cells having palisading arrangement of nuclei.

DISCUSSION

The orthokeratinized odontogenic cyst (OOC) is a relatively rare developmental odontogenic cyst, whose histogenesis is still enigmatic. [1,2,6] It was first described by Schultz in 1927 as an orthokeratinized variant of the formerly called OKC, today known as the KCOT.

World Health Organization (WHO) in 1992, defined OOC as the uncommon orthokeratinized type of OKC. OOC shows typical characteristic clinicopathological features and they are different from the parakeratinized odontogenic keratocyst. In 2005, the WHO designated OKC as KCOT based on its behavior (locally destructive,

high recurrence rate), histopathology (formation of daughter cyst and mitotic figures in the suprabasal layers of the lesional epithelium) and genetics (loss of function of tumor suppressor gene PATCH). [1,7]

According to Zhu et al. KCOT may arise from the remnants of dental lamina, dental papilla or from the oral epithelium. [7] Vuhahula *et al.* suggested a different pathogenesis for OOC associated with an impacted tooth. According to them OOC when associated with impacted tooth arises due to the pluripotentiality of odontogenic cyst epithelium. After their function of tooth development, the reduced enamel epithelium may keratinize under appropriate stimuli, thus forming a true dentigerous cyst with orthokeratinization. It has also been considered as a central epidermoid cyst arising from the cell rests of the dental lamina. [1,2,6,7]

Clinically OOC has been reported to occur among young adults of third to fourth decade of life, with a male predominance but present case was reported in a female patient. Mandible is affected twice as often as maxilla, with a predilection for the posterior ramus and molar region. [2,6] Incidentally, about 75% of OOCs are associated with impacted teeth, clinically and radiographically mimicking a dentigerous cyst. [2] The present case was associated with an impacted 38, clinically and radiographically resembling a dentigerous cyst as in accordance with the literature. As the clinicroadiographic diagnosis of any unilocular well circumscribed radiolucency around the crown of an impacted tooth is usually dentigerous cyst microscopic examination will give the final diagnosis. And it was true in the present case reported which was diagnosed initially as lateral variant of dentigerous cyst but histopathologically it showed features of OOC.

Histologically the lesion showed keratin filled cystic cavity lined by 2- 3 layers of orthokeratinised stratified squamous epithelium with prominent

granular layer. The basal layer predominantly composed of columnar cells having palisading arrangement of nuclei. Connective tissue capsule showed parallelly arranged bundles of collagen fibres infiltrated with minimal chronic inflammatory cells predominantly of lymphocytes were also seen. On other hand typical KCOT exhibits a highly cellular parakeratinized epithelial lining with surface corrugations and a palisaded layer of basal cells and additionally, at times diffuse and focal epithelial hyperplasia, epithelial budding, reactive cytological alterations, dystrophic calcification, daughter cysts, odontogenic epithelial remnants and ameloblastomatous epithelium could also be noted. [1,2,6]

IHC staining pattern of OOC showed negative reaction to epithelial membrane antigen and of the carcinoembryonic antigen. Moreover, the level of expression of Ki-67 and p53 is lower in OOC than in KCOT suggesting a reduced proliferative activity and less aggressiveness. [2,4,6] Positive expression of the antiapoptotic marker bcl-2 in the basal cell layer in OKC as against its negative reactivity in OOC also supports for its less aggressive behaviour.

A study reported by Aragaki et al. showed a differential expression of keratin (K) in KCOT and OOC. OOC showed positive reactivity for K1, K10 and Loricrin (LOR), while KCOT shows negative reactivity for all the three, suggesting that keratin profile in OOC was similar to that of epidermis. On the contrary, K4, K13 and K17 expression was strongly positive in KCOT, but negative in OOC, further confirming that the keratin profile in KCOT differs from OOC but is similar to dental lamina. [2,4,6] Therefore, OOC exhibits distinctive clinical, pathologic, and behavioural features that varied substantially from KCOTs. [4]

As OOC is clinically less aggressive and has low rate of recurrence than KCOT, the treatment modality for OOC is more conservative that is by mere enucleation of

the cyst. Removal of entire cystic lining along with the extraction of impacted tooth is the principal treatment modality in OOC. However, if an erupting tooth needs to be preserved, conservative treatment should be done. But thorough sampling of the specimen is required as presence of areas of parakeratinization and polarization will diagnose the lesion as a KCOT which has to be treated more aggressively because of its high recurrence rate (62%). [1,2,6,8] Hence OOC is considered as an independent clinical and pathological entity of the KCOT with a different prognosis with significantly less rate of recurrence.

REFERENCES

1. Yanduri S, Veerendra Kumar B, Shyamala K, Girish Rao S. Orthokeratinised odontogenic cyst. Indian J Dent Adv 2010;2:149-52.
2. Dong Q, Pan S, Sun LS, Li TJ. Orthokeratinized odontogenic cyst: A clinicopathologic study of 61 cases. Arch Pathol Lab Med 2010;134:271-5.
3. Selvamani M, Devi AY, Basandi PS, Madhushankari GS. Prevalence and clinicopathological comparison of kerotocystic odontogenic tumor and orthokeratinized odontogenic cyst in South Indian sample population: A retrospective study over 13 years. J Pharm Bioallied Sci 2014;6:S127-30.
4. Kotwaney S, Shetty P. Orthokeratinized odontogenic keratocyst. Univ Res J Dent 2013;3:101-3.
5. Sarkar S, Khursheed O, Bansal R, Burza WK. Aggressive orthokeratinized odontogenic cyst: A rare case report and review. J Adv Oral Res 2015;6(2):40-43.
6. da Silva MJ, de Sousa SO, Correa L, Carvalhosa AA, de Araujo VC. Immunohistochemical study of the orthokeratinized odontogenic cyst: a comparison with the odontogenic keratocyst. Oral Surg Oral Med Oral Pathol Radiol Endod. 2002; 94: 732-7.
7. Vuhahula E, Nikai H, Ijuhin N, Ogawa I, Takata T, Koseki T, Tanimoto K. Jaw cysts with orthokeratinization: analysis of 12 cases. J Oral Pathol Med 1993
8. Shear M, Speight MP, editors. Cysts of the Oral and Maxillofacial Regions. 4th ed. Oxford: Blackwell Munksgaard Publication; 2007. p. 1.

How to cite this article: Nishana M, Mohtesham I, Prabhu V et al. Orthokeratinized odontogenic cyst: a case report- a milder variant of OKC or an independent entity. Int J Health Sci Res. 2017; 7(9):350-354.
