

Case Report

Peripheral Odontogenic Myxoma with Ossification: A Unique Case Report

Dr. Kavita R. Vanga¹, Dr. Freny Karjodkar², Dr. Kaustubh Sansare³,
Dr. Amaresh Dora⁴, Dr. Ibrahim Ali⁴

¹PG student, ²Professor and H.O.D, ³Associate Professor,
Oral Medicine and Radiology Department, Nair Hospital Dental College, Mumbai
⁴M.D.S in Oral Medicine and Radiology, Nair Hospital Dental College, Mumbai

Corresponding Author: Dr.Kavita R. Vanga

ABSTRACT

Odontogenic myxoma is an uncommon, benign neoplasm and originates exclusively from the tooth-bearing areas of the jaw and more commonly found centrally in the mandible. Soft-tissue localization is seldom seen and is categorized as peripheral odontogenic myxoma. (POM). POM has a low recurrence rate. It grows slowly and less aggressive as compared to the central variety. Only a few cases of POM located on maxillary gingiva are reported in the literature. In this case report, we present an unusual case of POM located on the gingiva in the anterior maxillary region in a 50 year-old female patient and all reported POM's in the literature are discussed .

Keywords: odontogenic myxoma, peripheral, gingiva, maxilla.

INTRODUCTION

Myxoma is a rare, benign mesenchymal tumor found in the numerous sites of the head and neck region. Myxoma of the jaws grows slowly and unlike at the other regions, have a bone destruction tendency and have a high recurrence rate. They can be categorized as osteogenic or odontogenic. Osteogenic myxoma occurs due to the degeneration of the mesenchymal focus of the jaw and is mostly considered as a malignant tumor. [1]

Odontogenic myxoma (OM) is a benign tumor exclusive to the tooth bearing regions of the jaw bones and originates from mesenchymal cells such as dental follicle, papillae, or periodontal ligament. [1] OM constitutes only 3% to 6% of odontogenic tumors. They have a gender predilection in females. Though the lesions can occur at any age, it mostly arises in individuals between 10 and 30 years. The occurrence of

OM in the maxilla is rare as compared to the mandible. [2]

Peripheral odontogenic myxoma (POM) of the intraoral and perioral tissues are rare and considerably less common than the central myxoma of the jaws. [1] Synonyms for POM include soft-tissue odontogenic tumors, extra osseous odontogenic tumors or odontogenic tumors of the gingiva. [2] They are benign, insidious, slowly growing, less aggressive and have low recurrence rate as compared to central OM. [1,2] They may be seen with or without bone destruction. [1] Numerous theories have been proposed regarding the pathogenesis of peripheral myxoma. One of the theories suggests that fibroblasts and myofibroblasts play an important role, whereas the others attribute the origin to the mesenchymal cells such as dental papillae or periodontal membrane. [1]

In the literature, only a few cases of POM located on the gingiva were reported. [1,3-5] In this case report, the peripheral Odontogenic myxoma located on the gingiva in the anterior maxillary region is presented, and myxomas are reviewed according to the literature.

CASE REPORT

A 50 year-old female patient reported to the Oral Medicine and Radiology Unit with the complaint of painless gingival swelling in the upper front teeth region which was initially of small size and gradually increased since six

months. Patient gives history of similar type of growth in the past two years for which she consulted private dentist where excision of the lesion along with the extraction of maxillary right central incisor was done. No histo-pathological record of the previous surgery was available. After the complete healing of the excised site removable partial denture was fabricated and given to the patient. There was associated history of trauma due to sharp flange of removable partial denture. The patient's medical history and family history were non-contributory.

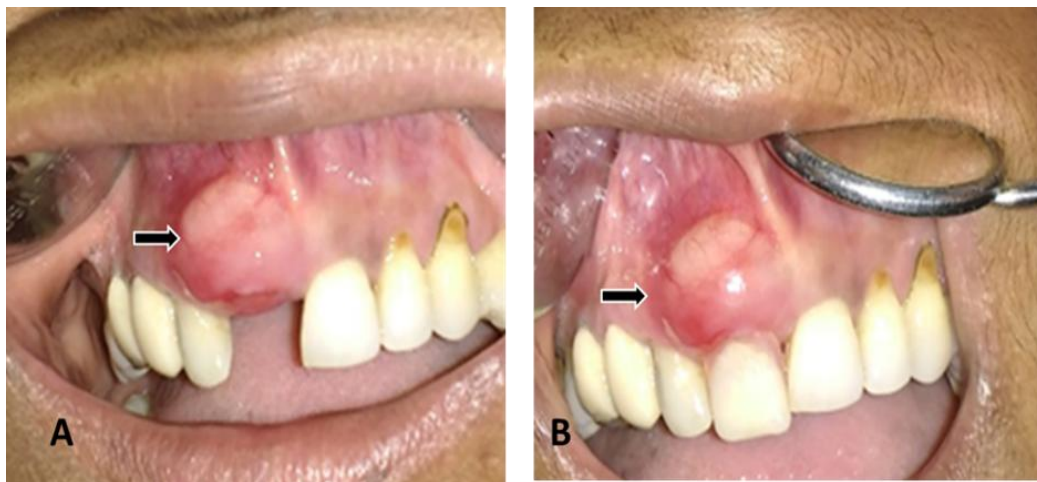

Figure 1: Intraoral photograph showing A: lesion on labial gingiva in relation to maxillary right central and lateral incisor region B. Same lesion with the insertion of RPD

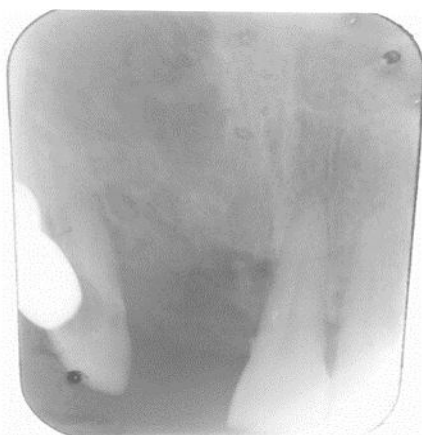

Figure 2: Intra-oral Periapical radiograph showing no bony changes

Extra-oral examination revealed no significant clinical findings. Intraoral examination revealed a solitary swelling on the labial gingiva of the maxilla in relation to maxillary right central and lateral incisor

region measuring approximately 1.5×2 cm supero-inferiorly and 2×2.5 cm medio-laterally. Swelling was oval with smooth surface and overlying mucosa was normal in colour (figure 1). On palpation the lesion was non-tender, non compressible, sessile, fixed to the underlying mucosa and firm in consistency. Maxillary right lateral incisor and left central incisor were grade I mobile. Oral hygiene was average. On intra-oral periapical radiograph of maxillary anterior region no bony changes were evident, as shown in figure 2. Blood investigations were within the normal limits. Based on the clinical and radiographic findings, provisional diagnosis of traumatic fibroma was made with differential diagnosis of nerve sheath tumours, giant cell fibroma and oral focal mucinosis.

Excisional biopsy of the lesion under local anaesthesia was done and the excised mass was sent for histological examination. Microscopic examination of Hematoxylin and Eosin stained section demonstrated abundant loose myxoid tissue containing few collagen fibrils. The tumor was composed of loosely arranged spindle shaped fibroblasts with small round nuclei suspended in a delicate network of collagen fibrils with ossification [Figures 3 and 4]. Small blood vessels were also present and no noticeable odontogenic islands were seen. A diagnosis of peripheral OM with ossification was made. Patient was followed up over a period of 6 months and no recurrence was observed.

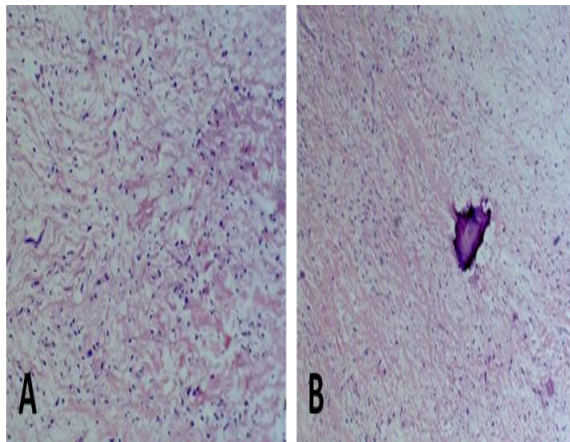


Figure 3: Histopathological picture showing A Hematoxylin and eosin stained section showing loosely arranged spindle cells and fibroblasts with small round nuclei ($\times 4$ scanner view) B Ossification seen in loose myxoid stroma ($\times 10$)

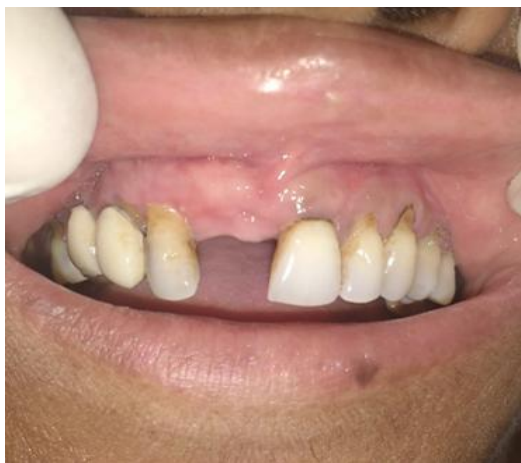

Figure 4: Clinical intraoral photograph of follow-up after 6 months showing no recurrence

DISCUSSION

OM can be categorized in two types, central myxoma situated in the bone and peripheral myxoma situated extraosseously or in the soft tissue overlying the tooth-bearing areas. Schmidseider R, et al described another classification which states that soft tissue-located myxoma arise from the alveolar bone and seen with bone destruction are considered as peripheral odontogenic myxoma. [1]

OM is a locally invasive neoplasm exclusive to the tooth bearing areas of the jaw bones. It is believed to originate from odontogenic ectomesenchyme of the dental follicle. In the fully developed jaw, remnants of odontogenic ectomesenchyme are located in the gingiva and periodontal ligament Ectomesenchymal cells in these locations have a potential to serve as a stem cell population for neoplastic proliferations with the microscopic features of an OM. [4] Although OM is usually considered to be a rare odontogenic neoplasm, they seem to be more frequent in series reported in Africa than in other parts of the world. [4] Mandible appears to be more affected than the maxilla, in the ratio of 3:1. [6] OM commonly occurs in the posterior region of both the jaws. [2] The presented case showed involvement of maxillary anterior region in a 50yr old female which is rare OM commonly occur centrally within the jaw bones, whereas in present case lesion was located peripherally on the gingiva.

Buchner et al. analysed one of the largest series of odontogenic tumors and not even a single case of POM of maxillary gingiva was reported by them. [1] Few cases of maxillary POM of maxillary gingiva have been reported in the literature which is described in brief here. Perrotti et al., reported the POM which was asymptomatic, sessile lesion on attached gingiva present with respect to maxillary left central incisor with a tense elastic consistency on palpation. [3] Aytac-Yazicioglu et al., reported the POM which was asymptomatic, sessile lesion in the right maxillary premolar and molar region on the gingiva extending up to the vestibule and it caused the

migration of the premolar distally. Raubenheimer et al reported two cases with largest dimension of POM which were 9 cm and 10 cm. This indicates of their unlimited growth potential if left untreated. [4] One of the case was pedunculated tumor, asymptomatic, soft in consistency, present on the labial gingiva of maxillary left central and lateral incisor region with slight mobility of involved teeth with no bony involvement and other case was asymptomatic pedunculated attached with a narrow base to the lingual gingiva in the region of the anterior mandibular teeth. The mandibular canine and incisor teeth were tilted forward in a horizontal plane and the mandibular alveolar margin showed cuffing. Vijay et al reported the POM which was asymptomatic lesion, firm in consistency on the labial gingiva of maxillary left central and maxillary left lateral incisor [2] and Tasnime S et al reported POM which was asymptomatic lesion, sessile, soft to firm in consistency, on attached gingiva of maxillary left lateral incisor and maxillary left canine with history of similar type of swelling 1 year back. [5] History of recurrence of the swelling was also reported by our patient. Thus, in literature only four cases were reported in the anterior maxillary gingiva. In our case, the lesion was asymptomatic, sessile, firm in consistency present on the attached gingiva of the anterior maxilla with respect to maxillary right central incisor and maxillary right lateral incisor. These clinical findings are consistent with most of the cases reported. Grade 1 mobility of maxillary right lateral incisor was noted which could be due to localized periodontitis and surrounding trabecular pattern was normal on intraoral periapical radiograph.

The unique finding in our case is the patient was a denture wearer with sharp flanges. All the clinical and radiological findings led us to the diagnosis of traumatic fibroma. There are ten cases of peripheral odontogenic myxoma reported with bone destruction and eight cases of peripheral odontogenic myxoma without bone

destruction in the literature. [1,4,5] Ours is the case of the POM without bone destruction. Peripheral Odontogenic myxoma with bone destruction tend to appear in the older patients with a male predilection compared to the cases without bone involvement. The cases showing bone destruction enlarge rapidly, compared to the ones without destruction. [1] In one of the reports, the authors use the term “soft tissue myxoma” for the gingival mass showing the microscopic features characteristic for OM. [3] Application of the term POM to this tumor would be inappropriate as “soft tissue myxoma” may lead to confusion with the other non odontogenic myxomatous proliferations found in soft tissue. [4] The reported incidences of POM are significantly lower than those of other peripheral odontogenic tumors like the peripheral ameloblastoma (1% of all ameloblastoma), peripheral odontogenic fibroma (total number of reported cases is over 150) and even the rare peripheral dentinogenic ghost cell tumor. [4]

Odontogenic myxoma is categorized as a benign tumor, [3] however, Pahl S et al, reported a malignant variant of odontogenic myxoma. [1] Hence, histopathological diagnosis has to be performed carefully due to the malignant potential of these myxoma. Histologically, the central odontogenic tumor closely resembles the mesenchymal portion of a developing tooth. The tumor is not encapsulated and composed of randomly oriented stellate, spindle-shaped, and round cells with slightly eosinophilic cytoplasmic processes extending from the centrally placed nucleus in an abundant loose myxoid stroma that contains only a few fine collagen fibrils and small islands of odontogenic epithelium. [2] Odontogenic epithelial remnants are not required for the final diagnosis, [1] OM is a tumor of a dual fibroblastic–histiocytic origin and also signifies that the cells comprising OM are of myofibroblastic origin. [2]

Differential diagnosis of odontogenic myxoma should include odontogenic mesenchymal tumors as well as

nonodontogenic tumors with myxomatous degeneration, such as myxoid chondrosarcoma and myxoid neurofibroma. Myxoid neurofibroma is comprised of elongated cells with tapering, bland nuclei, and a pale indistinct cytoplasm. [1] Myxoid liposarcoma is composed of widely separated, monomorphic fusiform cells in a mucoid stroma. Presence of a delicate plexiform capillary network is the significant feature which is not observed in peripheral Odontogenic myxoma. [1] In this case, fibroblastic histogenesis such as collagen fibres and mesenchymal cells are present which is consistent with odontogenic myxoma. In our case unique histological finding of ossification was noted.

The classic treatment of choice in central lesions is surgical resection as they are radio-resistant tumors. Some studies mentioned the overall recurrence rate as 25% due to the lack of capsule and its infiltrative growth pattern. [1,2] However, soft-tissue myxoma is not reported to cause recurrence or metastasis; [2] Various treatment modalities have been described in the literature such as simple enucleation with curettage, simple enucleation with curettage followed by electrical or chemical cautery and the application of liquid nitrogen cryotherapy has also been reported as an adjunctive treatment procedure for the treatment of benign odontogenic tumors. [1] Effective treatment procedure for peripheral odontogenic myxomas include intraoral

approach such as enucleation and curettage. [1] In our case, excision of the lesion and marginal curettage was done. The patient was followed up for 6 months, and with the above surgical intervention, no recurrence has been observed.

REFERENCES

1. Aytac-Yazicioglu D, Eren H, Görgün S. Peripheral odontogenic myxoma located on the maxillary gingiva: Report of a case and review of the literature. *Oral Maxillofac Surg.* 2008; 12:167–171. [PubMed]
2. Vijay Kumar Jain and Soundarya Narayana Reddy. Peripheral odontogenic myxoma of maxillary gingiva: A rare clinical entity. *J Indian Soc Periodontol.* 2013 Sep-Oct; 17(5): 653–656.
3. Perrotti V, Rubini C, Fioroni M et al. Soft tissue myxoma: report of an unusual case located on the gingiva. *J Clin Periodontol.* 2006; 33:76–78
4. Erich J. Raubenheimer and Claudia E. Noffke. Peripheral Odontogenic Myxoma: A Review of the Literature and Report of Two Cases. *J Maxillofac Oral Surg.* 2012 Mar; 11(1): 101–104.
5. Tasnime S, Saxena C, Bansal Vet al. Peripheral odontogenic myxoma. *Indian J Dent Res.* 2016 Jul-Aug; 27(4):437-440
6. Stuart C. White and Michael J. Pharoah. *Oral Radiology Principles and Interpretation.* 5th ed. Missouri: Mosby Publication; 2004

How to cite this article: Vanga KR, Karjodkar F, Sansare K et al. Peripheral odontogenic myxoma with ossification: a unique case report. *Int J Health Sci Res.* 2017; 7(9):302-306.
