

Case Report

# Quantitative Effect of Modified Thoracolumbar Spinal Brace in Kyphoscoliosis - A Case Report

Neha Singh Mitra<sup>1\*</sup>, Bharat Bhusan Bharti<sup>2\*</sup>, Dr. Amed Equebal<sup>3</sup>

<sup>1</sup>Demonstrator (P&O), <sup>2</sup>Prosthetist & Orthotist, <sup>3</sup>Assistant Director Technical,

\*Department of Prosthetics and Orthotics,

National Institute for Locomotor Disabilities (Divyangjan), Kolkata, West Bengal, India

Corresponding Author: Neha Singh Mitra

## ABSTRACT

**Background:** Kyphoscoliosis, abnormal curvature in spinal column often leads pulmonary dysfunction and forward bending of spine. Existing supportive spinal bracing may provide some sort of relieve from pain but upright postural with scope of correction is still challenging.

**Aim:** The aim of present case study was to identify the alternating factors related with spinal bracing which assist in upright postural maintenance.

**Methods:** Quantitative approach was used to identify the effect of customized thoracolumbar spinal brace. Oswestry Low Back Pain Disability Questionnaire and x ray evaluation were used for quantification of result. St. George's Respiratory questionnaire was used to address pulmonary dysfunction. Pre and post test was used with adaptation time for 4 weeks in spinal brace on.

**Result:** Result showed marked relieve in spinal pain with improved Oswestry Disability Index score in post test quantification. There was significant alteration noticed in kyphotic posture but scoliosis was not much changed.

**Conclusion:** This study highlighted the effect of customized spinal brace with some alteration which improves quality of life along with maintain upright spinal posture.

**Key Words:** Kyphoscoliosis, Thoracolumbar brace, Quality of life, Spinal pain, Pulmonary dysfunction.

## INTRODUCTION

Kyphoscoliosis (KS), sagitto-frontal plane deformity where abnormal sideway and posterior spinal curvature reported in both sagittal and frontal plane. Kyphoscoliotic curvature leads dependent activities of daily living (ADL), especially performance of mobility tasks, <sup>[1]</sup> pain, inadequate quality of life <sup>[1,2]</sup> impaired muscular and motor function <sup>[3]</sup> and pulmonary dysfunction. <sup>[4]</sup> With growing age KS leads significant problem and addressing spinal clinical condition in become more challenging than younger age. <sup>[5,6]</sup> Clinical signs included abnormal hunch along with a presence of S or C-like shape,

uneven lengths of arms and legs, some time presence of associated disorders likes neurological disorders and hypertension etc. KS can occur for various causes and in different stage of life.

Changes in spinal shape also lead disruption in balance. An increase sagittal curvature also may alter physiologic loading through the spine and leading to increased flexion moments and compression and shear forces imposed on spine segments. <sup>[2,7]</sup> It may lead various physical constraints, reduced mobility and other orthopedic problems, which leads more energy expenditure during activities and reduced quality of life and functional capacity. <sup>[5,8]</sup>

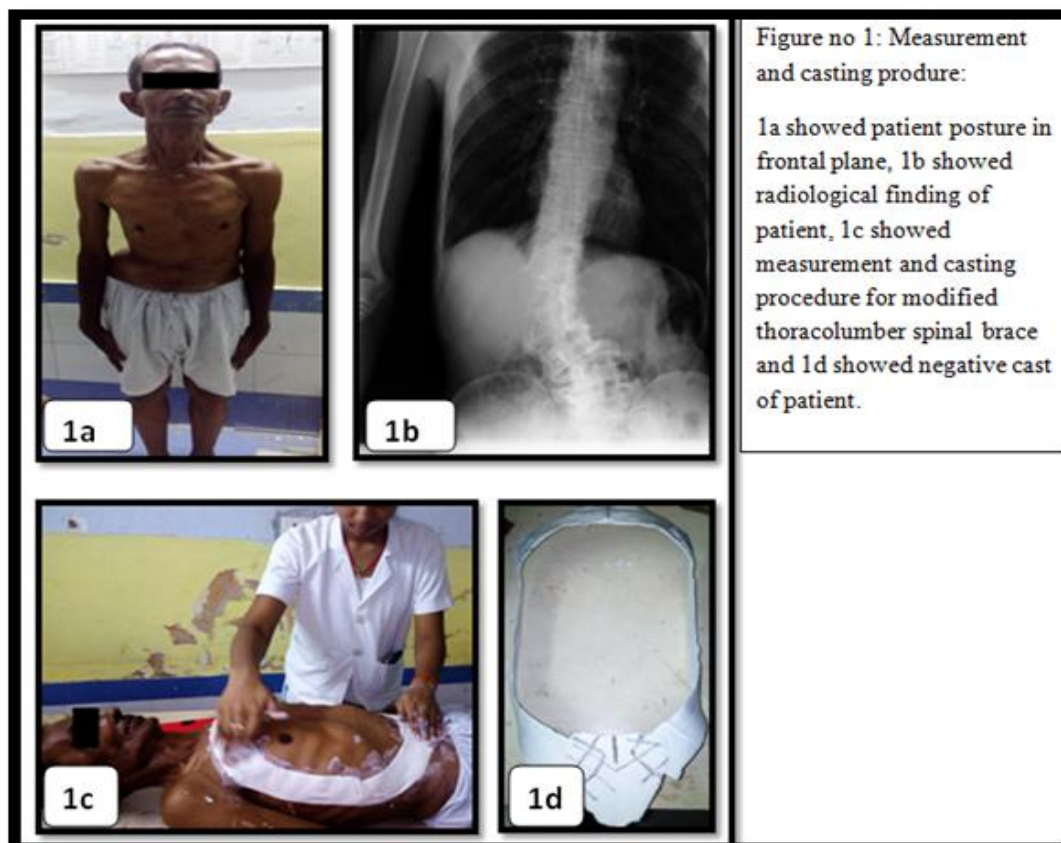Many prefabricated spinal braces are available in the market which can be fitted but problem arises when patient with kyphoscoliosis requires gradual correction and support instead of one time corrective mechanism. One shot correction may lead sever pain, discomfort, more energy expenditure during activities of daily living and sometime rejection of brace too. The aim of this case study was to identify the alternating factors related with spinal bracing which assist in upright postural maintenance with development of alternative support system.


### METHOD

A 56 year male patient with spinal curvature was reported. Patient was also suffered from chronic degenerative diseases, osteoporosis and leads to structural changes in the spine and adjoining tissues. A detailed assessment was performed with demographic data, medical history, x- ray evaluation, Cobb's angle, angulations in sagittal and frontal plane and functional outcome. Patient was reported with

abnormal hunch back with C like shape, uneven leg length and abnormal gait. Patient was assessed with Oswestry low back pain disability questionnaire (QLBPDQ) [9] to assess the severity of pain and St. George's respiratory questionnaire (SGRQ) [10] to identify the respiratory problem. Patient was diagnosed with kyphoscoliosis in thoracolumbar region. QLBPDQ score with interpretation of severity of disability and SGRQ score as 0-100 as per feedback. Patient was fitted with thoraco-lumber molded spinal brace. Fabrication process included measurement, casting, molding, trimming and finishing of molded brace as described in figure no 1 and figure no 2. Pre and post questionnaire feedback was taken after wearing of brace with adaptation of 4 weeks.

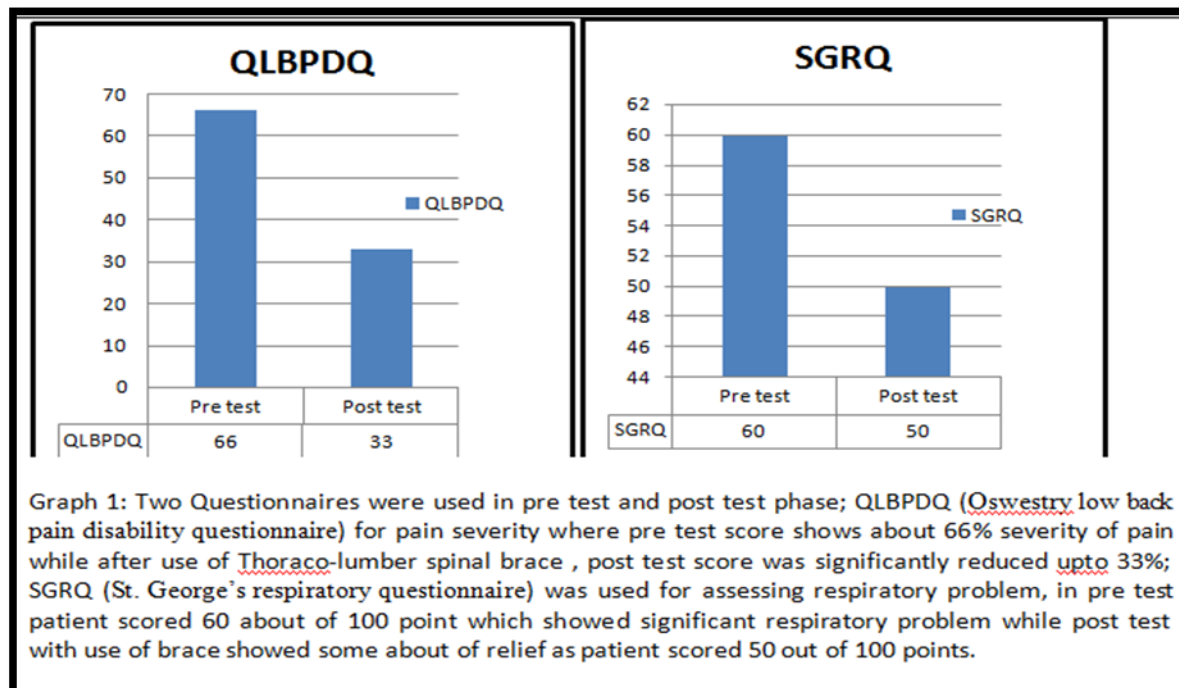
Fabrication of spinal brace includes template fabrication, casting, cast cutting, molding of polypropylene sheet as per various parts. Components and accessories of customized spinal brace were attached with accessories pad, hook and loop straps, wing nut.





## RESULT

Result of this case study was analyzed with comparison of pre and post score of questionnaires. Quantification was performed on based on scoring of pain and respiratory discomfort. QLBPdq pre test score was 66% which signifies crippled condition and post test with 33% score with moderate disability. SGRQ pre test was 60 score and post test score was 50. (Graph no 1) Much change was not reported in SGRQ feedback after use of thoracolumbar orthosis for 4 weeks. X ray evaluation was not showed any significant changes.



## DISCUSSION

This case study was performed to analyze the effect of thoracolumbar spinal brace to address the spinal pain and breathing difficulties in kyphoscoliosis patient. In orthotic design, three point pressure was use to support the spine. Large area was used for distribution of supportive pressure system. Design of thoracolumbar spinal brace was altered to increase the contact surface area. Braces provide support to the muscles and bones, as well as apply

corrective pressure to reduce the curvature. The braces for Kyphoscoliosis have to be designed such that it becomes effective with both abnormal curvatures in the coronal and sagittal plan.

Many factors were responsible for alternating spinal curvature and reduced mechanical loading like gravity, muscle imbalance, loss of bony integrity due to tumour, burst fracture, infection or osteoporosis, and loss of ligamentous stability. [11,12] Muscle (extensor muscles,

the supraspinous and interspinous ligaments, the capsule of the facet joints, and the ligamentum flavum) weakness also leads bending of spine. [11,13]

Orthotic Management of kyphoscoliosis was challenging as in starting fitment, patient feel discomfort with use of spinal orthosis particularly with pelvic area and complain about breathing discomfort. Use of three point pressure system in spinal braces provides supportive and corrective mechanism as well as marked controversy in various research studies. Norton and Brown [14] stated about discomfort caused by spinal devices which applied a three-point pressure over bony prominences to change or maintain posture while using the orthotic device. [15,16] Numerous papers were reporting on brace biomechanics where three point system seems to be universally accepted. [17-19]

As per research studies, better quality of life achieved through pain reduction, decreased limitations of daily living, [20] and improved well-being. [15] Spinal bracing also shows quantitative impact on several aspects on ADL activities and family functioning. [21] It is also evident that brace treatment has implications in some self-perceived condition of human and involved in the concept of quality of life. [22] The deleterious effects on the quality of life may vary in relation to the type of brace selected for treatment. [23] This subjective case study shows more realistic response than purely statistical process. QLBPQ and SGRQ both were used by patient itself, to evaluate the pain severity and breathing discomfort which was indirectly related with spinal bracing.

## CONCLUSION

Spinal abnormality leads impaired ADLs activity and quality of life. Further problem associated with physical pain and respiratory constrictions. Improved spinal posture leads some amount improved quality-of-life and help in pain reduction and decreased limitations of daily living. Present case study concludes with reduced

spinal pain by use of spinal brace in kyphoscoliosis. This study will lead new directions to research papers related with orthotic management in kyphoscoliosis. Future work needed to determine inclusion of more number of participants and more statistical calculation for better understanding of outcome with proper documentation.

**Conflict of Interest:** None declared.

## REFERENCES

1. Katzman, W. B., Wanek, L, Shepherd, J. A. & Sellmeyer, D. E. (2010). Age-Related Hyperkyphosis: Its Causes, Consequences, and Management. *Journal of Orthopaedic & Sports Physical Therapy*. 40, 352-8.
2. Briggs, M. A., Dieën, van H. J., Wrigley, V. T., Greig, A. M., Phillips, B., Lo, S. K. & Bennell, K.L. (2007). Thoracic Kyphosis Affects Spinal Loads and Trunk Muscle Force. *Physical Therapy*. 87, 595-12.
3. Sinaki, M, Brey, R. H., Hughes, C. A., Larson, D. R. & Kaufman, K.R. (2005). Significant reduction in risk of falls and back pain in osteoporotic-kyphotic women through a Spinal Proprioceptive Extension Exercise Dynamic (SPEED) program. *Mayo Clinic Proceedings*. 80, 849-6.
4. *Bergofsky EH: Respiratory failure in disorders of the thoracic cage. Am Rev Respir Dis. 1979, 119: 643-669.*
5. Takahashi T, Ishida K, Hirose D, Nagano Y, Okumiya K, Nishinaga M, Yamamoto H. (2005). Trunk deformity is associated with a reduction in outdoor activities of daily living and life satisfaction in community-dwelling older people. *Osteoporosis International*. 16, 273-6.
6. *Jeong, K. G. & Bendo, A. J. (2004). Spinal Disorders in the Elderly. Clinical Orthopaedics and Related Research*. 25, 110-125
7. Harrison, D. E., Cailliet, R, Harrison, D. D., Janik, T. J., Holland, B. (2001). Reliability of centroid, Cobb, and Harrison posterior tangent methods: which to choose for analysis of thoracic kyphosis. *Spine*. 26, 227-234.



8. Ryan, S. D. & Fried, L. P. (1997). The impact of kyphosis on daily functioning. *Journal of the American Geriatrics Society*. 45, 1479–1486.
9. Fairbank JC, Pynsent PB. *The Oswestry Disability Index*. *Spine* 2000 Nov 15;25 (22):2940-52.
10. St. George's Respiratory Questionnaire (SGRQ). (cited 2017 June 6) <https://www.thoracic.org/members/assembleies/assembleies/srn/questionnaires/sgrq.php>
11. McGill, S. M, Hughson, R. L & Parks, K. (2000). Changes in lumbar lordosis modify the role of the extensor muscles. *Clinical biomechanics (Bristol, Avon)*. 2000;15 (10), 777–780.
12. van Dieën J. H. (1997). Are recruitment patterns of the trunk musculature compatible with a synergy based on maximization of endurance? *Journal of Biomechanics*. 30, 1095–1100.
13. Panjabi, M, Brand, R & White, A. (1976) Mechanical properties of the human thoracic spine. *The Journal of bone and joint surgery*. American volume. 58, 642.
14. Norton, P. L. & Brown, T. (1957). The immobilization efficiency of back braces, their effect on the posture and motion of the lumbosacral spine. *The Journal of Bone and Joint surgery*. American volume. 39-A (1), 111-139.
15. Pfeifer, M, Begerow, B & Minne H. (2004). Effects of a New Spinal Orthosis on Posture, Trunk Strength, and Quality of Life in Women with Postmenopausal Osteoporosis: A Randomized Trial *American journal of physical medicine & rehabilitation*. 83(3), 177-186.
16. Lumsden, R. M. & Morris, J. M. (1968). An in vivo study of axial rotation and immobilization at the lumbosacral joint. *The Journal of bone and joint surgery*. American volume. 50, 1591-1602.
17. Rigo, M, Negrini, S, Weiss, H. R., Grivas, T. B., Maruyama, T & Kotwicki, T. (2006). 'SOSORT consensus paper on brace action: TLSO biomechanics of correction (investigating the rationale for force vector selection)'. *Scoliosis*. 1, 11.
18. Jonasson-Rajala, E, Josefsson, E, Lundberg, B & Nilsson, H. (1984). Boston thoracic brace in the treatment of idiopathic scoliosis. Initial correction. *Clinical Orthopaedics*. 183, 37-41.
19. Schmitz, A, Konig, R, Kandyba, J, Pennekamp, P, Schmitt, O & Jaeger, U. E. (2005). Visualization of the brace effect on the spinal profile in idiopathic scoliosis. *European Spine Journal*. 14, 138-143.
20. KADO, M. D. (2009). The rehabilitation of hyperkyphotic posture in the elderly. *European Journal of Physical and Rehabilitation Medicine*. 45, 583-93.
21. Gratz, R. R. & Papalia-Finlay, D. (1984). Psychosocial adaptation to wearing the Milwaukee brace for scoliosis. *Journal of Adolescent Health Care*. 5, 237–24.
22. Myers, B. A., Friedman, S. B. & Weiner, I. B. (1970). Coping with a chronic disability: psychosocial observations of girls with scoliosis treated with the Milwaukee brace. *The American Journal of Diseases of Children*. 175–181.
23. Korovessis, P, Zacharatos, S, Koureas, G & Megas, P. (2007). Comparative multifactorial analysis of the effects of idiopathic adolescent scoliosis and Scheuermann kyphosis on the self-perceived health status of adolescents treated with brace. *European Spine Journal*. 16, 537–546.

How to cite this article: Mitra NS, Bharti BB, Equebal A. Quantitative effect of modified thoracolumbar spinal brace in kyphoscoliosis - a case report. *Int J Health Sci Res*. 2017; 7(8):516-520.

\*\*\*\*\*