

Case Report

Multilocular Cystic Renal Cell Neoplasm of Low Malignant Potential: A Case Report with Review of Literature

Dr Shashikala K¹, Dr Mohammad Naushad Ansari², Dr Prakash C J³,
Dr Anisha TS¹

¹Assistant Professor, ²Resident, ³Professor,
Raja Rajeswari Medical College and Hospital, Bangalore

Corresponding Author: Dr Shashikala K

ABSTRACT

Multi-locular cystic renal cell carcinoma (MCRCC) is a renal cortical neoplasm with a distinct multi-locular gross appearance and is a variant of clear cell RCC. It is an uncommon low-grade tumor with excellent prognosis. Up to 90% cases are discovered incidentally on radiologic evaluation for other causes. The chief differential diagnosis includes cystic nephroma, cystic clear cell carcinoma, clear cell papillary renal cell carcinoma and tubulocystic carcinoma. Only few cases of MCRCC are reported in literature. This case is being highlighted for its rarity and so as to avoid a misdiagnosis as conventional RCC.

Keywords: Multilocular cystic renal cell carcinoma, low grade potential, kidney

INTRODUCTION

It is a well-differentiated clear cell RCC. The 2004 World Health Organization (WHO) classification of kidney tumors recognizes multilocular cystic renal cell carcinoma (MCRCC) as a rare variant of clear cell carcinoma with a good prognosis. [1] MCRCC is also known as multilocular clear cell RCC and multicystic clear cell carcinoma. These tumors comprise 1-2% of all renal tumors. MCRCC is usually positive for CD10, vimentin, and epithelial membrane antigen (EMA).

CASE REPORT

A 61-year-old female patient presented to the urology department with pain in right lumbar region since 2 months. Ultrasonography revealed a mass in the cortex of the right kidney with left renal calculus with mild hydronephrosis. Contrast enhanced computed tomography (CECT)

showed a well defined complex cyst in the upper pole measuring 3.2x2.7cms with calcification and peripherally enhancing solid component within. Another cyst measured 7x7 mm in the interpolar region. A diagnosis of Right renal complex cyst indeterminate, Bosniak type 3 cyst with left non-obstructing renal calculus was made. The partial nephrectomy specimen was sent for histology.

MACROSCOPY

The right nephrectomy specimen measured 5x 4.5 x 1.5 cms with a part of peri-nephric fat and adrenal gland. Cut surface of the right kidney showed a well delineated and encapsulated cystic mass measuring 3x3cms. Cut-surface of the growth was multiloculated, cystic with thin septae in between the cysts. The largest cyst measured 1.5x1.0cms.No solid areas were noted. The cysts were filled with clots and a

foci of calcification was noted. The ureter was grossly free from any growth. Right adrenal measured $2.5 \times 2 \times 1$ cm. Cut-surface of adrenal was within normal limits grossly.

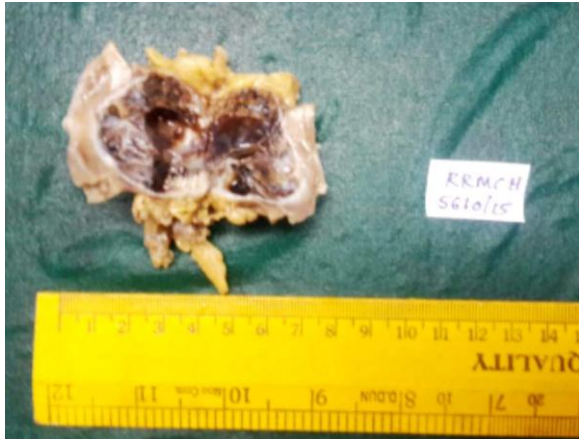


Fig 1: Right kidney showing multiloculated cystic mass with thin septae in between the cysts

Sections show multiple cysts of varying sizes separated by septae containing tumor cells showing uniform, hyperchromatic nucleus, inconspicuous nucleoli (Fuhrman nuclear grade 1), and abundant clear cytoplasm with distinct cell borders. Mitotic figures were sparse. Lumen of the cysts contained eosinophilic secretions/hemorrhage. Septae between the cyst also contains cords and clusters of similar tumor cells, (Fig 1, 3, 4). The ureteric resected margin, peri-nephric fat and renal vessels were free from tumor cell invasion. Adjacent renal parenchyma showed focal glomerular hyalinization and sclerosis, tubular casts, calcification, ossification and chronic inflammatory cell infiltrate, (Fig 2). The adrenal was within normal histological limits. The histomorphology was compatible with MCRCC, Fuhrman nuclear grade 1.

MICROSCOPY

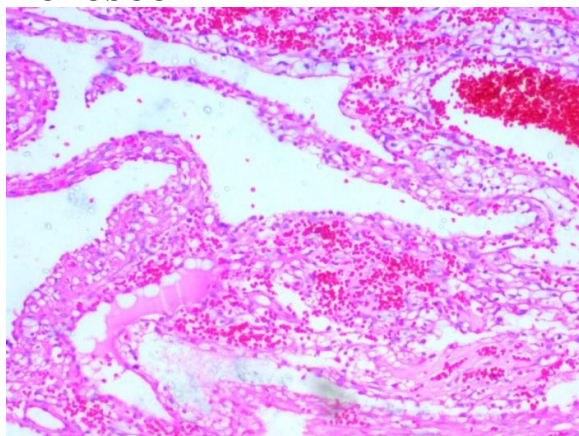


Fig 2

Fig 2: Photomicrograph shows cysts of varying sizes separated by septae containing tumor cells, H&E(X10).

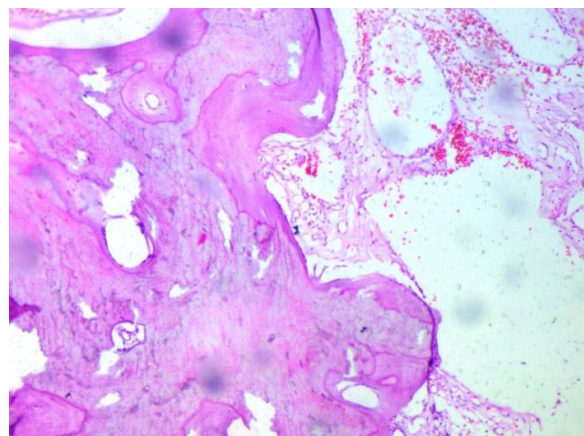


Fig 3

Fig 3: Ossification with cyst and tumor cells, H&E (x40)

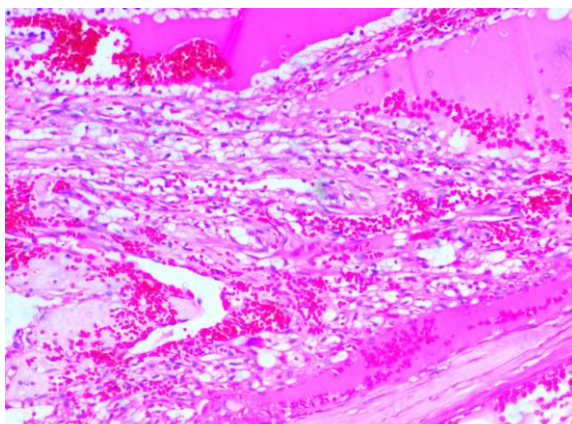


Fig 4

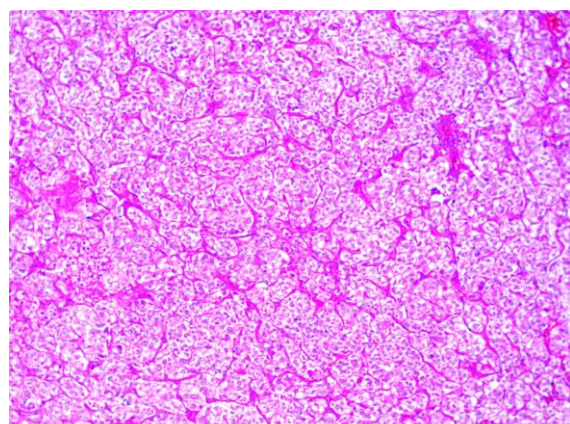


Fig 5

Fig 4 & 5: Photomicrograph shows septae with tumor cell showing uniform, hyperchromatic nucleus, inconspicuous nucleoli (Fuhrman nuclear grade 1), H&E(x40).

DISCUSSION

MCRCC is also known as multilocular clear cell RCC and multicystic clear cell carcinoma. These tumors comprise approximately 1-2% of all renal tumors. [1,2] Multilocular renal cysts are usually benign, but malignant changes may occur. It usually presents as a solid mass, but in 10-22% of cases, RCC appears as a unilocular or multilocular cystic mass on imaging studies. The male to female ratio for MCRCC is 3:1. The mean age of incidence is 51 years. [1] According to the Bosniak classification, based on imaging criteria, multilocular cystic RCC may present as a Bosniak type III cystic lesion (and occasionally as a Bosniak type II lesion). However, this type of Bosniak lesion can also be due to a mixed epithelial and stromal tumor of the kidney (MESTK), a cystic nephroma or a multilocular cyst, all of which are benign lesions.

Gallo and Penchansky hypothesized the patho-genesis of multilocular renal cysts as follows: (i) those of dysgenetic origin are topographically confined to a single lobe, and (ii) those of neoplastic origin are mainly based on observations of clinical and histologic similarities with Wilms' tumor. [1,3]

Diagnosis is mainly done on histopathological features such as a well-developed capsule, fibrous stroma, multiple epithelial lining septa, and nuclear features. No papillary growth should be identified. These groups must not be expansile nodules and must not show infiltrative growth. Nuclei should be of low grade (1 or 2). These Diagnostic criteria were defined by the 2004 WHO classification of kidney tumors based on suggestions of Ebin and Bonsib. Von-Hippel Lindau mutations have been identified in 25% of tumors, the neoplastic cells in a majority of the cases being strongly reactive to PAX2 and CAIX, similar to typical low-grade clear cell RCC. [1]

Shams H et al study observed Chromosome 3p deletion in 89% of the clear cell RCC cases and 74% of the

multilocular cystic RCC cases, with no significant difference in the status of chromosome 3p deletion between clear cell RCC and multilocular cystic RCC. The differential diagnosis of MCRCC consists of other cystic lesions of kidney, primarily cystic nephroma, extensively cystic clear cell RCC, clear cell papillary RCC, and tubulocystic carcinoma. [1,4] To date, this tumor has never been shown to metastasize. However, Walsh *et al.* in 2010 have reported the first case of MCRCC metastasizing to one out of seven intra-aortocaval lymph nodes.

Clinically, MCRCC behaves as a low-grade variant of RCC with stage I disease at initial presentation in 83% to 88% of cases. The tumor has an extremely high cure rate following surgical resection, with a range of 92% to 100%. Vascular invasion, sarcomatous transformation, and metastatic spread have not been reported. [4]

The diagnostic rarities of finding a completely cystic renal cell carcinoma and the excellent prognosis, few authors have suggested renaming it as multilocular cystic renal cell neoplasm of low malignant potential. [3,4]

CONCLUSION

Multilocular cystic RCC is a tumor composed entirely of numerous cysts, the septa of which contain groups of clear cells indistinguishable from grade I clear cell RCC. It has excellent prognosis when compared with the other variants of RCC. Based on the excellent outcomes, this lesion is redefined as *multilocular cystic renal cell neoplasm of low malignant potential*. Accordingly nephron-sparing surgery is recommended as a therapeutic strategy.

REFERENCES

1. Mazzucchelli et al, Multilocular Cystic Renal Cell Neoplasms of Low Malignant Potential, *Anal Quant Cyto-pathol Histopathol* 2012; 34:235–238.
2. Ordonez NG, Rosai J. Urinary tract. In: Rosai J, editor. *Rosai and*

- Ackerman's Surgical Pathology. 9th ed. Missouri: Mosby; 2004. pp. 1163–72.
3. Anadi Roy Chowdhury, Debasis Chakraborty, Palash Bhattacharya, and Ranjan Kumar Dey, Multilocular cystic renal cell carcinoma a diagnostic dilemma: A case report in a 30-year-old woman, *Urol Ann*, v.5(2); Apr-Jun 2013.
 4. Suzigan S, López-Beltrán A, Montironi R, Drut R, Romero A, Hayashi T, et al. Multilocular cystic renal cell carcinoma: A report of 45 cases of a kidney tumor of low malignant potential. *Am J Clin Pathol*. 2006; 125:217–22

How to cite this article: Shashikala K, Ansari MN, Prakash CJ et al. Multilocular cystic renal cell neoplasm of low malignant potential: a case report with review of literature. *Int J Health Sci Res*. 2017; 7(8):492-495.
