

Case Report

A Case Report on Rare Immature Teratoma of Ovary

Dr. H. P. Gupta¹, Dr. Shivani Singh², Dr. Deepali Mehra³

¹Professor, ²Associate Professor, ³Junior Resident,
Department of Obstetrics and Gynaecology, Era's Lucknow Medical College & Hospital, Lucknow

Corresponding Author: Dr. H. P. Gupta

ABSTRACT

Immature Teratoma is a germ cell tumour. Pure immature teratoma is extremely rare and represents approximately 1% -3% of all ovarian cancers. Immature teratomas are usually diagnosed in girls and young women up to their early twenties. In this case report a 18 yrs old unmarried female was admitted in Era's Lucknow medical College and hospital on 2nd Sept. 2016 with lump and pain in abdomen associated with nausea and vomiting. On per abdomen examination a firm mass approximately 24 weeks size reaching upto umbilicus was present. Her baseline investigations were normal and her USG reports showed a complex solid adnexal mass suggestive of neoplastic etiology, CECT revealed a well defined heterogeneously enhancing, abdominopelvic mass likely to be immature teratoma. She underwent Total abdominal hysterectomy with right sided salpingo-oophorectomy with omentectomy. The HPE report revealed tumour mass comprised of immature neural element in form of cellular glial tissue and neuroepithelial rosettes. So we planned adjuvant chemotherapy. Patient has already received 3 cycles of bleomycin, etoposide and cisplatin.

Keywords: Immature teratoma, CECT, adjuvant chemotherapy

INTRODUCTION

Teratomas are tumours commonly composed of multiple cell types derived from one or more of the three embryonic germ layers: ectoderm, endoderm, and mesoderm. [1] The word teratoma is derived from the Greek word "teraton" meaning monster. [2] It was initially used by Virchow. Ovarian teratoma is a type of germ cell tumours subclassified into mature and immature type.

Immature teratoma of ovary is a rare tumour representing 1-3% of all germ cell tumour. Immature teratomas differ from mature cystic teratomas because they have clinically malignant behavior are not as common as mature cystic teratomas (<1% of ovarian teratomas) and are histologically characterized by the presence of immature

or embryonic tissues. [3] They affect younger women commonly in age group of 15 -19 years. Immature teratomas rarely appear during the menopausal period.

Teratomas are discriminated in benign mature and malignant immature pathologies. Malignant teratomas represent 3% of teratomas. [4]

CASE REPORT

We are presenting a case report of 18 years old unmarried girl who was admitted in Era's Lucknow Medical College on 2nd sept 2016 with chief complain of lump and pain in lower abdomen since 6 months. She had vague pain, insidious in onset, off and on and associated with nausea and vomiting and loss of appetite. She was operated 1 year back for lump in abdomen and

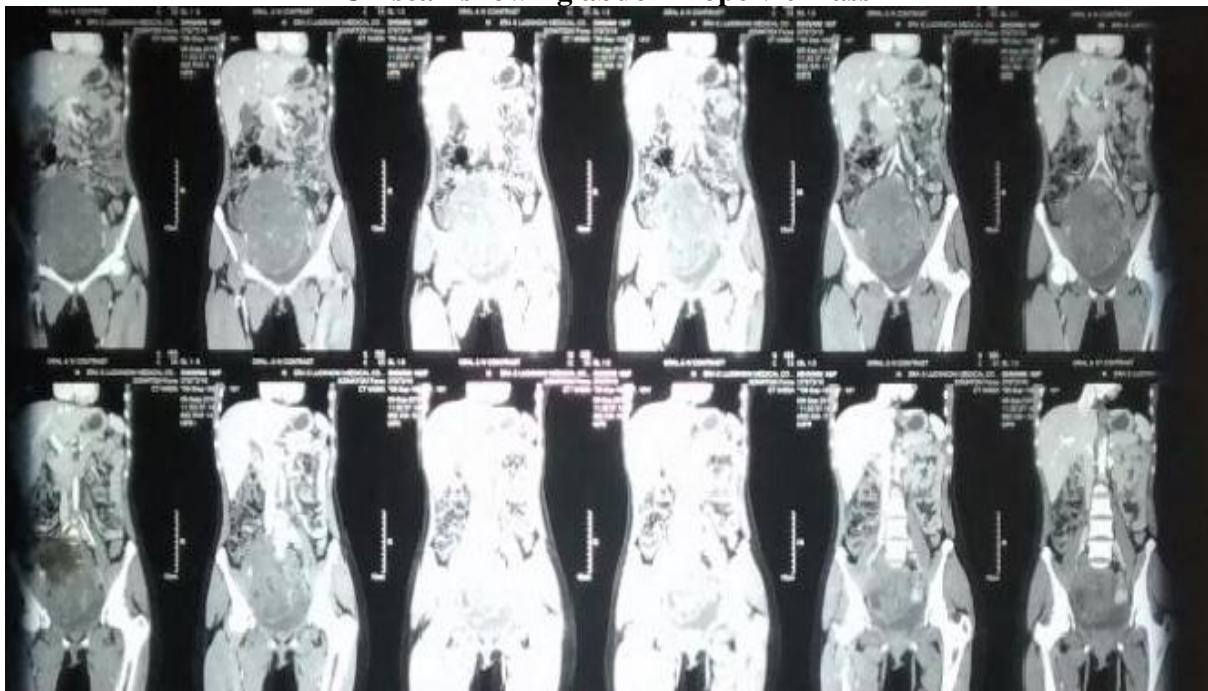
underwent laparotomy at district hospital Shahjhanpur. No details of operative procedure were available; the histopathological records showed that it was mature ovarian teratoma. There was no other significant past, personal or family history. On general examination patient was of average built, well oriented to time place and person. Her vitals were BP= 110/70 mmHg, Pulse= 88 /min, Temp = 98.6 F, RR=18/min. There was no pallor, icterus, cyanosis, clubbing, lymphadenopathy and there was no pedal oedema.

On Examination: abdomen was distended, and a right paramedian scar mark of previous surgery was present. On palpation, a firm mass corresponding to 24 weeks of gestation reaching upto umbilicus was present, it was well circumscribed mobile from side to side, nontender, there was no free fluid. Her Baseline investigations were

within normal limit Hb= 10.8 %, TLC=11000, DLC=N₇₅L₂₅, Platelet=3.5 lakhs, Blood group=A +ve, viral markers negative by elisa, PT=13sec, PC=100, INR=1, Tot bilirubin=0.30mg/dl, SGOT=24 U/L, SGPT=21 U/L, ALP=149 IU/L, Blood Urea= 19 mg/dl, Creatinine=0.6 mg/dl, CA 125 levels was 56 IU/L.

On USG complex solid adnexal mass with few cystic areas extending into abdominal cavity upto supra umbilical level S/O neoplastic etiology was found. CECT revealed a well defined heterogenously enhancing, abdominopelvic mass measuring (17.8*14.8*11.6) cm with multiple hypoenhancing areas, foci of calcification, areas of fat attenuation with multiple vascular channels with minimal ascites likely to be neoplastic teratoma (immature).

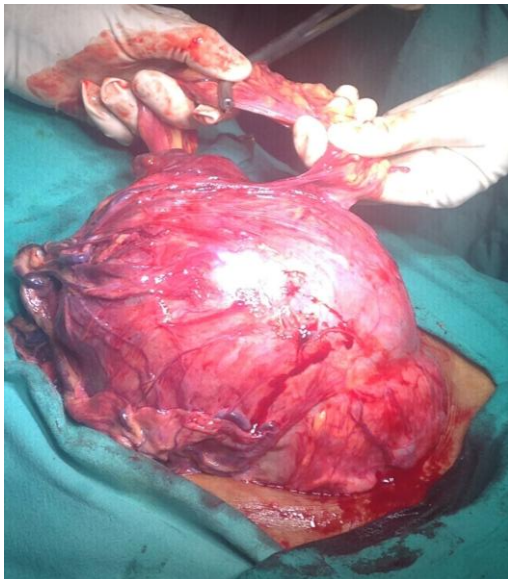CT scan showing abdominopelvic mass



The patient underwent exploratory laparotomy On exploration a 16x13 cm size mass was seen attached to the uterus on the right cornua. Right ovary was normal and was separated from the mass, left ovary and tube were absent which must have been removed in previous surgery. There was no

ascites and lymph nodes were not palpable. Mass could be easily detached from the uterus by blunt dissection. The gross appearance of the mass was giving the suspicion of malignancy therefore total abdominal hysterectomy with right sided salpingo-oophorectomy was done. (Patient

herself and her parents were counselled and informed consent was taken after explaining the gravity of the problem). On gross examination tumour measuring 16x13x5cm, globular, outer surface smooth and encapsulated. Uterus and cervix with one sided adnexa measuring 9x3x1.5 cm. Right sided ovary measures 3x2cm fallopian tube measure 7x1.2cm. The HPE report revealed tumour mass composed of immature neural element in form of cellular glial tissue and neuroepithelial rosettes. **IMPRESSION:** Tumour mass - Immature teratoma, ovary - multiple follicular cyst, corpus albican, uterus was normal.



Mass of 16*13 cm attached to uterus on right cornua

DISCUSSION

In this case ovary of the same side was found to be normal and the mass was firmly attached to serosa of uterine wall on right side, the other ovary was absent so it must be metastatic seedling which must have got deposited on the serosa of uterine wall and attained such a big size in 6 months period. This mass was diagnosed as immature teratoma, on HPE examination therefore adjuvant chemotherapy was planned. Patient has received 3 cycles of bleomycin, etoposide and cisplatin.

Immature teratoma may remain asymptomatic or may present with acute pain in abdomen because of torsion, infection, rupture and malignant change.

More specifically, immature formations of teratomas are classified into three categories: firstly, lesions that include immature ectodermic tissue and neuroectodermal epithelial tissue in rosettes and tubules, secondly, masses that contain immature mesenchyme with immature cartilage, immature fat, osteoids and rhabdomyoblasts and in third one immature endodermal tissue as well as hepatic tissue, intestinal type epithelium with basal vacuolization and embryonic renal tissue

The coexistence of malignancy is often represented as teratoma with malignant transformation. Studies have been reported by H.J Norris et al they did a clinicopathological study of 58 patients having immature ovarian teratoma and its prognosis; [5] FF Nogales et al reported grade 2 ovarian immature endodermal teratoma in adolescent girls who were treated with triple chemotherapy; [6] M Kowai et al did a study to establish optimal management of immature teratoma. Shigeaki Iwanaga, Atsuko Shimada et al presented a case report in which the site of the tumor was uterine fundus while in other cases the tumours were found in the uterine cavity or the cervical canal. [7] In their case tumor with a broad stalk arose from the right surface of uterine fundus where as in our case report there was no stalk attached to the tumor.

The malignancy risk increases with the rate of increase of neuroepithelial tissues in immature teratoma. Follow up after treatment is usually based on clinical examination and symptoms with expert use of CT scans

CONCLUSION

Malignancy of immature teratoma in women <20 yrs old is confined between 0.2 and 1.4 per 100,000 while in women between 20-29 yrs old does not exceed the level of 2.2 per 100,000 although the tumour is rare; but in young adolescents the possibility of these teratomas should always be considered and multidisciplinary approach for their treatment should be

conducted. Based on this rare occurrence this case is being reported.

REFERENCES

1. Meryam ben, Amina Mohtaram, Jinane karmourn et al (2013) primary immature teratoma of uterus relapsing as malignant neuroepithelioma :case report oncol med.
2. Gheorghisan-Galateanu A, Terzea DC, Carsote M, Poiana (2013) Immature ovarian teratoma with unusual gliomatosis: J ovarian Res 6:28.
3. Sofoklis Stavrou, Ekaterini Domali, Ioannis Paraoulakis et al. (2016) Immature teratoma in a 21 year old woman: case report: Journal of general practice.
4. Quirk JT, Natarajan N: ovarian cancer incidence in the United States, 1992-1999. *Gynecol oncol* 2005,97:519-523.
5. Norris HJ, Zirkin HJ, Benson WL. Immature (malignant) teratoma of the ovary: a clinical and pathologic study of 58 cases. *Cancer* 1976: 37;2359-2372.
6. FF Nogales, MD Franciso et al, immature teratoma of the ovary with a neural component: a clinicopathologic study of 20 cases. *Human Pathology*. November 1976, Vol.7; Issue 6; 625-642.
7. Shigeaki Iwanaga, Atsuko shimada et al: a case report on uterine teratoma of the uterine fundus: *The Kurume Medical journal*: vol 40; pg 153-158:1993

How to cite this article: Gupta HP, Singh S, Mehra D. A case report on rare immature teratoma of ovary. *Int J Health Sci Res*. 2017; 7(8):488-491.
