

Case Report

Nail Patella Syndrome with Secondary Osteoarthritis of Hip - A Rare Case Report

Dr. Saranya C¹, Dr. Saravanan M², Dr. Rajeswari. S³

¹D.M. Postgraduate in Rheumatology, ²Assistant Professor, ³Director & Head, Institute of Rheumatology, Madras Medical College & Rajiv Gandhi Government General Hospital, Chennai

Corresponding Author: Dr. Saranya C

ABSTRACT

Nail-patella syndrome (NPS) or Hereditary onycho-osteodystrophy is a rare autosomal dominant condition characterised by skeletal and nail abnormalities and frequently renal involvement. Our patient presented with both hip and knee pain and on examination, he had features of nail dystrophy, hypoplastic patellae and hip arthritis. Radiological evaluation showed prominent iliac horns, femoral head abnormalities with early osteoarthritis of both hips. He responded with symptomatic therapy. Secondary osteoarthritis of hip joint due to structural abnormalities of femoral head was quite unusual in Nail-patella syndrome, hence this case was reported.

Keywords: Nail-patella syndrome, nail dystrophy, hypoplastic patellae, prominent iliac horns.

INTRODUCTION

Nail-patella syndrome (NPS) or Hereditary onycho-osteodystrophy is a rare autosomal dominant condition involving both ectodermal and mesodermal origin. ⁽¹⁾ The incidence of this syndrome at birth is estimated at 1/45000 and prevalence at 1/50000. ⁽²⁾ It is also known as Fong disease, Osterreicher-Turner syndrome or Turner-Kieser syndrome. This syndrome is characterised by skeletal and nail abnormalities and frequently renal involvement. ⁽³⁾ We report a case of Nail-patella syndrome who presented with hip and knee pain and was found to have hypoplastic patellae, prominent iliac horns and nail dystrophy. In addition to it, he had short and broad femoral head with subsequent development of early secondary osteoarthritis of both hip joints. Structural changes involving femoral head are less

frequently encountered in NPS, hence this case was reported.

CASE REPORT

A 24 year old male, presented with pain over both hip and knees for 2 months duration. The pain was mechanical in nature, aggravated by doing activities and relieved by taking rest. No history of any trauma in the past. He was born out of non-consanguineous marriage. Birth and developmental history was uneventful. On examination, patient had short stature with height of 148cms. Upper limb examination showed prominent medial epicondyle of both elbows with limitation in full supination of right forearm (figure 1). Loss of skin crease was noted over the dorsum of 2nd, 3rd and 4th DIP of both hands (figure 2). Examination of the nails showed dystrophic changes of both thumb nails (figure 3). He also had bilateral toe nail dystrophy (figure

4). Knee examination showed prominent sulcus in between femoral condyles (figure 5). On palpation, both Patellae were small and superiorly located. Examination of hip revealed positive Patrick's test (FABER), with pain localised to hip joint. There was painful limitation of internal rotation of both hips. The power of quadriceps, hamstrings and glutei muscles were normal.



Figure 1: Prominent medial epicondyle with restriction of complete supination in right forearm

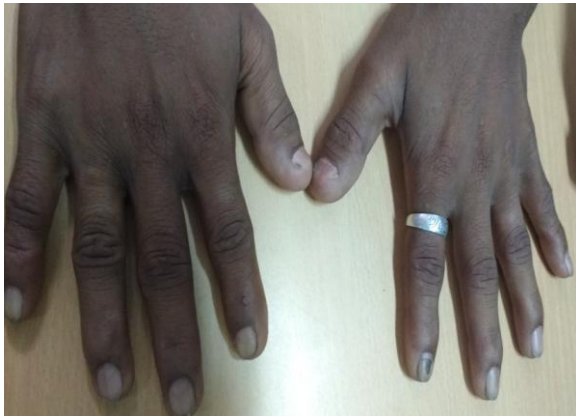

Figure 2: Loss of skin crease over DIP of 2nd, 3rd and 4th fingers

Blood investigations namely complete hemogram, erythrocyte sedimentation rate, C-reactive protein, blood urea and serum creatinines were normal. Urine routine, including protein creatinine ratio was normal. Ophthalmological evaluation was unremarkable. Radiograph of knees showed hypoplastic patella on both sides (figure 6). Radiograph of pelvis showed bilateral short and broad femoral head and bilateral prominent posterior iliac horns (figure 7). Ultrasound abdomen was normal. MRI pelvis with both hips revealed articular cartilage thinning of both femoral head and

acetabulum, short and broad femoral head and bilateral prominent iliac horns. No evidence of joint effusion or avascular necrosis of femoral head (figure 8). He was treated with analgesics, anti-resorptive therapy and other supportive measures. Regular physical therapy and follow up was advised.

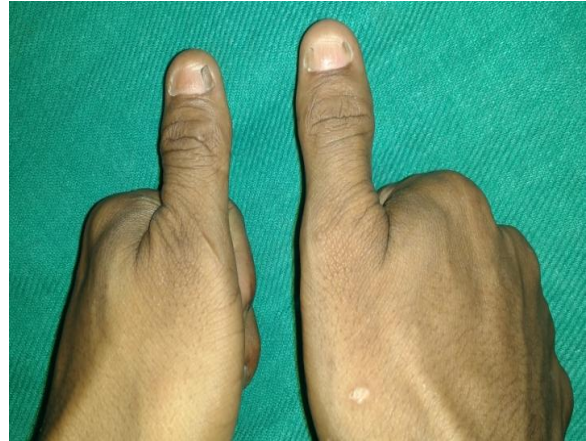

Figure 3: Thumb nail dystrophy

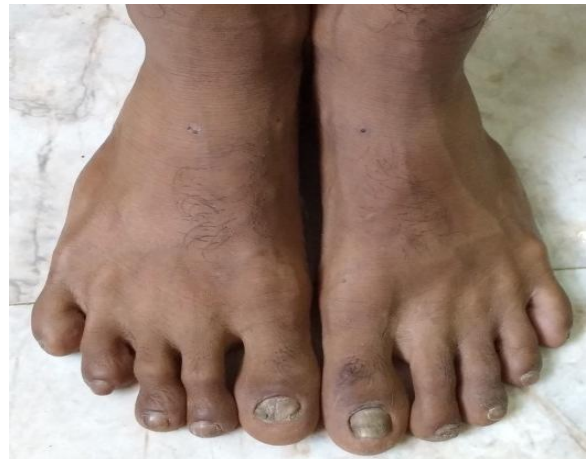

Figure 4: Toe nail dystrophy

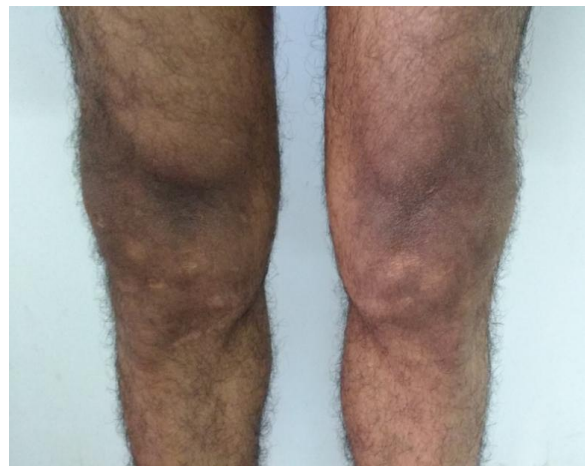


Figure 5: Prominent sulcus between the femoral condyles with superior displacement of patellae

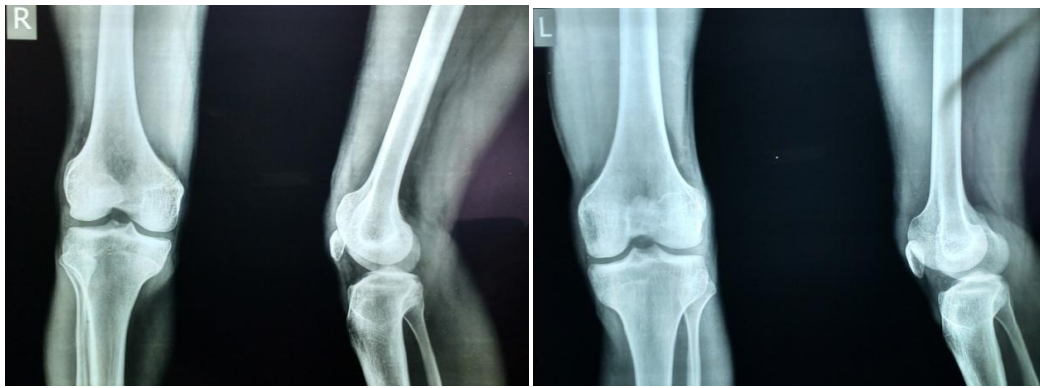

Figure 6: Radiograph of both knee showing hypoplastic patellae

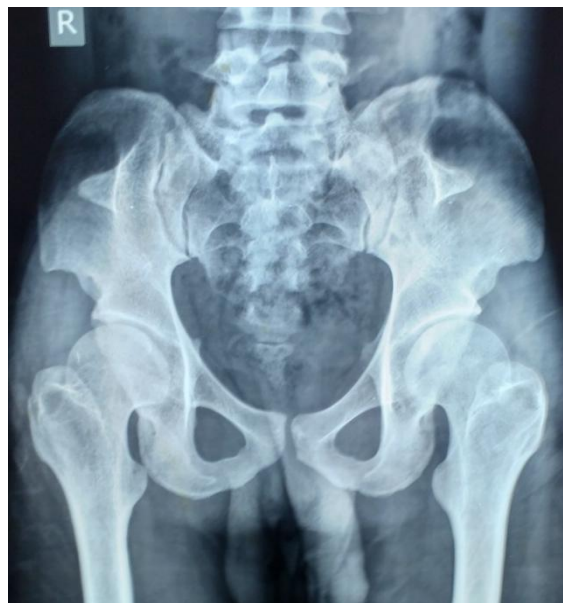

Figure 7: Radiograph of pelvis showed bilateral short and broad femoral head and bilateral prominent posterior iliac horns

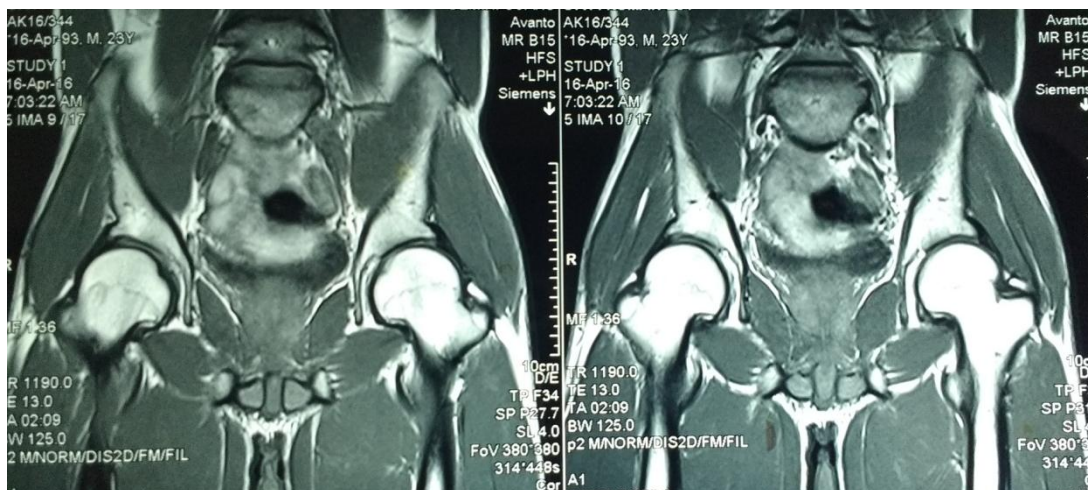


Figure 8: MRI Hips showing articular cartilage thinning on both the hip joint

DISCUSSION

Nail-patella syndrome or hereditary onycho-osteodystrophy is a rare genetic disorder that occurs due to mutations of the LMX1B gene located at chromosome 9q34. (4) LMX1B gene is a transcription factor that

plays an important role in dorso-ventral patterning of the limb and renal development. More than 140 heterozygous mutations have been reported so far. (5) NPS is characterised by three major features: Nail anomalies, skeletal abnormalities and

renal disease. Nail anomalies (80-90%) are bilateral and symmetrical; nails may be absent, hypoplastic, or dystrophic (discolouration, triangular lunulae, splitting, longitudinal or horizontal ridging, thinning). Nail may be separated into two halves by a longitudinal cleft or ridge of skin. The thumb nails are the most severely affected. Dysplasia of the toe nails is usually less frequent than the fingernails. They may also have distal digital changes (loss of the creases in the skin overlying the distal interphalangeal joint).

The most frequent skeletal abnormalities are absent or hypoplastic patellae and prominent iliac horns. Hypoplastic patella is seen located laterally or superiorly without actual dislocation. Recurrent subluxation or dislocation of the patella is also common, usually associated with poor development of vastus medialis. Prominent medial femoral condyle and tibial tuberosity with hypoplastic lateral femoral condyle may be seen. The pathognomonic skeletal feature of NPS is bilateral, symmetrical and prominent iliac horns. ⁽⁶⁾ These iliac horns are the bony processes that arise from the central part of the iliac bone, directed posteriorly and laterally. Elbow abnormalities may be asymmetrical which include limited extension, supination and pronation; posterior dislocation of radial head; cubitus valgus and pterygium of antecubital region. Rarely genu recurvatum, genu valgum, genu varum, hypoplasia of cruciate ligaments, pectus excavatum, scoliosis, increased lumbar lordosis, spondylosis, spondylolisthesis, spina bifida are observed in some cases. ⁽⁷⁾

Manifestations of renal disease include proteinuria and microscopic haematuria. Proteinuria occurs in 30% to 50% of cases. Of the patients with renal involvement, only 5% progress to end-stage renal disease (ESRD). ^(8,9) Other rare features include glaucoma, depression, attention deficit disorder, sensory neuropathy, gastrointestinal symptoms (constipation, irritable bowel syndrome),

lean habitus and difficulty to gain weight. NPS is diagnosed based on the characteristic clinical and radiological features. Molecular genetic testing to identify mutations of LMX1B gene can be done. ⁽¹⁰⁾ No specific therapy for NPS and symptomatic management is instituted based on the clinical manifestations. Surgical interventions may be required in selected cases.

Our patient had skeletal manifestations in the form of hypoplastic patellae, prominent iliac horns, along with dystrophic changes of both finger and toe nails. Since he had hip pain with restriction of movements, MRI hips was done, which revealed femoral head abnormalities with early degenerative changes in the form of articular cartilage thinning. He responded with symptomatic therapy along with regular physical exercises. He was advised for regular follow up to monitor the renal status and other complications.

CONCLUSION

This case was reported since our patient had osteoarthritis of both the hips secondary to structural abnormalities of femoral head which was quite unusual in Nail-patella syndrome.

REFERENCES

1. Sabnis SG, Antonovych TT, Argy WP, Rakowski TA, Gandy DR, Salcedo JR. Nail-patella syndrome. Clin Nephrol 1980; 14: 148-153
2. Levy M, Feingold J. Estimating prevalence in single-gene kidney diseases progressing to renal failure. Kidney Int. 2000; 58: 925.
3. Sweeney E, Fryer A, Mountford R, Green A, McIntosh I. Nail patella syndrome: a review of the phenotype aided by developmental biology. J Med Genet 2003; 40: 153-162.
4. Vollrath D, Jaramillo-Babb VL, Clough MV, et al. Loss-of-function mutations in the LIM-homeodomain gene, LMX1B, in nail-patella syndrome. Hum Mol Genet 1998; 7:1091.
5. Hamlington JD, Jones C, McIntosh I. Twenty-two novel LMX1B mutations

- identified in nail patella syndrome (NPS) patients. *Hum Mutat* 2001; 18: 458.
6. Lucas GL, Opitz JM, Wiffler C. The nail patella syndrome. Clinical and genetic aspects of 5 kindreds with 38 affected family members. *J Pediatr* 1996; 68: 273-88.
 7. Little EM. Congenital absence or delayed development of the patella. *Lancet* 1897; 2:781.
 8. Lemley KV. Kidney disease in nail-patella syndrome. *Pediatr Nephrol* 2009; 24: 2345-2354.
 9. Hoyer JR, Michael AF, Vernier RL. Renal disease in nail-patella syndrome: clinical and morphologic studies. *Kidney Int* 1972; 2: 231-238.
 10. Dreyer SD, Zhou G, Baldini A, et al. Mutations in LMX1B cause abnormal skeletal patterning and renal dysplasia in nail patella syndrome. *Nat Genet* 1998; 19: 47

How to cite this article: Saranya C, Saravanan M, Rajeswari. S. Nail patella syndrome with secondary osteoarthritis of hip - a rare case report. *Int J Health Sci Res.* 2017; 7(8):479-483.
