

---

*Case Report*

## Mediastinal Pancreatic Pseudocyst

**B. Ananda Rama Rao<sup>1</sup>, P. Sai Kumar<sup>2</sup>, M. Datta Prasad<sup>2</sup>**

<sup>1</sup>Prof of Surgery; <sup>2</sup>Residents in Surgery,  
SVS Medical College, Mahabub Nagar, Telangana, India.

Corresponding Author: B. Ananda Rama Rao

---

### ABSTRACT

A well-known complication of both acute and chronic pancreatitis is pancreatic pseudocyst. Acute or chronic inflammation or any injury of pancreas leads to collection of fluid. In very rare instances we find extension of pancreatic pseudocyst into the mediastinum. A mediastinal pseudocyst can cause symptoms due to compression or invasion of surrounding structures. Approximately only 50 cases of mediastinal extension of the pancreatic pseudocyst in the world literature are reported till date. We discuss here about a 50 years old male with complaints of pain abdomen, lower chest non cardiac pain, shortness of breath and gangrene of left hand finger tips since one month. Colour Doppler of upper limbs showed decreased flow in distal ulnar and radial arteries suggestive of Digital vasculitis, which improved on treatment with heparin. Chest x-ray showed mass like lesion in the mediastinum. USG abdomen suggestive of 5X4 cm Pancreatic Pseudocyst. CT scan abdomen was done, which showed large Pancreatic Pseudocyst in retro gastric position. This patient was managed surgically. Mid line incision was given and Cyst fluid aspirated. Post operatively series of x-rays were taken and eventually found that the pseudocyst disappeared completely after 6 months.

**Key words:** Acute Pancreatitis, Chronic pancreatitis, Pseudocyst, Mediastinal Extension,

### INTRODUCTION

Pseudocyst formation is a common complication of both acute and chronic pancreatitis. Usually pseudocysts are seen in peripancreatic areas and very rarely they reach the mediastinum; exact incidence being unknown. [1] Pseudocysts are cystic cavities encased by reactive fibrous tissue. The presence of a well-defined wall allows to distinguish a pseudocyst from an acute fluid collection seen in cases of acute pancreatitis. Acute fluid collection is distinguished from acute and chronic pseudocysts by Atlanta classification. Acute fluid collection appears early in the course of acute pancreatitis and lacks a wall of inflammatory tissue, whereas acute pseudocysts are composed of wall of inflammatory tissue containing pancreatic fluid enclosed within a wall. They occur as

a result of acute pancreatitis or trauma to the pancreas. Chronic pseudocysts, are also composed of pancreatic fluid and inflammatory tissue wall, but occur only as a consequence of chronic pancreatitis without any attack of preceding acute pancreatitis. [1] Disruption of pancreatic duct due to inflammatory injury leads to leakage of pancreatic secretions rich in amylase. Thoraco-pancreatic fistulae occur due to posterior disruptions while anterior disruptions produce pancreatic ascites. Based on the termination site of the fistula the thoraco-pancreatic fistulas are divided into four types A) Pancreatico-pleural, B) Mediastinal pseudocyst, C) Pancreatico-bronchial, and D) Pancreatico-pericardial. Mediastinal pancreatic pseudocyst (MPP) by way of its unique location can present with symptoms of dysphagia, chest pain,

palpitations and in extreme cases pericardial effusion, tamponade, and respiratory distress. [2,3] High index of suspicion is often needed in diagnosing this entity. Pancreatic ductal morphology and its communication with the pseudocyst holds the major role for successful management. We discuss here about managing a 50 years old patient with mediastinal extension of pancreatic pseudocyst.

### MATERIAL &METHODS

A 50 years old male with history of chronic alcohol intake presented to surgical

OPD with complaints of pain abdomen, lower chest non cardiac pain, shortness of breath and gangrene of left hand finger tips since one month (Fig 1&2). The same patient presented six months back with features of chronic pancreatitis plus left pleural effusion managed by ICD. Patient got relieved of symptoms so he was discharged. Three months back he again presented with acute on chronic pancreatitis and gangrenous changes of left hand finger tips.

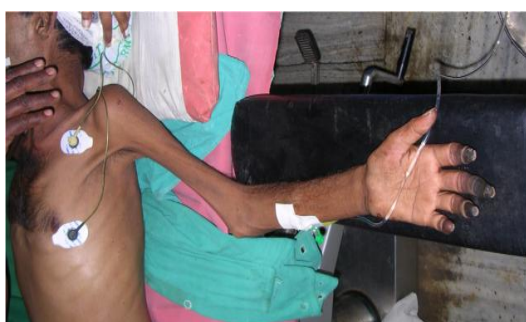

Figure no:1

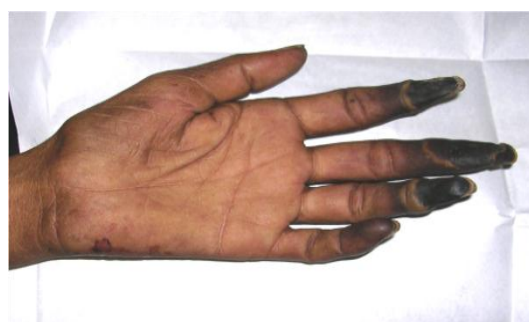

Figure no:2

Colour Doppler of upper limbs showed decreased flow in distal ulnar and radial arteries suggestive of Digital vasculitis, which improved on treatment with Heparin. USG abdomen suggestive of

5X4 cm Pancreatic Pseudocyst. CT scan abdomen and chest were done, which showed large Pancreatic Pseudocyst in retro gastric position extending into chest (Fig 3&4)

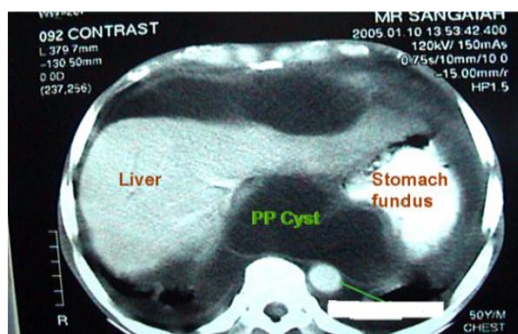


Figure no:3

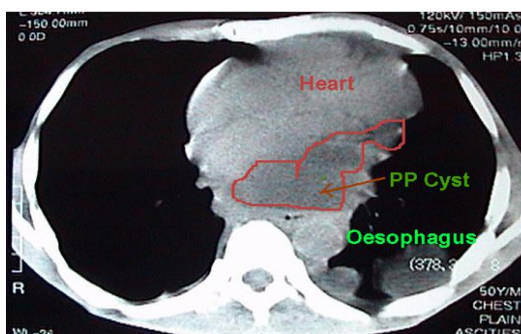


Figure no:4

Now again patient presented with the complaints of pain abdomen, lower chest non cardiac pain, shortness of breath and gangrene of left hand finger tips since one month.(Fig 1&2)On examination, abdomen was distended with severe epigastric tenderness and with no palpable mass, no organomegaly and no palpable lymph nodes.

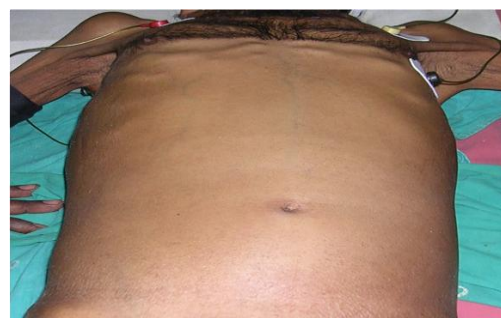

Figure no:5

On auscultating the chest there were decreased breath sounds in left mid & basal zones. Routine haematological and biochemical tests were done Sr amylase-1830SU/dl, LFT within normal range, Sr Proteins-7.2G%; (Alb 2.4, Glob 4.8), TLC-9800/cmm, DLC-Polymorphs74, Lymphocytes22, Eosinophils2, Monocytes 1%, FBS-70mg%, Screat-1.1mg%, Sr electrolytes-Na-138, K-3.9, meq/L. X ray chest showed lenier opacities in Left mediastinum. (Fig 6&7)

USG Chest suggestive of encysted effusion in left mid zone 2D echo-extrinsic compression of left atrium and ERCP-main pancreatic duct narrow? Stricture. Biliary tree appeared to be normal. This patient was managed surgically. Mid line incision from xiphoid process to umbilicus taken,

pseudocyst was identified and cyst wall opened. Cystic fluid aspirated and rubber catheter placed in parahiatal opening of cyst connected to draining system outside. (Fig 8&9) Course of anti-biotics were started and series of x-rays were taken during post operative care. At the end of sixth month, the pseudocyst disappeared. (Fig 10)

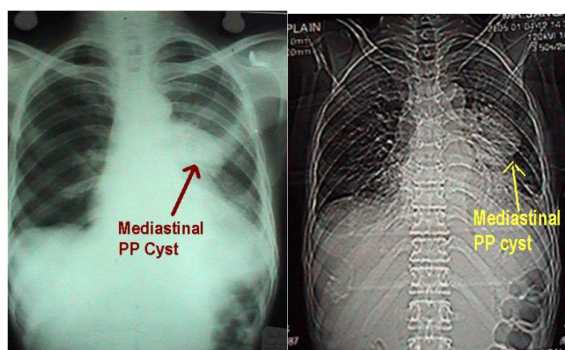


Figure no:6

Figure no:7

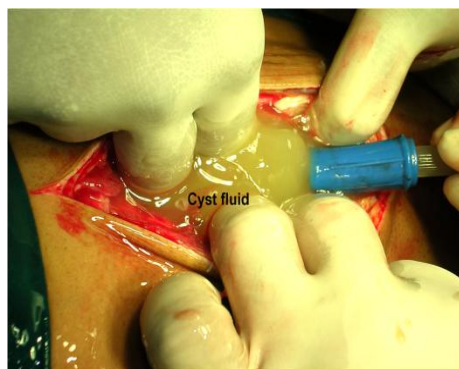


Figure no:8

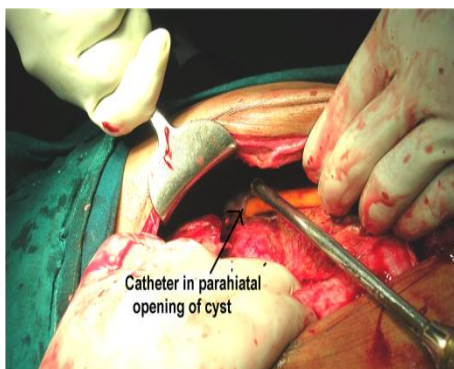


Figure no:9

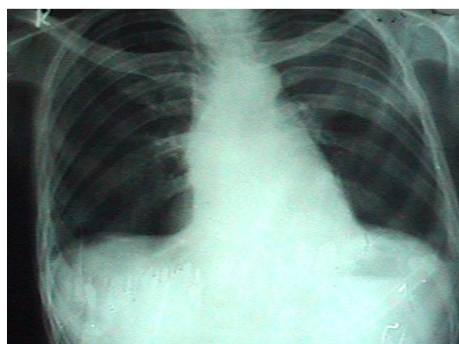


Figure no:10

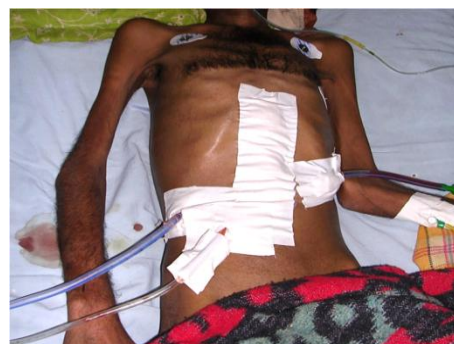

Figure no:11

## DISCUSSION

In 1951 mediastinal pancreatic pseudocyst was first described, [3] and it remains a rarest complication of pancreatitis. Alcohol-induced pancreatitis is responsible for the majority of cases in adults. post-traumatic occurrence is also not uncommon. [4] Carcinoma pancreas, gall

stone pancreatitis, and idiopathic causes composing the remainders. [5] Pathophysiologically, mediastinal pseudocysts occur after rupture of the pancreatic duct posteriorly into the retroperitoneal space. Esophageal or aortic hiatus are the two routes through which the pancreatic fluid enters the mediastinum. [6,7]



Therefore, the posterior mediastinum is the most common location of the mediastinal pseudocysts.

Pseudocyst formation is a result of elevated intraductal pressure due to Pancreatic ductal obstruction because of stricture or stones, Pseudocyst can complicate 7% to 15% of episodes of acute pancreatitis and 20% to 25% of cases of chronic pancreatitis. In the majority of reported cases, these cysts were diagnosed in patients presenting symptomatically such as abdominal, chest and back pain, dyspnea, cardiac tamponade, dysphagia, odynophagia, cough and weight loss. [1,4,7-11]

Contrast enhanced CT scans are more specific and superior to ultrasound for diagnosing mediastinal pseudocysts. Chest X-ray can reveal a space-occupying mass in the posterior or middle mediastinum. Magnetic resonance imaging and magnetic resonance cholangiopancreatography (MRCP) can help identify the connection between the mediastinal and abdominal pseudocyst in cases where it is not so evident on CT scan. MRCP has similar sensitivity to Endoscopic retrograde cholangiography (ERCP) and has the advantage of providing images of the ducts in their natural state because it does not involve the distension of the ducts by the injected contrast media which occurs with ERCP.

Newer techniques such as Endoscopic ultrasonography(EUS) is increasingly being used in evaluating cystic lesions of the pancreas given its advantages in delineating intracystic contents and wall structures. [12] An elevated amylase level in the aspirated fluid from a mediastinal pseudocyst confirms the diagnosis. [13]

Primary therapeutic options include surgery with internal or external drainage of the pseudocysts (cystogastrostomy and cystoenterostomy), transcutaneous, transpapillary, transgastric and transesophageal endoscopic drainage. [3,4,6,8,16] Transhiatal drainage of mediastinal pseudocysts has been in practice and showed good results. [16] Endoscopic

drainage procedures has recurrence of >5% and complication rate of 10% with better tolerability than transcutaneous procedure. Further repeat EUS after resolution of mediastinal pseudocysts has shown significant periesophageal fibrosis and rarely a stricture needing endoscopic Bougiedilatation. [8] Other modalities of treatment are Usage of somatostatin analog and bromhexine hydrochloride as well as abstinence from alcohol and parenteral nutrition showed resolution of pseudocysts. [10,14,15]

## CONCLUSION

Mediastinal pancreatic pseudocyst is a very rare complication of acute pancreatitis. MPP should be suspected in pancreatitis patients presenting with dysphagia, dyspnae, atypical chest pain on finding a thin walled cystic lesion in posterior mediastinum in continuity with pancreas and increased levels of amylase on cystic contents analysis. It gives a definitive diagnosis for this unusual and potentially life threatening presentation of a pancreatitis and helps in choosing accurate mode of management.

## REFERENCES

1. Sandberg AA, Dervenis C.: Pancreatic pseudocysts in the 21st century. Part 1: classification, pathophysiology, anatomic considerations and treatment. JOP. 2004;5:8–24.
2. A. V. Ajmera and T. A. Judge,: Mediastinal extension of pancreatic pseudocyst-a case with review of topic and management guidelines,” American Journal of Therapeutics, 2012, vol. 19, no. 5, pp. e152–e156.
3. Topa L, Laszlo F, Sahin P, Pozsar J.: Endoscopic transgastric drainage of a pancreatic pseudocyst with mediastinal and cervical extensions. Gastrointest Endosc. 2006;64:460–463.
4. Komtong S, Chanatrirattanapan R, Kongkam P, Rerknimitr R, Kullavanijaya P.: Mediastinal pseudocyst with pericardial effusion and dysphagia treated by endoscopic drainage. JOP. 2006;7:405–410.

5. Balthazar EJ. Pancreatitis. In: Gore RM, Levine MS, editors. Text Book of Gastrointestinal Radiology. 2<sup>nd</sup> ed. Philadelphia: WB Saunders; 2002. p. 1785-7.
6. Johnson RH, Jr, Owensby LC, Vargas GM, Garcia-Rinaldi R.: Pancreatic pseudocyst of the mediastinum. *Ann Thorac Surg.* 1986;41:210–212.
7. Bhasin DK, Rana SS, Chandail VS, Nanda M, Sinha SK, Nagi B.: Successful resolution of a mediastinal pseudocyst and pancreatic pleural effusion by endoscopic nasopancreatic drainage. *JOP.* 2005;6:359–364.
8. Rose EA, Haider M, Yang SK, Telmos AJ.: Mediastinal extension of a pancreatic pseudocyst. *Am J Gastroenterol.* 2000;95:3638–3639.
9. Chettupuzha AP, Harikumar R, Kumar SK, Thomas V, Devi SR.: Pancreatic pseudocyst presenting as odynophagia. *Indian J Gastroenterol.* 2004;23:27–28.
10. Tsujimoto T, Takano M, Tsuruzono T, Hoppo K, et al.: H. Mediastinal pancreatic pseudocyst caused by obstruction of the pancreatic duct was eliminated by bromhexine hydrochloride. *Intern Med.* 2004;43: 1034–1038.
11. Suga H, Tsuruta O, Okabe Y, Saitoh F, et al.: A case of mediastinal pancreatic pseudocyst successfully treated with somatostatin analogue. *Kurume Med Journal.* 2005;52:161–164.
12. Musana KA, Yale SH, Abdulkarin A.: Successful endoscopic treatment of mediastinal pseudocysts. *Clin Med Res.* 2004;2:119–123.
13. Ingram M, Arregui ME: Endoscopic ultrasonography. *Surg Clin North Am.* 2004;84:1035–1059.
14. Saftoiu A, Ciurea T, Dumitrescu D, Stoica Z: Endoscopic ultrasound-guided transesophageal drainage of a mediastinal pancreatic pseudocyst. *Endoscopy.* 2006;38:538–539.
15. Baron TH, Wiersema MJ.: EUS-guided transesophageal pancreatic pseudocyst drainage. *Journal of Gastrointest Endosc.* 2000;52:545–549.
16. Bardia A, Stoikes N, Wilkinson NW.: Mediastinal pancreatic pseudocyst with acute airway obstruction. *Journal of Gastrointest Surg.* 2006;10:146–150.

How to cite this article: Rao BAR, Kumar PS, Prasad MD. Mediastinal pancreatic pseudocyst. *Int J Health Sci Res.* 2017; 7(7):391-395.

\*\*\*\*\*