

Case Report

## Hemangioma of Tongue: A Case Report

Dr. Ghosh Tuhina<sup>1</sup>, Dr. Saha Subrata<sup>2</sup>, Dr. Sarkar Subir<sup>3</sup>

<sup>1</sup>Post Graduate Trainee Third Year, <sup>2</sup>M.D.S, Professor, <sup>3</sup>M.D.S, Professor & HOD,  
Department of Pedodontics and Preventive Dentistry, Dr R Ahmed Dental College and Hospital, Kolkata, India.

Corresponding Author: Dr. Ghosh Tuhina

### ABSTRACT

Hemangiomas are benign tumors of vascular origin that primarily develops during infancy and childhood. It is most commonly seen in the head and neck region and rarely in the oral cavity. Hemangiomas in the oral cavity are always of clinical importance and require early diagnosis and appropriate treatment. Tongue hemangiomas show a great risk for patients since the tongue being an inquisitor mobile organ is more susceptible to trauma and subsequent complications. Here we have presented a case of hemangioma in a 5-year-old female patient occurring on posterior dorsal surface of tongue.

**Key words:** Hemangioma, surgery, tongue.

### INTRODUCTION

Hemangioma (Greek: Haima-blood; angeion vessel, omatumor) is a term that encompasses a heterogeneous group of clinical benign vascular lesions that have similar histological features. <sup>[1]</sup> The origin of hemangioma is debatable. While some authors believe it to be a true neoplasm, others are of the opinion that it is a hamartoma due to its resemblance with normal vessels and limited growth potential. Hemangiomas usually appear 2-4 weeks after birth; grow rapidly till the age of 6 – 8 months and then slowly develop. By age 5-8 years, they start to involute and spontaneously regress in 70% of the cases. <sup>[2]</sup> The majority of hemangiomas involve the head and neck. They are relatively rare in the oral cavity but intraorally may occur on the tongue, lips, buccal mucosa, gingiva and palatal mucosa. <sup>[3]</sup> Hemangiomas are found in greater frequency in girls, white children, premature infants, twins, and those born to mothers of higher maternal age. <sup>[4]</sup>

Clinically hemangiomas appear as soft mass, smooth or lobulated, and sessile or pedunculated and may vary in size from a few millimeters to several centimeters. <sup>[5]</sup> The superficial hemangiomas are often lobulated, and blanch under finger pressure and the deeper lesions tend to be dome-shaped with normal or blue surface coloration, and they seldom blanch. Pedunculated hemangiomas of the oral cavity are extremely rare.

Historically, hemangiomas have been classified in a variety of ways. According to Enzinger and Weiss, hemangiomas are broadly classified into capillary, cavernous, and miscellaneous forms like verrucous, venous, arteriovenous hemangiomas, and so forth. <sup>[6]</sup> The capillary type is the most common and is characterized by the presence of small vessels surrounded by a connective tissue deficient in elastin, causing small, localized lesions. Cavernous hemangiomas are composed of large thin-walled vessels causing extensive infiltrated injuries. <sup>[7]</sup>

The purpose of this paper is to present a case of growth diagnosed as hemangioma on the posterior dorsal surface of tongue in a 5-year-old girl and discuss the various treatment modalities.

### CASE REPORT

A 5-year-old female patient reported to the Department of Pedodontics and Preventive Dentistry with the chief complaint of swelling on the posterior surface of tongue and difficulty in eating spicy food. According to her parents the swelling was present for last four years and has remained constant in size since then but the color has changed from dark red to red to pinkish color. There was no history of pain associated with the swelling or difficulty in swallowing of food.

On general examination, the patient was normally built for her age without any relevant medical history. On clinical examination, extra orally there was presence of port wine stain extending from lower part of nose to upper lip (Figure 1). Intraorally, a growth measuring 3 cm x 3 cm was noted on the dorsal surface of posterior two-third of the tongue (Figure 2). The growth appeared to be sessile, reddish pink in color and without any ulceration. It was soft to palpate and showed blanching on application of pressure. A provisional diagnosis of hemangioma of tongue was made based on clinical findings. On investigation, magnetic resonance imaging (MRI) revealed large ill-defined heterogeneous altered signal intensity (hypotense in T1 and hypertense in T2 and STIR) enhancing lesion was noted in right side of tongue with extension into right masticator space which gave support to the clinical diagnosis of haemangioma of tongue (Figure 3). Further diagnostic modalities like Doppler study and Computerized Tomography angiography study were suggested before any definitive treatment was planned but the patient didn't report back for further treatment.

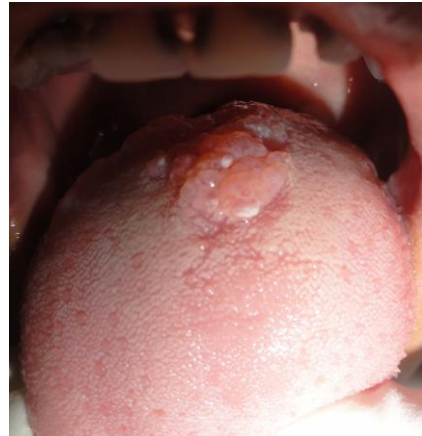


Figure 1. Extraoral photograph showing port wine stains extending from lower part of nose to upper lip.

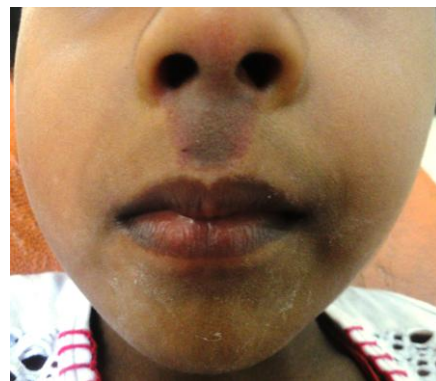

Figure 2. Intraoral picture showing a growth on the dorsal surface of posterior two-third of the tongue.

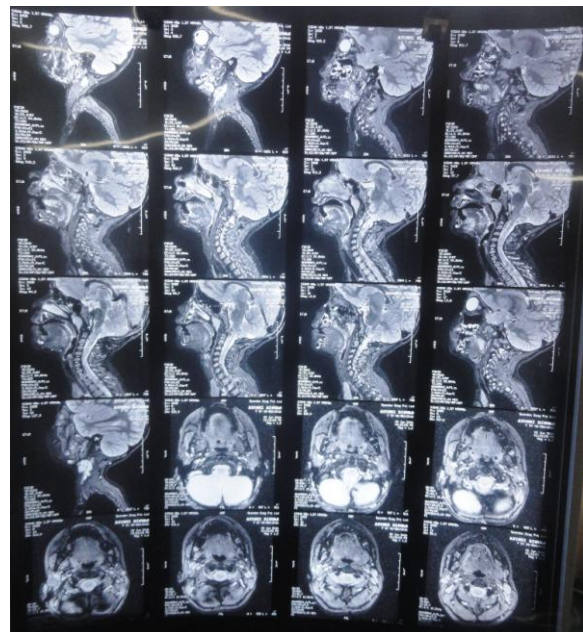


Figure 3. Magnetic resonance imaging (MRI) revealed large ill-defined heterogeneous altered signal intensity enhancing lesion in right side of tongue with extension into right masticator space.

### DISCUSSION

Amongst the various intraoral sites, the occurrence of hemangioma on the

tongue is extremely rare. Being a mobile inquisitive organ, the tongue is more susceptible to minor trauma and consequent bleeding and ulceration, swallowing difficulties, breathing and aesthetic problems.

Hemangiomas may mimic other lesions both clinically and histopathologically. The differential diagnosis of hemangiomas includes pyogenic granuloma, chronic inflammatory gingival hyperplasia, telangiectasia and even squamous cell carcinoma. Hemangiomas can be easily confused with pyogenic granuloma, which is a reactive lesion that develops rapidly, bleeds easily and is usually associated with inflammation and ulceration. Clinically, it is often lobulated, pedunculated and red to purple and it may be hormone sensitive.<sup>[5]</sup> In addition, hemangiomas may be confused with the vascular-appearing lesions of the face or oral cavity as in Sturge-Weber syndrome.<sup>[8]</sup> They are often located in the territory of the branches of the trigeminal nerve. Ocular and cerebral vascular lesions may be found in such cases.

Arteriovenous malformations should also be considered in the differential diagnosis of haemangiomas. Hemangiomas are often circumscribed lesions which rarely affect bone and intraorally are most commonly present on tongue, lips and buccal mucosa. A lesion with a thrill or bruit or with an obviously warmer surface is most likely a special vascular malformation, called arteriovenous aneurysm or arteriovenous malformation, with direct flow of blood from the venous to the arterial system, bypassing the capillary beds. Also arteriovenous malformations are poorly circumscribed lesions which may affect bone also. Therefore precise diagnosis of the type of vascular lesion is important because it may influence treatment considerably.

Management of oral hemangiomas varies considerably depending on the age of the patient, the extent and type of lesions as well as their clinical characteristics. Many

congenital hemangiomas have been reported to undergo spontaneous regression at an early stage. Treatment is indicated only under some conditions where esthetic disfigurement, repetitive bleeding and palpable mass are a matter of concern. Treatment of oral hemangiomas can be divided into two broad categories: medical treatment and surgical or invasive treatment. The two primary medical treatments in the treatment of proliferating hemangiomas in infants and children are steroids and beta-blocker therapy. High doses of systemic or intralesional steroids are the first-line treatment, and a dramatic response is observed in 30% of patients. The dosage commonly used is 3-5mg/kg per day of oral prednisolone between the first & thirtieth months.<sup>[9]</sup> Beta-blockers, most specifically propranolol, have been in use since mid 2008 for infants with severe or disfiguring hemangiomas. Beta-blockers can cause rapid involution of hemangiomas, but may be contraindicated in patients with malformations of the great vessels. Hypotension and bradycardia may occur. 2–3 mg/kg/day propranolol should be administered, divided in 2–4 doses per day. Duration of therapy varies from 2-10 months.<sup>[10]</sup>

When there is no response to the systemic treatment or if there is an aesthetic complaint, surgery is indicated. Complete surgical excisions are a mainstay of treatment of vascular malformations if they are small and amenable to such therapy. Alternative treatment modalities include laser therapy, cryotherapy, embolisation and use of sclerosing agents.<sup>[5,11]</sup> The prognosis of haemangiomas is good as it rarely recur after adequate removal.

## CONCLUSION

Hemangiomas of the oral soft tissues may mimic other lesions clinically and even histologically. Early detection and biopsy are crucial in determining the clinical behavior of the lesion and potential complications. The treatment modality should be planned according to the

diagnosis and prognosis of the particular vascular malformation.

#### REFERENCES

1. Enzinger FM, Weiss SW. Soft tissue tumors. 3rd edition. St Louis: Mosby; 1995:581-6.
2. Dorigatti E, Molon RS, Conte Neto N, Gabrielli MAC, Hochuli Viera E. Lip cavernous hemangioma in a young child. *Braz Dent J.* 2010; 21(4):370-4.
3. Eivazi B, Ardelean M, Baumler W, Berlien HP, Cremer H, Elluru R, et al. Update on hemangiomas and vascular malformations of the head and neck. *Eur Arch Otorhinolaryngol.* 2009; 266(2):187-97.
4. Acikoz A, Sakkaliagolu U, Ozdamar S, et al. Rare benign tumors of the oral cavity—capillary hemangioma of the palatal mucosa: a case report. *Intl J Paed Dent* 2000; 10:161–5.
5. Neville BW, Damm DD, Allen CM, Bouquot JE. *Oral Maxillofac Path.* 2nd edition. Philadelphia: WB Saunders; 2002:447-9.
6. Enzinger FM, Weiss SW. *Soft Tissue Tumours.* 5<sup>th</sup> ed. St. Louis: CV Mosby.; 2001.
7. Redondo P. Clasificación de las anomalías vasculares (tumores y malformaciones): características clínicas e historia natural. *An Sist Sanit Navar* 2004; 27 Suppl 1:9-25.
8. Bhansali RS, Yeltiwar RK, Agrawal AA: Periodontal management of gingival enlargement associated with Sturge-Weber syndrome. *J Periodontol* 2008, 79:549-55.
9. Zhou Q, Yang XJ, Zheng JW, Wang YA, Zhang ZY. Short-term high-dose oral prednisolone on alternate days is safe and effective for treatment of infantile hemangiomas. *J Oral Maxillofac Surg.* 2010; 109:166-7.
10. Le´aute´-Labre`ze, E Dumas de la Roque, T Hubiche, F Boralevi, JB Thambo, A Taieb. Propranolol for severe haemangiomas of infancy. *N Engl J Med.* 2008; 358(24):2649–51.
11. Shafer’s textbook of oral pathology, 7th ed. Elsevier; 2012, p.144–8

How to cite this article: Tuhina G, Subrata S, Subir S. Hemangioma of tongue: a case report. *Int J Health Sci Res.* 2017; 7(7):366-369.

\*\*\*\*\*