

Comparison of Cranio-Cervical Posture and Upper Cervical Range of Motion in Class I and Class II Skeletal Malocclusion

Badal Sonawane¹, Shreevidya Karthik², Karthik Balasubramanian³,
Loveleen Waghule¹

¹Physiotherapy Intern, School Of Physiotherapy, D.Y Patil University, Nerul, Navi Mumbai, Maharashtra, India

²Assistant Professor, School Of Physiotherapy, D.Y Patil University, Nerul, Navi Mumbai, Maharashtra, India

³Lecturer, YMT Dental College and Hospital, Dr. G.D. Pol Foundation, Kharghar, Navi Mumbai, Maharashtra.

Corresponding Author: Shreevidya Karthik

ABSTRACT

Jaws form important component of skull, which is connected with rest of the spine through cervical vertebrae. Evidence on relationship between incongruent arrangement of upper and lower jaws i.e. skeletal malocclusion and cranio-cervical posture in Indians is limited. Restriction in upper cervical mobility due to cervical postural abnormalities is also not known. This study aimed to identify cranio-cervical postural abnormalities and restriction of upper cervical mobility in skeletal malocclusion. Methods: 24 participants (13 in Class I and 11 in Class II) were included in this study. Lateral cephalograms were utilised to measure the cranio-cervical angle (CCA) Upper cervical mobility was measured using Cervical Range of Motion (CROM) device during Flexion Rotation Test (FRT). Comparison between mean values of CCA and FRT of Class I and Class II skeletal malocclusion values were done using student's t-test. Correlation between CCA and FRT ranges were analysed using Pearson's correlation co-efficient. Results: Mean of the CCA and FRT ranges were found to be affected in Class II. Mean CCA of Class II subjects was 94.36 ± 4.08 . Mean of FRT ranges on right and left sides were 39.66 ± 2.08 and 39.81 ± 2.33 respectively. A high and significant correlation was found between CCA and FRT ranges on both right ($r = 0.78$; $p < 0.001$) and left side ($r = 0.69$; $p < 0.001$). Conclusion: CCA and FRT ranges were significantly reduced in people with skeletal Class II malocclusion as compared to skeletal Class I. Strong positive correlation was found between CCA and upper cervical range of motion.

Keywords: Atlanto-occipital joint, skeletal malocclusion, cranio-cervical angle, lateral cephalogram, flexion rotation test.

INTRODUCTION

Malocclusion is a result of an interaction between jaw position and the position assumed by the teeth, as they erupt, which is again affected by jaw relationships. Angle's system of classification provides an orderly way to classify malocclusions. Although Angle's system involves assessment of first molar to classify, a broader basis for assessment is skeletal or

radiographic assessment of malocclusions using angle's principles. According to this there are three main types of skeletal malocclusions viz. Class I, Class II and Class III. In Class I malocclusion, there is simultaneous protrusion of the upper and lower jaw. In Class II malocclusion, there is protrusion of the upper jaw or maxilla in comparison to the lower jaw and in Class III, there is protrusion of the lower jaw or

the mandible as compared to the upper jaw. [1]

The upper cervical spine is formed by atlanto-occipital joint and the atlanto-axial joint. [2] There are two types of spinal curve in the human body viz. Primary curve & the Secondary curve. A human baby is born with primary curve known as kyphotic curve. Later, with normal development, this curve only persists in thoracic and sacral regions. This curve and consequently cervical posture is affected by various factors like cranio-facial morphology, orthodontic therapy, use of anterior repositioning devices etc. [3] Genetic and environmental factors affect variations in cranio facial morphology. The environmental and genetical influence on the cranio cervical posture has been studied extensively in the past. Studies on relationship between spinal posture and the morphological aspects of the face have usually focused on relationship between the spinal posture and vertical dimensions of face and consequently, the divergence and inclination of mandible and maxillary bases. [3] Most of the studies have found anteriorization of the head, meaning upper cervical extension posture in skeletal Class II and posteriorization of head in skeletal Class III malocclusion. (1,4,5) All these studies were done on populations of different geographical locations. However, there is dearth of evidence regarding the relationship between skeletal malocclusions and cranio cervical posture in Indian population.

Faulty postures are identifiers of muscle imbalances and altered soft tissue extensibility around the joints in malalignment. This has been noted in the upper cervical region too. Kee IK and Byun JS et al have documented decrease in upper cervical mobility as a result of alterations in craniocervical posture in teenage population. [6] Presence of a similar effect on upper cervical mobility due to cervical postural abnormalities if found, in people with skeletal malocclusions is not known. This study aimed to identify cranio-cervical

postural abnormalities and restriction of upper cervical mobility in skeletal malocclusions.

MATERIALS & METHODS

This study was a cross-sectional observational study, wherein subjects were divided into two groups. 13 subjects were incorporated in Class I group and 11 subjects in Class II group through convenience sampling within a duration of three months. Subjects were grouped on the basis of diagnosis made with the help of lateral cephalogram, from the outpatient department of the Department of Orthodontics & Dentofacial Orthopaedics and few private dental centers in Thane district. Subjects with following conditions were excluded from the study:

- 1) History of previous orthodontic treatment or orthognathic surgery
- 2) Neuromuscular disease or temporomandibular joint disorder
- 3) Presences of wound, burns, or scarring in the head and neck region
- 4) Cervical trauma/surgery
- 5) Jaw trauma
- 6) Temporal mandibular joint dysfunction
- 7) Congenital cervical anomaly
- 8) Individuals with pacemakers or other metal implants in body

Procedure-

Lateral cephalogram was used to assess the cranio-cervical angle. The angle was analysed by tracing the following landmarks on a butter paper superimposed on the lateral cephalogram over a source of light:

A line was drawn from the base of the occipital bone to the posterior nasal spine (McGregor plane). Another line was drawn between apex of the odontoid process of the second cervical vertebra C2 (Axis) and the most inferior point of the anterior side of the body of the Axis (odontoid plane). The lower posterior angle between the above lines was measured with the help of a protractor. This angle indicates the Cranio-Cervical angle. (Fig 1)

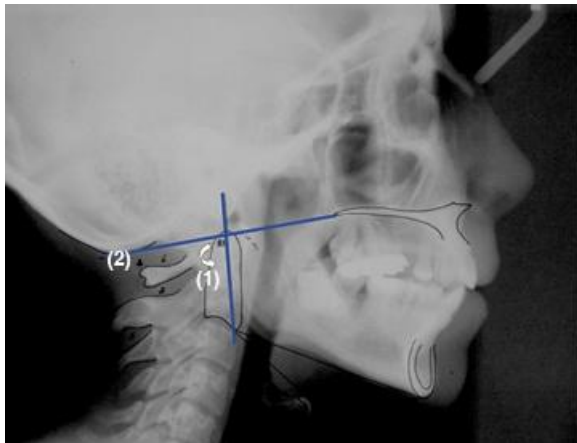


Fig1: Measurement of Cranio-cervical angle on Lateral Encephalogram: Lower posterior angle formed by odontoid plane (1) and McGregor plane (2).

The procedure for flexion rotation test (Fig 2) was explained to the subjects. CROM device was fitted on the head of the subjects. The flexion-rotation test was performed with the subject lying supine on a physiotherapy treatment table. Subjects were asked to relax as much as possible. Their neck was moved to the end range cervical flexion by the examiner. In this flexed position the head and neck were passively rotated to the end range, till comfortable limits. The ranges were recorded on the CROM. Same movements were repeated for three times in each direction and best of the three values was considered as final reading for analysis. The examiner was required to comment on quality of movement (pain & end-feel) and direction of restriction (if present), immediately after the test. Interpretation of the test results were based upon the range of motion, pain provocation and resistance to movement during the test.

Statistical Analysis: Software Graph Pad In Stat 3.1 was used for analysis of the data. Microsoft word and Excel were used to generate graphs, tables etc. Results on

continuous measurements are presented on Mean \pm SD and results on categorical measurements are presented in Number (%). Comparison between mean values of cranio-cervical angles of Class I and Class II skeletal malocclusion was done using Student's t-test. Comparison between mean values of ranges obtained in Flexion rotation test ranges of Class I and Class II skeletal malocclusion subjects was also done using Student's t-test. Correlation between cranio-cervical angles and flexion rotation test ranges (Right and Left separately) were analysed using Pearson's correlation coefficient.



Fig 2: Measurement of Upper cervical range of motion with flexion rotation test using CROM

RESULTS

The mean age of the participants included in the study in the Class I group was 39.53 ± 14.24 years and in the Class II group was 41.10 ± 11.02 years.

The mean of the cranio-cervical angle in Class I was found to be $103 \pm 1.73^\circ$ and in the Class II group it was found to be $94.36 \pm 4.08^\circ$. 64% of Class II participants had abnormal posterior inferior angle in cranio cervical posture as assessed with the lateral cephalometric tracing.

Table 1: Cranio-cervical angles in Class I and Class II skeletal malocclusion

Malocclusion	Class I	Class II
Cranio-cervical Angle	103 ± 1.73	94.36 ± 4.08
Angle affected in (% of subjects)	0%	64%
Unpaired t-test	$t = 6.948, < 0.0001$	

The difference between mean values of CCA of Class I and Class II was found to be highly statistically significant.

Flexion rotation test ranges were found to be affected in 64% of Class II subjects (either on one or both the sides).

Only 15% of Class I study subjects had affected FRT ranges

Table 2: Flexion rotation test ranges in Class I and Class II skeletal malocclusion

Malocclusion		Right Side		Left Side	
		Class I	Class II	Class II	Class I
Flexion -Rotation Test	Mean Value±SD	44.07±2.78	39.66±2.08	43.76±2.24	39.81±2.33
	Ranges affected in (% of subjects)	15%	63%	7%	64%
	Unpaired t-test	t= 4.731, p= 0.0001		t=4.201,p=0.004	

The difference between mean values of ranges obtained in FRT on both right and left sides of Class I and Class II subjects was found to be highly statistically significant. A positive correlation was found between CCA and FRT of Class II subjects.

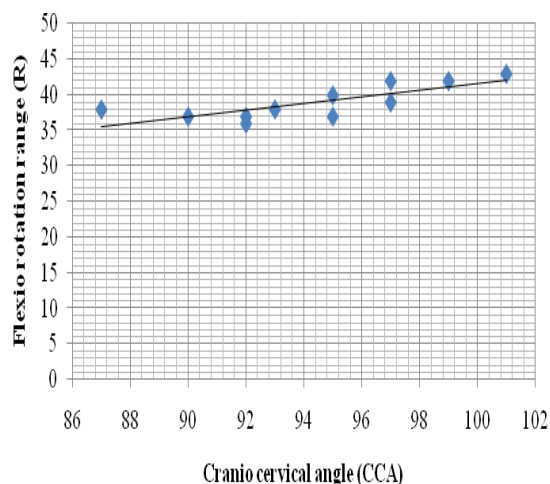


Fig 3: Correlation between CCA and FRT on right side in Class II subjects

Positive correlation was found between CCA and FRT ranges on right ($r = 0.78, p = 0.0043$) as well as on left side ($r = 0.69, p = 0.0180$)

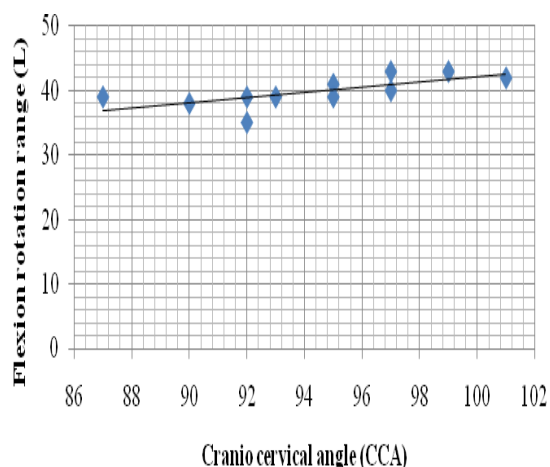


Fig 4: Correlation between CCA and FRT on left side in Class II subjects

DISCUSSION

This study aimed at comparing the cranio-cervical posture and its effect on upper cervical mobility in Class I & Class II skeletal malocclusion. In skeletal malocclusion, there is mal-alignment of the upper and lower jaw which extrapolates into malalignment of the teeth. As per the Classification given by Edward H Angle, in Class II malocclusion, there is anteriorization/protraction of the maxilla whereas in Class I malocclusion there is concomitant protraction of both the jaws. Jaws form important component of the skull, which is connected with rest of the spine through cervical vertebrae. First and second cervical vertebrae (atlas and axis respectively) are different from others with respect to their functions and anatomy. About 60% of the entire cervical spine axial rotation occurs in this region, and about 40% occurs from lower cervical spine. [7] Earlier changes in cervical range of motion and muscle endurance could be interpreted as a risk factor for the development of neck discomfort. [8]

In the present study cranio-cervical posture was assessed on the patient's lateral cephalogram, as it is found to be one of the most accurate methods of evaluating cranio-cervical posture. [9] The craniocervical angle is formed by the McGregor plane and the odontoid plane. This angle is used to assess the antero-posterior position of the cranium in relation to the cervical spine. In present study, the average cranio-cervical angle on the lateral cephalogram were recorded to be $103^\circ \pm 4.08^\circ$ for Class I and $94^\circ \pm 1.73^\circ$ for skeletal Class II malocclusions. The comparisons of mean cranio-cervical angle of Class I and Class II groups were seen to be highly statistically significant (p value < 0.0001). According to various researchers,

normal cranio-cervical angle is estimated to be $101^{\circ}\pm 5^{\circ}$.^[10,11] A value of $94^{\circ}\pm 1.73^{\circ}$ suggests upper cervical extension or forward chin posture in skeletal Class II group. 64% of the Class II subjects exhibited reduction of posterior inferior angle, with a minimum value reaching 87° . These changes in the cranio cervical angles are a common findings in the Class II malocclusion.^[4] Bjork and Marcotte demonstrated extended head position in individuals with Class II malocclusions.^[12,13] A study by D'Attilio and Sergio Caputi et al., also documented increased head extension in Class II compared to Class I malocclusion. Explanation for these findings could be traced back to the evidence suggesting presence of low dorsal height of atlas in subjects with skeletal Class II malocclusion.^[14] Correlation between morphological deviations of the atlas vertebra and craniofacial morphology could be found in the early embryogenesis. The notochord determines the development of both body of the atlas vertebra and the basilar part of the occipital bone which is the posterior part of the cranial base angle.^[15] As the jaws are attached to the cranial base; the cranial base could be the developing link between the atlas & jaws. Presence of low atlas arch in Class II group, leads to cervical extension posture. Studies prove a strong positive correlation between head posture and the vertical height of dorsal arch of atlas, meaning lesser the height of the posterior arch of the atlas more is the head extension.^[16] Secondly, it has been noted that the subjects with a low dorsal arch had a relatively elevated and thus altered suprahyoid muscular activity which would permanently affect the position of the mandible.^[14]

In order to check the effect of changed cranio-cervical posture on the mobility of the same, Flexion Rotation Test (FRT) was performed as it is one of the most valid methods for measurement of upper cervical mobility.^[17] Mean values of the FRT ranges on the right and left side were found to be $39^{\circ}\pm 2.4^{\circ}$ and $39.81^{\circ}\pm 2.35^{\circ}$

respectively for skeletal Class II subjects. Hiroshi Takasaki and Toby Hall et al, have postulated that the normal values of FRT fall within the range of $44^{\circ}\pm 4^{\circ}$.^[17] According to this 64% of our Class II subjects had limitations in FRT ranges, on one side or both the sides. A positive correlation between the cranio-cervical angle & FRT range of motion in right ($r=0.78$) and left ($r=0.69$) side was found in Class II participants. This relationship could be explained with certain biomechanical alteration resulting from sustained faulty postures. Biomechanically axial rotation and lateral flexion are not considered as physiological movements of atlanto-occipital joint. Muscles cannot produce these movements in isolation. As performed in FRT, these movements can be produced by moving the head into these directions passively while keeping the atlas fixed. Rotation requires forward translation of one condyle and backward translation of the other. Translation is possible only if the condyles of the occiput rise up the respective walls of the atlantal sockets. For axial rotation of head, condyles of the occiput must separate from the atlas. This separation is normally resisted by tension in the capsules of the atlanto-occipital joints.^[7] Postural analysis of our Class II subjects demonstrated anteriorization of occiput on atlas (forward chin). Even minor alignment faults in posture limit motion and leads to tightness of soft tissues and muscles. Consequent tightness in the posterior part of the atlanto-occipital joint capsule could be a limiting factor for the FRT range of motions in this study. Secondly, in faulty postures the muscles that are in shortened position are thought to be overactive and those in elongated positions to be weaker. Present study indicated presence of anteriorization of head (poking chin posture) in skeletal Class II malocclusion. Stretching & weakness of semispinalis cervicis and overaction & shortening of semispinalis capitis is well documented in poking chin posture.^[18] This could be a limiting factor for upper cervical flexion, leading to

restriction of range of motions during FRT, as its first step is complete cervical flexion.

In our study all the participants with Class 2 malocclusion who had abnormal FRT ranges, reported the presence of pain in the neck. This pain can be attributed to the faulty posture. [19] Anatomically, there is no disc present between occiput & atlas and atlas & axis. The stability to these structures is only provided by their ligaments and facet joints which are also rich in nociceptors and sensory afferent supply. Capsular ligament tension is increased during abnormal postures and excessive tension on the capsular ligaments can cause upper cervical instability and related neck pain. [20] Detailed assessment of the pain was beyond the scope of this study.

CONCLUSION

Evaluation of cranio-cervical angle suggests presence of upper cervical extension or forward chin posture in skeletal Class II subjects. Ranges recorded during the FRT were significantly reduced in people with skeletal Class II malocclusion as compared to skeletal Class I, on one side or both the sides. A strong positive correlation was found between CCA and upper cervical range of motion (FRT).

Limitations:

This study being conducted on a limited time frame could include less number of samples which according to the authors is a limitation of the study.

ACKNOWLEDGEMENTS

The authors would like to thank Dr. Unnati Pandit, Professor and Director, School of Physiotherapy, D Y Patil University, Nerul and Dr. A. Kumarswamy, Head of research, Y.M.T Dental College and Hospital, Dr. Sharad Kokate, Dean, YMT Dental College and Hospital and Dr. Meghna Vandekar, Head of the department, Department of Orthodontics and Dentofacial Orthopaedics, Y.M.T Dental College and Hospital, Kharghar for their unwavering support towards this study.

REFERENCES

1. Deda MR, Mello-Filho FV, Xavier SP, Trawitzki LV. Head posture in the presence of class II and class III dentofacial deformities. *Revista CEFAC*. 2012 Apr;14(2):274-80.
2. Swartz EE, Floyd RT, Cendoma M. Cervical spine functional anatomy and the biomechanics of injury due to compressive loading. *Journal of athletic training*. 2005 Jul 1;40(3):155.
3. Michelotti A, Buonocore G, Manzo P, Pellegrino G, Farella M. Dental occlusion and posture: an overview. *Progress in orthodontics*. 2011 May 31;12(1):53-8.
4. García N, Sanhueza A, Cantín M, Fuentes R. Evaluation of cervical posture of adolescent subjects in skeletal class I, II, and III. *Int. j. morphol*. 2012 Jun 1;30(2):405-10.
5. Arntsen T, Sonnesen L. Cervical vertebral column morphology related to craniofacial morphology and head posture in preorthodontic children with Class II malocclusion and horizontal maxillary overjet. *American Journal of Orthodontics and Dentofacial Orthopedics*. 2011 Jul 31;140(1):e1-7.
6. Kee IK, Byun JS, Jung JK, Choi JK. The presence of altered craniocervical posture and mobility in smartphone-addicted teenagers with temporomandibular disorders. *Journal of physical therapy science*. 2016;28(2):339-46.
7. Bogduk N, Mercer S. Biomechanics of the cervical spine. I: Normal kinematics. *Clinical biomechanics*. 2000 Nov 30;15(9):633-48.
8. Szeto GP, Straker LM, O'Sullivan PB. A comparison of symptomatic and asymptomatic office workers performing monotonous keyboard work-2: neck and shoulder kinematics. *Manual Therapy*. 2005 Nov 30;10(4): 281-91.
9. Weber P, Corrêa EC, Milanesi JM, Soares JC, Trevisan ME. Craniocervical posture: cephalometric and biophotogrammetric analysis. *Brazilian Journal of Oral Sciences*. 2012 Sep; 11(3):416-21.
10. Armijo-Olivo S, Jara X, Castillo N, Alfonso L, Schilling A, Valenzuela E,

- Frugone R, Magee D. A comparison of the head and cervical posture between the self-balanced position and the Frankfurt method. *Journal of oral rehabilitation*. 2006 Mar 1;33(3):194-201.
11. Matheus RA, Ramos-Perez FM, Menezes AV, Ambrosano GM, Haiter-Neto F, Bóscolo FN, Almeida SM. The relationship between temporomandibular dysfunction and head and cervical posture. *Journal of Applied Oral Science*. 2009 Jun;17(3):204-8.
 12. Bjork A. Some biological aspects of prognathism and occlusion of the teeth. *The Angle orthodontist*. 1951 Jan;21(1):3-27.
 13. Marcotte MR. Head posture and dentofacial proportions. *The Angle orthodontist*. 1981 Jul;51(3):208-13.
 14. Watanabe M, Yamaguchi T, Maki K. Cervical vertebra morphology in different skeletal classes: a three-dimensional computed tomography evaluation. *The Angle Orthodontist*. 2010 Jul;80(4):719-24.
 15. Kale P, Shrivastav S, Kamble RH, Sharma N. Variation in the morphology of atlas vertebrae in different skeletal patterns: a three-dimensional computed tomography evaluation. *Journal of evolution of medical and dental sciences*. 2015 Feb 26;4(17):2948-55.
 16. Kylämarkula S, Huggare J. Head posture and the morphology of the first cervical vertebra. *The European Journal of Orthodontics*. 1985 Aug 1;7(3):151-6.
 17. Takasaki H, Hall T, Oshiro S, Kaneko S, Ikemoto Y, Jull G. Normal kinematics of the upper cervical spine during the flexion-rotation test-In vivo measurements using magnetic resonance imaging. *Manual therapy*. 2011 Apr 30;16(2):167-71.
 18. Burt HA. Effects of Faulty Posture: President's Address.1950: XLIII: 187-194
 19. Yip CH, Chiu TT, Poon AT. The relationship between head posture and severity and disability of patients with neck pain. *Manual therapy*. 2008 Apr 30;13(2):148-54.
 20. Steilen D, Hauser R, Woldin B, Sawyer S. Chronic neck pain: making the connection between capsular ligament laxity and cervical instability. *The open orthopaedics journal*. 2014;8:326.

How to cite this article: Sonawane B, Karthik S, Balasubramanian K et al. Comparison of cranio-cervical posture and upper cervical range of motion in Class I and Class II skeletal malocclusion. *Int J Health Sci Res*. 2017; 7(7):110-116.
