

Case Report

Adenomatoid Odontogenic Tumor in Mandible: An Anatomic Variation-A Case Report

Dr. Sunita Kulkarni¹, Dr. Usha Rathod², Dr. Ashish Lanjekar³

¹Professor and HOD OMDR, ²Post Graduate Student OMDR, ³Reader OMDR
Dept of Oral Medicine and Radiology, Swargiya Dadasaheb Kalmegh Smruti Dental College & Hospital,
Nagpur, Maharashtra.

Corresponding Author: Dr. Usha Rathod

ABSTRACT

Adenomatoid odontogenic tumor (AOT) is a hamartomatous, benign, uncommon epithelial odontogenic tumor. It is also called as ameloblastic adenomatoid tumor, adamantinoma, epithelioma adamantinum or teratomatous odontoma. The WHO has defined AOT as a tumor of odontogenic epithelium with duct-like structures and with varying degree of inductive changes in the connective tissue. It commonly occurs in maxilla with impacted canine as a painless swelling. Conservative surgical enucleation is the treatment of choice. Here we present a case of a 29 years old male patient reported with chief complaint of swelling in the lower right anterior teeth region since 1 month to the department of oral medicine and radiology.

Keywords: Adenomatoid odontogenic tumor, pseudo-adenameloblastoma, anatomical variation.

INTRODUCTION

As documented in literature by Steensland, Adenomatoid odontogenic tumor (AOT) is called the master of disguise as epitheliomaadamantinum.^[1] It is a benign neoplasm. It is a relatively uncommon distinct odontogenic neoplasm. The WHO histological typing of odontogenic tumors, jaw cyst and allied lesions (2005) has defined AOT as a tumor of odontogenic epithelium with duct-like structures and with varying degree of inductive changes in the connective tissue.^[2] It is a slow growing lesion, commonly occurs in maxilla. It constitutes about 3% of all odontogenic tumors followed by odontoma, periapical cemental dysplasia (Cementoma), myxoma, and ameloblastoma.^[2,7] AOT may expand the cortical plates at an early stage, in which the cancellous bone spread linearly and then later by expansion may affect the cortical

plates. Recurrence rate is low and can be treated with enucleation and simple curettage.^[2]

CASE REPORT

CLINICAL EXAMINATION:

A 29 years old male patient reported with chief complaint of swelling in the lower right anterior teeth region since 1 month to the department of oral medicine and radiology. He was apparently alright 1 month back, then he noticed swelling in mandibular anterior teeth region. The swelling was initially small in size and progressively increased to present size with no history of pain, bleeding, pus discharge and paresthesia.

Extraoral examination revealed a single diffused swelling on lower right side of the face extending from midline of face to right corner of mouth antero-posteriorly and from lower border of lower lip to 1 cm

above the lower border of mandible supero-inferiorly (FIG-1).

Colour same as that of adjacent skin, size approximately 3 X 4 cm, shape roughly oval with ill-defined margins.

Intra oral clinical examination revealed a single, well defined, round swelling in 43 44 region. It was extending anterioposteriorly from distal of 43 to mesial of 44 and superioinferiorly from marginal gingiva to deep in labial vestibule (FIG-2). Size was approximately 1.5 X 1.5 cm, colour was same with adjacent mucosa with well defined borders and smooth surface. On the basis of history, clinical presentation a provisional diagnosis of periapical cyst was given.

INVESTIGATIONS:

Orthopantomograph was obtained. The radiographic examination shows the solitary well defined radiolucency in periradicular area of 43 44 extending anterioposteriorly from mesial root surface of 43 to distal root surface of 44 and superioinferiorly from alveolar crest to periapical area of 43 44. Tooth displacement seen with 43 44. No root resorption seen. Size is approximately 3x 2 cm (FIG.3)

Routine hematological examinations including hemogram, blood sugar level, screening tests were found to be within normal physiological limits. The histopathological report of fine needle aspiration (FIG- 4) shows odontogenic epithelial cells arranged in whorls, duct of various size, strands and small island. Areas of eosinophilic coagulum are seen intercellularly. Few convulated duct and rosettes are seen. {FIG-5 HD, FIG 6 LD}

DIAGNOSIS:

The differential diagnosis is consisted Ameloblastoma Follicular cyst, CEOT Calcifying odontogenic cyst, Ameloblastic fibro-odontoma, Dentigerous cyst. Thus a final diagnosis was considered as Adenomatoid Odontogenic Tumor.

TREATMENT:

Total surgical excision of the lesion under local anesthesia and aseptic conditions was done. (FIG-7,8)

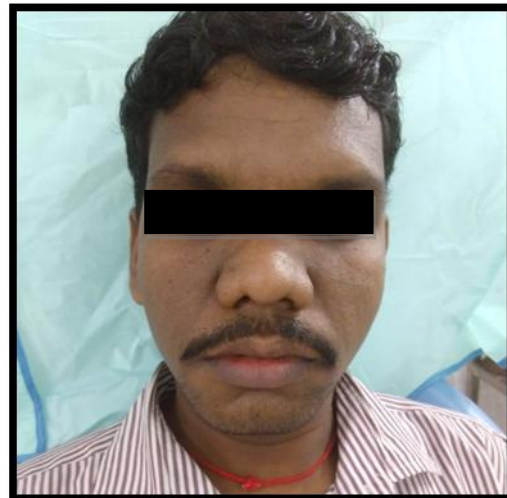

FIG-1 Extra-Oral showing swelling on right side of face

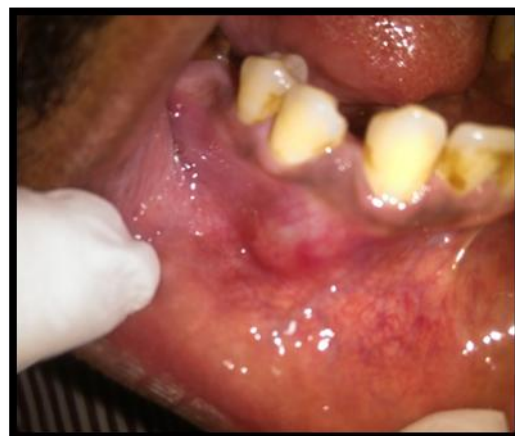

FIG-2 Intraoral showing lesion

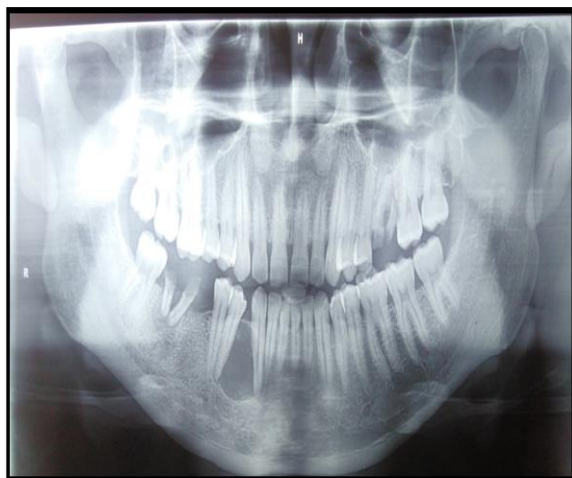


FIG-3 OPG showing lesion in right mandibular premolar region.




FIG-4 FNAC showing blood

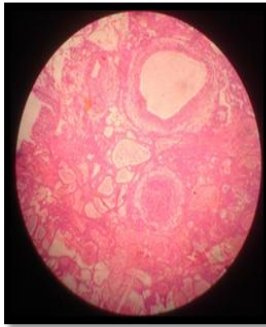


FIG-5 High Definition

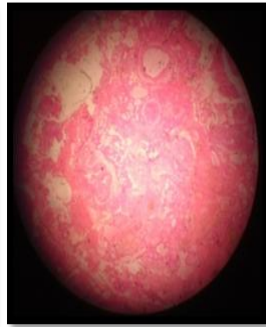


FIG-6 Low Definition

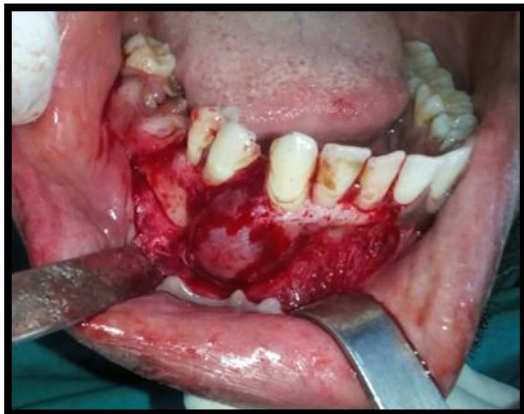

FIG-7 Surgically Raised Flap

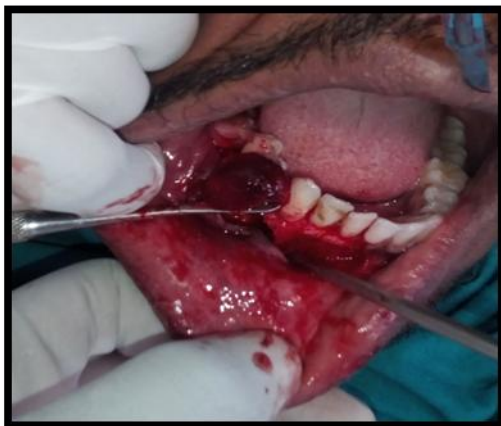

FIG-8 Removal Of Lesion

The clinical and radiographic features often shows similarity with other odontogenic cyst. [2] The clinical presentation is asymptomatic swelling which is slowly growing and often associated with an unerupted tooth. Displacement of neighbouring teeth is more common than root resorptions. The tumor may be partly cystic, and in some cases the solid lesion may be present only as masses in the wall of a large cyst. [1] An amorphous material called "tumor droplets" which is an eosinophilic uncalcified can be found. Some tumor droplets show a homogenous matrix whereas most tumor droplets reveal electron-dense plaques. [3,4] The radiographic findings of AOT frequently resemble other odontogenic lesions such as dentigerous cysts, globule-maxillary cysts, ameloblastomas, calcifying odontogenic tumors odontogenic keratocysts calcifying odontogenic cysts and periapical disease. [2,7]

The peripheral lesions may show some erosions of the adjacent cortical bone AOT can occur both intraosseously and extraosseously Intraosseous AOTs are characterised by a well-defined unilocular radiolucency surrounding the crown, Intraosseous type accounts for about 73% of all AOTs. The extrafollicular type occurs 24% of all AOTs and presents as a unilocular radiolucency found between, above, or superimposed on the roots of erupted teeth². Based on positive staining with CK5, CK17 and CK19, AOT phenotype is characterized by a cytokeratin (CK) profile similar to follicular cyst and/or oral or gingival epithelium. [3,5]

DISCUSSION

AOT has unique clinical, radiographic, and histopathological features.

AOT involves both the bone and soft tissue in anatomic configuration. It has a decisive sex predilection for females, but in our case it is present in male. [6] The relatively small size of the tumor and lack of recurrences in most cases goes in favour of hamartoma but the question is still unanswered whether it is hamartoma or tumor. Aggressive features in few of the reported cases and an increased variation as compared to odontogenic apparatus suggest that it has neoplastic origin. Calcifications exhibited in the form of leisegang rings, spheroidal masses, and globular forms. [1,8]

Conservative surgical enucleation is the treatment modality of choice. Guided tissue regeneration with membrane technique is suggested after complete removal of the tumor if periodontal intrabony defects caused by AOT are present. Recurrence rate of AOT is rare. [3,9]

REFERENCES

1. Mutalik VS, Shreshtha A, Mutalik SS, Radhakrishnan R. Adenomatoid odontogenic tumor: A unique report with histological diversity. *Journal of Oral and Maxillofacial Pathology*. 2012 Jan 1;16(1):118.
2. Baskaran P, Misra S, Kumar MS, Mithra R. Adenomatoid Odontogenic Tumor– A Report of Two Cases with Histopathology Correlation. *Journal of clinical imaging science*. 2011 Jan 1;1(1):64.
3. Handschel JG, Depprich RA, Zimmermann AC, Braunstein S, Kübler NR. Adenomatoid odontogenic tumor of the mandible: review of the literature and report of a rare case. *Head & Face Medicine*. 2005 Aug 24;1(1):3.
4. Philipsen HP, Reichart PA. The adenomatoid odontogenic tumour: ultrastructure of tumour cells and non-calcified amorphous masses. *Journal of oral pathology & medicine*. 1996 Oct 1;25(9):491-6.
5. Larsson Å, Swartz K, Heikinheimo K. A case of multiple AOT-like jawbone lesions in a young patient—a new odontogenic entity?. *Journal of oral pathology & medicine*. 2003 Jan 1;32(1):55-62.
6. Kumar CA, Reddy J, Gupta S, Raghav N. An Unusual Site of Adenomatoid Odontogenic Tumor Presenting as Periapical (Radicular) Cyst: A Rare Case Report. *Journal of Indian Academy of Oral Medicine and Radiology*. 2010 Jan 1;22(1):39.
7. Friedrich RE, Scheuer HA, Zustin J. Adenomatoid odontogenic tumor (AOT) of maxillary sinus: Case report with respect to immunohistochemical findings. *In vivo*. 2009 Jan 1;23(1):111-6.
8. Garg D, Palaskar S, Shetty VP, Bhushan A. Adenomatoid odontogenic tumor—hamartoma or true neoplasm: a case report. *Journal of oral science*. 2009;51(1):155-9.
9. Blumenthal NM, Mostofi R. Repair of an intrabony defect from an adenomatoid odontogenic tumor. *Journal of periodontology*. 2000 Oct 1;71(10):1637-40.

How to cite this article: Kulkarni S, Rathod U, Lanjekar A. Adenomatoid odontogenic tumor in mandible: an anatomic variation- a case report. *Int J Health Sci Res*. 2017; 7(6):331-334.
