

Case Report

Post Hypoxic Sequelae Following Organophosphorus Poisoning -A Case Report

Dr. Nikhil. G. Panpalia¹, Dr. Prerana. N. Chandak², Dr. Samrat. S. Madnaik³

¹Resident of Neurology, Jawaharlal Nehru Medical College, Belagavi, Karantaka

²Obstretician and Gynaecologist Working at Devki Nursing Home, Akola, Maharashtra

³Resident Cardiac Anesthesia, Jawaharlal Nehru Medical College, Belagavi, Karantaka

Corresponding Author: Dr. Nikhil. G. Panpalia

ABSTRACT

A 19 year young male who consumed organophosphorus compound and required assisted mechanical ventilation. He developed features of anoxic encephalopathy with diminished vision and weakness. There was good recovery on treatment with later patient developing features of Extrapyramidal features secondary to post hypoxic sequelae.

Keywords: Organophosphorus poisoning, Extrapyramidal syndrome, Hypoxic encephalopathy.

INTRODUCTION

Organophosphate (OP) is the general term for esters of phosphoric acid. [1,2] In 1932, German chemist Willy Lange and his graduate student, Gerde von Krueger, first described the cholinergic nervous system effects of organophosphates, noting a choking sensation and a diminution of vision after exposure. [3] This discovery later inspired the German chemist Gerhard Schrader in 1930s to experiment with these compounds as insecticides. [4]

The American Association of Poison Control Centre reported 102,705 cases of the incidence of organophosphate annually; [6] the highest incidence is seen in India. [5,6] The incidence in Sri Lanka is 10,000 – 20,000 hospital admissions annually. [7] According to WHO estimation around 10,000 hospital deaths annually occur from OP poisoning world-wide. [8] Signs and symptoms are divided into muscarinic effects, nicotinic effects and central nervous system effects. [9] Morbidity and mortality are due to insufficient respiratory management, delayed intubation, cardiac

complications, aspiration pneumonia, weakness and neuropathy. [10] Despite its common occurrence, there is not much awareness.

In this case we report an uncommon occurrence of hypoxic injury to the brain in a patient who initially had presented with respiratory distress following exposure to OP poisoning. He had axial and appendicular weakness with diminished vision and on follow up there was involuntary choreiform movement of both upper limbs with generalized rigidity.

CASE REPORT

In this report we are presenting a case of 22 year old patient who was found unconscious in the field. Compound bottle was lying next to him which was presented by the relatives to the doctor at the local hospital. It was confirmed as OP chemical after which was given gastric lavage and started on atropine with pralidoxime. There was precipitous deterioration of general condition with patient developing respiratory distress after which he was

shifted to our hospital for further management.

On admission to our hospital he was stuporose, opening eyes and moving all four limbs to deep painful stimuli. There was characteristic smell of compound from his clothes and breath. GCS was 8/15 (E2 V2 M4). There was presence of bronchorrhea with bilateral conducted sounds, generalized fasciculations and increased sweating. Neck holding was weak. In view of aspiration pneumonitis with poor chest expansion and low GCS he was intubated and kept on mechanical ventilation (volume support).

He was given atropine 1 mg every 10 minutes till his oral secretions and chest conducted sounds cleared. After this he was continued on atropine infusion 4mg/hour and infusion was adjusted accordingly. Pralidoxime was given at 2gm/kg in divided doses over 2 days. IV fluids and supportive care was given to the patient. Routine lab parameters including hemogram, electrolytes and renal parameters were normal and they were monitored serially. Serum cholinesterase levels; were 889.8 U/L.

After 2 days his general condition improved. Chest expansion had improved to >2 cm with reduced conducted sounds. There was no drug or infection induced fever. Subsequently on third day he was extubated and kept on Mask (Bipap) ventilation. He tolerated the extubation well with no further respiratory distress. Atropine infusion was stopped on third day and it was given every 4th hourly intravenously. Subsequently it was tapered and stopped on fifth day of admission.

On 6th day he was finally fully oriented with GCS 15. He had persistent neck holding weakness with Aymmetric flaccid Quadripareis (Left>Right) with preserved reflexes. He also had diminished vision in both eyes with only perception of light present. Pupils were normally reacting. Fundus examination was done which showed no papilloedema with preserved disc and vessels. Considering the above scenario possibility of OP neuropathy which

is commonly associated with this syndrome were considered. He was treated supportively with showing no improvement in neurological condition of patient. Finally in view of non resolving visual loss it was decided to obtain cranial imaging of brain.

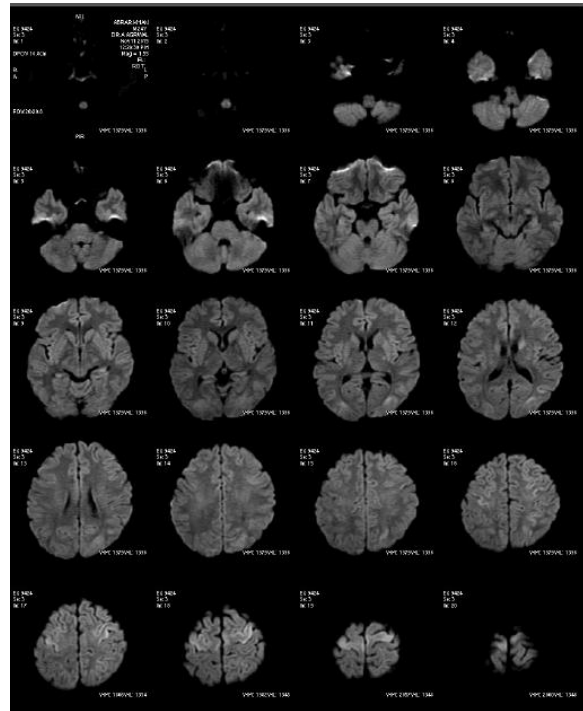


Figure1: Diffusion weighted hyperintensities in bilateral frontal, inferior parietal and occipital region. These changes were characteristic of hypoxic brain insult.

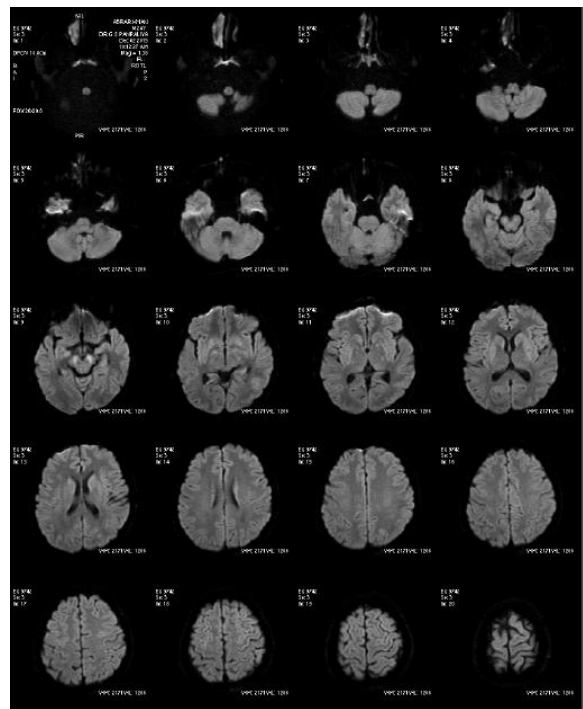


Figure2: . Repeat diffusion weighted images showed resolution of lesions

There was diffusion restricted, T2 and FLAIR hyperintensities in bilateral frontal, inferior parietal and occipital region. (Figure 1) These changes were characteristic of hypoxic brain insult. Subsequently he was started on Piranulin with Dexamethasone 8 mg stat and 4 mg every sixth hourly. Patient was monitored serially. On 8th day he had improvement in vision with patient being able to count fingers from both eyes at distance of one foot. He was also able to hold his neck and there marked improvement in limb power to 4/5. He was continued on steroids and it was decided to repeat Brain imaging after 3 days i.e day 11. Repeat brain imaging showed resolution of lesions. (Figure 2)

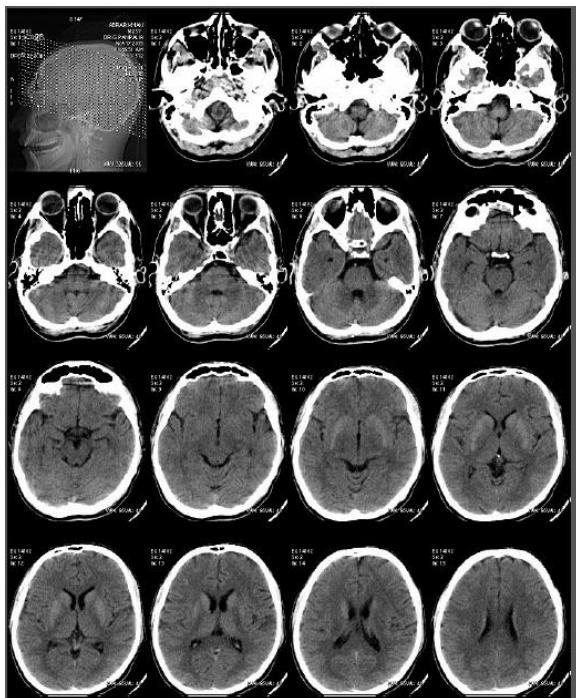


Figure 3: CT brain shows involvement of bilateral basal ganglia hyperintensities suggestive of hypoxic insult.

On day 12th his vision improved markedly with able to perceive things at 5 feet. Limb power was 4/5 with patient being able to walk with support. He was discharged subsequently and it was planned to repeat Brain imaging on follow up. There was presence of involuntary choreiform movement of both upper limbs on follow up. Repeat imaging showed resolution of edema from parietal, occipital and frontal region but there was involvement of

bilateral basal ganglia suggestive of hypoxic insult. (Figure 3) He was started on anticholinergics and dopamine blocking agents. At present on subsequent follow up there was subsequent reduction of involuntary movements with patient being able to carry out activities of daily living independently.

DISCUSSION

Organophosphate (OP) compounds are widely used as pesticides in agricultural parts of the world. Insufficient control on the importation, production, storage and unsafe use of OP pesticides are the common reasons of poisoning. [11]

Suicidal and non-suicidal organophosphate poisoning is a major problem in rural areas of India and the incidence are increasing rapidly due to increasing sentimental situations. [5] Hypoxic encephalopathy is a rare in Organophosphorus poisoning that presents after apparent recovery from acute cerebral anoxia. [12,13] It appears within one to three weeks after anoxia and has an insidious onset characterized by cognitive, neuropsychiatric, motor and extrapyramidal abnormalities. [12,13] At onset, the patient shows apathy, confusion, attentional and memory deficits, irritability, and aggressiveness, followed by altered gait, spasticity, and extrapyramidal manifestations, which, in some cases, eventually lead to coma or death. [13] Some patients stabilize and are left with mild or moderate sequelae, whereas others recover completely. [12] This is similar to our case who initially had features of cerebral anoxia noted as weakness with impaired vision and altered behavior with later showing features of extrapyramidal involvement noted as rigidity and involuntary movement.

The main histopathological patterns seen in this syndrome are demyelination in the centrum semiovale and necrosis of the cortical laminae and basal ganglia, which correlate with cranial MRI features. [12] On neuroimaging, hypoxic injury is noted as signal intensity on T2-weighted and FLAIR

sequences, repercussions in diffusion-weighted images and ADC mapping of the centrum semiovale and periventricular white matter, and bilateral signal abnormalities in the globi pallidi, with low signal intensity on T1-weighted and high signal intensity on T2-weighted and FLAIR images. [13] It is reasonable to assume that the abnormal features in the pallidal nuclei are secondary to acute damage after anoxic injury, whereas the white matter findings correspond to delayed damage.

Outcome in hypoxic injury ranges from complete recovery to death, and seems not to be related to the medication administered. [12] Severity and persistence of DPE sequelae have been correlated to the presence and persistence of low signal intensity in the ADC map on cranial MRI. [13] The outcome in our patient was favorable and coincided with an improvement in the white matter lesions on diffusion imaging though the extrapyramidal features which occurred later in this case could be explained by the persistence of lesion in bilateral basal ganglia.

CONCLUSION

This is rare case report of a patient who presented with OP poisoning, later on developing hypoxic insult with post hypoxic sequelae in the form of rigidity and involuntary movements which responded to symptomatic treatment. Hence we suggest rapid diagnosis and treatment for good clinical recovery for such patients.

REFERENCES

1. Davies R, Ghose A. Chronic exposure to organophosphates: background and clinical picture. *Adv Psychiatr Treatment* 2000; 6:187-92.

2. Kasper DL, Braunwald E, Hauser S, Longo D, Jameson JL, Fauci AS, editors. *Harrison's principles of internal medicine*. 16th ed. New York: *McGraw Hill*; 2005.
3. Reddy KS. *The essentials of forensic medicine and toxicology*. 25th ed. India: *Medical Book Co.*; 2006.
4. Taylor P. Anticholinesterase agents. In: Goodman LS, Gilman A, editors. *The pharmacological basis of therapeutics*. 6th ed. New York: *MacMillan Publishing Co*; 1980. p. 428.
5. Rodgers ML. OP poisoning. *Am J Emerg Med* 2006; 22:335-44.
6. Singh G, Khurana D. Neurology of acute organophosphate poisoning. *Neurol India* 2009; 57:119-25.
7. Khurana D, Prabhakar S. Organophosphorus intoxication. *Arch Neurol* 2000; 57:600-2.
8. Ghosh PG, Sawant NA, Patil SN, Aglav BA. Microbial biodegradation of organophosphate pesticides. *Int J Biotechnol Biochem* 2010; 6:871-6.
9. Karczmar AG. Story of muscarinic receptors, alkaloids with muscarinic significance and of muscarinic functions and behaviors. *Annual Rev Biomed Sci* 2009; 11:T1-50.
10. Tall A, Ly AB, Nabeth P, Sall AA, Sarr FD, Faye J, et al. Epidemiological investigation of death cases by pesticide poisoning. *J Agric Biotechnol Sustainable Develop* 2010; 2:51-5.
11. Malik GM, Mubarik M, Romshoo GJ. Organophosphorus poisoning in the Kashmir Valley, 1994-1997. *N Engl J Med* 1998; 338:1078-9
12. Custodio CM, Basford JR. Delayed postanoxic encephalopathy: a case report and literature review. *Arch Phys Med Rehabil* 2004; 5:502-505.
13. Plum F, Posner JB, Hain RF. Delayed neurological deterioration after anoxia. *Arch Inter Med* 1962; 110:18-25.

How to cite this article: Panpalia NG, Chandak PN, Madnaik SS. Post hypoxic sequelae following organophosphorus poisoning - a case report. *Int J Health Sci Res*. 2017; 7(4):480-483.
