

# Efficacy Laser Dermabrasion Followed by Topical 5-Fluorouracil in the Treatment of Stable Vitiligo

Dr. Mariam George<sup>1</sup>, Dr. Mallikarjun M<sup>2</sup>, Dr. Manjunath. P<sup>3</sup>, Dr. Bugude Gangadhar<sup>3</sup>

<sup>1</sup>Post graduate, <sup>2</sup>Professor, <sup>3</sup>Assistant Professor,  
K.V.G Medical College, Sullia

Corresponding Author: Dr. Mariam George

## ABSTRACT

**Background:** Vitiligo is one among the various dermatological conditions where medical treatment can offer only partial success. A combined approach in the form of skin ablation and topical 5 fluorouracil has given good results.

**Aim:** In the present study, we are studying the effect of the use of laser skin ablation and application of 5 fluorouracil in treatment of patients with resistant vitiligo.

**Methods:** This study included 30 adult patients with resistant vitiligo lesions. The patients were treated with laser skin ablation, followed by 5 fluorouracil application for 15 days. The cosmetic outcome was then evaluated after maximum period of 3 months.

**Results:** Thirty patients were included (14 male and 16 females). Almost 40% of patients achieved excellent repigmentation (75-100%) after laser dermabrasion, followed by 5 fluorouracil application. Very good (50-75%) cosmetic results were achieved in 20% of patients, good improvement (25-50%) in 30% and poor improvement in (< 25%) only 10% of patients. Side-effects reported were transient hyperpigmentation in 3 (10%) patients; infection in 1(3.3%) patients, recurrence in 2(6.67%) patients while 24 (80%) patients did not report any untoward effects.

**Conclusion:** We conclude our study by stating that laser skin ablation, followed by 5- fluorouracil application is an ideal treatment option for resistant vitiligo.

**Key words:** vitiligo, 5-Fluorouracil, laser dermabrasion.

## INTRODUCTION

Vitiligo is an acquired multifactorial and polygenic dyschromia, presenting as multiple depigmented macules and patches.

[1] It affects 1- 3 % of world population. [2]

The ultimate aim of any treatment modality in vitiligo is to stimulate repigmentation of vitiligenous patch by stimulating the proliferation of active melanocytes around the hair follicles. It is one among the various dermatological conditions where medical treatment can offer only partial success. Medical management focuses upon a melanocyte reservoir and is preferred for expanding patches whereas for stable lesions, surgical modalities can be

considered. [3] Autologous suction blister grafting, split-thickness grafting, punch grafting, smash grafting, cultured epidermal suspensions and autologous melanocyte culture grafting are the currently practiced surgical methods for vitiligo. [4-8]

Combination of skin ablation and application 5 fluorouracil was previously used in the treatment of vitiligo with good results. In this study fractional carbon dioxide laser skin ablation was followed by topical 5-fluorouracil application. Topical 5-fluorouracil causes overstimulation of follicular melanocytes, which migrate to the epidermis during epithelialization. [9,10]

## METHODOLOGY

Study was done on 30 patients suffering from stable vitiligo resistant to medical modalities of treatment. Inclusion criteria included residual vitiligo after medical treatment which was stable for atleast one year. Patients who had keloidal tendency, mucosal vitiligo and patients with unrealistic expectations and those below 15 years of age were excluded from the study. Prilocaine cream under occlusion was applied to the vitiliginous area half an hour prior to the procedure. After half an hour area is cleaned with beta iodine and spirit. Fractional carbon dioxide was set at a Power of 25 J, Density of 0.3mm, Interval of 20msec, Duration of 0.3msec.

After laser application, area was wiped with saline soaked cotton gauze so that superficial epidermis is peeled off and minute bleeding points were made visible. (Fig. 2) Florida 5% cream (5 fluorouracil) was applied over the vitiliginous area under occlusion.

Patient was advised to clean the area and apply cream daily for a period of 15 days.

Patient was advised to stop application after 15 days. After that application of topical antibiotics was performed to avoid secondary bacterial infection until epithelization was completed.

Patient was evaluated every 15 days for a period of three months.

**Statistical analysis:** The results were analyzed using SPSS version 16 software. Results were expressed as simple percentage.  $P < 0.05$  was considered as statistically significant

## RESULTS

The study included 30 patients with stable vitiligo. 14(46.7%) male patients and 16 (53.3%) female patients.

22 (73.3%) cases of vitiligo vulgaris. 8 (26.7%) cases of focal vitiligo. None of the patients had family history of vitiligo. Cosmetic results assessed by physician is shown in (Table. 1)

Table. 1. Percentage of improvement of vitiligo after laser dermabrasion and topical 5 fluorouracil cream application

Improvement	Number of patients	Percentage
Poor (<25%)	3	10%
Minimal (25-50%)	9	30%
Good (50-75%)	6	20%
Excellent (>75%)	12	40%

Excellent cosmetic results were shown by 12 patients. Fig.4

Adverse effects included secondary bacterial infection and ulceration in 1 patient. Fig. 5

Transient hyperpigmentation in 3 patients and recurrence in 2 patients.

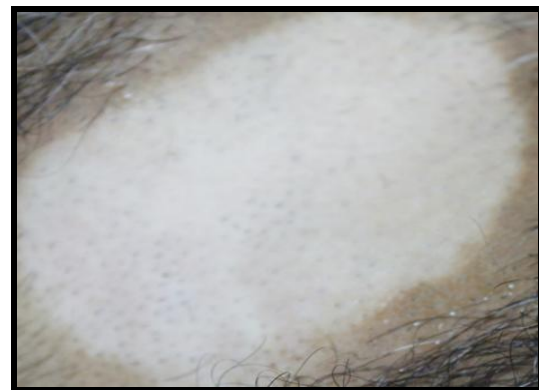

Fig. 1 vitiligo patch in chest

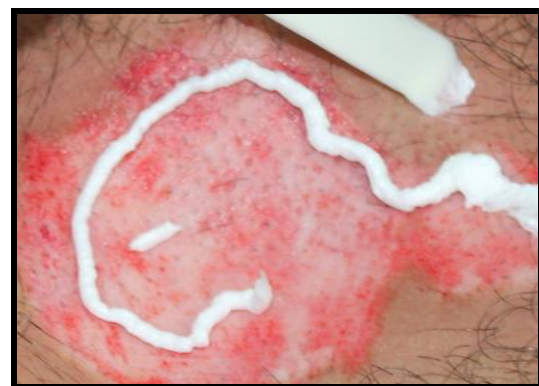

Fig. 2 Minute bleeding points after laser dermabrasion.

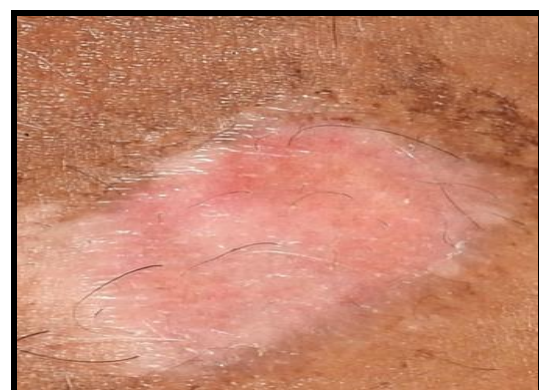

Fig. 3 Perifollicular erythema developing after two weeks of procedure.

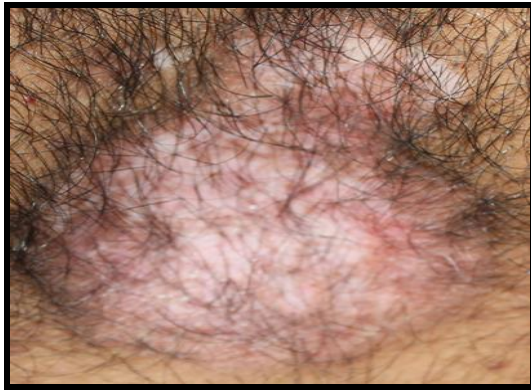

Fig. 4 Peripheral repigmentation after three months

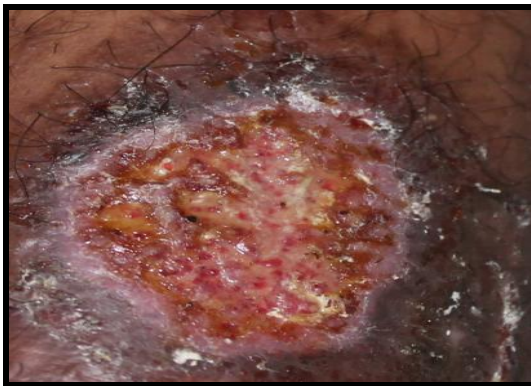


Fig. 5 Ulceration and secondary bacterial infection following prolonged application of 5 FU

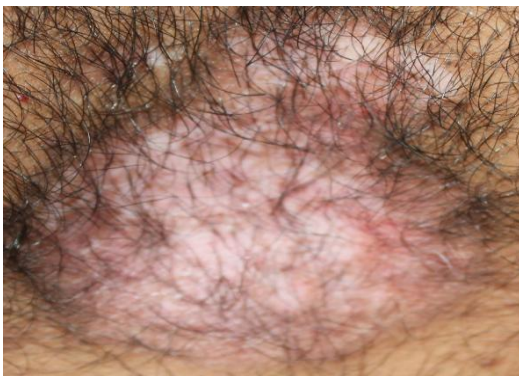

Fig. 6 Peripheral repigmentation after 3 months

## DISCUSSION

Laser skin ablation produces an array of microthermal zones (MTZs), creating small microscopic columns of thermal injury to skin and fractional resurfacing thermally ablates microscopic columns in regularly spaced arrays over a fraction of the skin surface.

This stimulates amelanotic (inactive) melanocytes present at the outer root sheath of the lower portion of the hair follicle. In our study the patients were subjected to laser skin ablation of the vitiliginous area followed by topical application of 5-

fluorouracil immediately after dermabrasion. 5 fluorouracil was continued daily for about 2 weeks until reepithelialization occurred. Patients were followed up every 2 weeks for about 3 months. After 2 weeks they were encouraged to expose themselves to the sun. This help in the migration and spreading of melanocytes. Melanocyte proliferate and migrate upwards and start actively synthesizing melanin at the infundibulum. From there they migrate further until they reach the surface of skin. [11,12] Repigmentation rate with this approach appears to be relatively high as only classically resistant areas were treated. In our study, 40% achieved a complete or almost complete repigmentation as compared to 45% excellent results obtained in a study done by Essam Elden M. Mohamed et al. using motor dermabrasion. [13]

Several studies have reported significant repigmentation after dermabrasion of the vitiliginous area with topical application of 5 fluorouracil. [14,15] Repigmentation in vitiligo lesions in our study was either due to pigment dispersion from follicular melanocytes and or by extension of pigment from the edges. The study of Cui, Shen and Wang, who found that the follicular repigmentation may be due to the reactivation of the melanocytes located in the outer root sheath of the hair follicles inside the lesions. [11]

Activation of the adjacent pigmented skin may result in melanocytoses.

In vitro Studies have shown that, low concentration of 5-FU selectively destroys keratinocytes in three weeks. While melanocytes continue to mutiply and form pigment. Our study was in concordance with study of Sethi, et al done in 2007, who found that hyperpigmentation is a known side-effect of 5-fluorouracil, observed during the treatment of skin tumors and psoriasis.

In their study the response rate was 73.3 % after a treatment period of six months. [10]

## CONCLUSION

Our study concludes by stating that laser skin ablation followed by topical 5-fluorouracil cream for 15 days serves as an ideal alternative treatment for stable vitiligo if currently used medical treatment failed.

## REFERENCES

1. Sehgal VN, Srivastava G. Vitiligo: Compendium of clinico-epidemiological features. Indian J Dermatol Venereol Leprol 2007;73:149-56
2. Kovacs SO. Vitiligo. J Am Acad Dermatol 1998;38:647-66.
3. Savant SS. Surgical therapy of vitiligo: Current status. Indian J Dermatol Venereol Leprol 2005;71:307-10.
4. Gupta S, Jain VK and Saraswat PK. Suction skin grafting in recalcitrant and stable vitiligo. Dermatol Surg 1999;25: 955.
5. Koga M. Epidermal grafting using the tops of suction blisters in the treatment of vitiligo. Arch Dermatol 1998;124: 1656.
6. Olsson MJ and Juhlin L. Leucoderma treated by transplantation of a basal cell layer enriched suspension. Br J Dermatol 1998;138:644.
7. Sanjeev V & Mulekar. Long-term follow-up study of segmental and focal vitiligo treated by Autologous – Non-cultured melanocytes–keratinocyte cell transplantation. Arch Dermatol 2004; 140:1211-15.
8. Falabella R. Repigmentation of stable leukoderma by autologous mini-grafting. J Dermatol Surg Oncol 1986;12:172.
9. Tsuji T & Hamada T. Topically administered 5- fluorouracil in vitiligo. Arch Dermatol 1983;119:722-27.
10. Sethi S; Mahajan BB; Gupta RR; Ohri A. Comparative evaluation of the therapeutic efficacy of dermabrasion, dermabrasion combined with topical 5-fluorouracil cream, and dermabrasion combined with topical placentrex gel in localized stable vitiligo. Int J Dermatol 2007;46:875-79.
11. Cui J, Shen LY, and Wang GC. Role of hair follicles in the repigmentation of vitiligo. J Invest Dermatol 1991; 97, 410-16.
12. Lerner AB. On the etiology of vitiligo and gray hair. Am J Med 1971;51:141-47.
13. Essam Elden M. Mohamed et al. Dermabrasion followed by topical 5-Fluorouracil in the treatment of stable vitiligo. The Gulf J Dermatol Venereol 2013;20:31-34
14. Ghoz MM. Vitiligo treatment by topical application of 5-fluorouracil cream following dermabrasion. Egypt J Dermatol Venereol 1996;16:79.
15. Anbar T, Westerhof W, Abdel-Rahman Amal, El- Khayyat M; El-Metwall Yasser. Treatment of periungual vitiligo with Erbium-YAG-laser plus 5-fluorouracil: a left to right comparative study Journal of Cosmetic Dermatology 2006;5:135-39.

How to cite this article: George M, Mallikarjun M, Manjunath. P et al. Efficacy laser dermabrasion followed by topical 5- fluorouracil in the treatment of stable vitiligo. Int J Health Sci Res. 2017; 7(4):144-147.

\*\*\*\*\*