

# Management of Intracranial Epidermoids, an Experience at a Tertiary Care Centre in North East India

**B.K.Baishya<sup>1</sup>, Mrinal Bhuyan<sup>2</sup>, Deep Dutta<sup>3</sup>, Abinash Dutta<sup>3</sup>, Rishikant Singh<sup>3</sup>, Junaid Ahmed<sup>3</sup>, Rajib Hazarika<sup>4</sup>**

<sup>1</sup>Professor and HOD, Department of Neurosurgery, Gauhati Medical College and Hospital

<sup>2</sup>Associate Professor, Department of Neurosurgery, Gauhati Medical College and Hospital

<sup>3</sup>Senior Resident, Dept. of Neurosurgery, Gauhati Medical College and Hospital

<sup>4</sup>Associate Professor of Anaesthesiology, Gauhati Medical College and Hospital

Corresponding Author: Deep Dutta

## ABSTRACT

**Objective:** Epidermoid tumours are benign lesions representing 1% of all intracranial tumours. Surgical treatment is challenging because of its slow growth along the natural neurovascular and cisternal planes. We present in this report our experience of management of these lesions in a cohort in North East India.

**Methods:** 16 cases of intracranial epidermoids confirmed by computed tomography (CT) and magnetic resonance imaging (MRI) of brain in plain, contrast and other relevant studies were enrolled in the study conducted between January 2010 to December 2015. Demographic data, details of clinical presentation, surgical management and follow up were documented for each patient. All the patients were operated in Gauhati Medical College and Hospital. All patients were followed-up routinely by clinical examination and neuroimaging. Average follow-up was 24 (range-11-60) months.

**Results:** 11 patients presented with cerebellopontine angle (CPA) epidermoids extending to various basal cerebrospinal fluid (CSF) cisterns, there were 3 cases of para and suprasellar epidermoids and 2 cases of sylvian fissure epidermoids. The patients underwent surgery between 2010 to 2015. The mean age at presentation was 34.32 years with maximum age of 49 years and minimum 17 years in our series. Total excision was achieved in 12(75%) cases. In 4(25%) cases parts of the cyst capsule were left behind because they were adherent to the brainstem and other critical neurovascular structures. One patient died post operatively following aspiration pneumonitis and infection. No recurrence was recorded till writing this paper.

**Conclusions:** Intracranial epidermoid are rare benign tumours. Total resection should be the goal to minimize the risk of postoperative aseptic meningitis, hydrocephalus, and tumour recurrence. Modern neurosurgical tools and microsurgery techniques have considerably improved the completeness of cyst resection without neurological deficits.

**Key Words:** Intracranial epidermoid, Benign tumours.

## INTRODUCTION

Epidermoid tumours are congenital benign slow growing masses that are believed to originate from misplaced epithelial rests during the first weeks of embryonic life. <sup>[1]</sup> These tumors are called pearly tumours of Cruveilhier 1829 <sup>[1]</sup> also described as the most beautiful tumour of

the body. <sup>[2]</sup> Bailey described it as ‘ghost of epithelial cells’ as the mass is slow growing that develops from the desquamated keratin and epithelial debris and cell derived from the lining epithelial capsule. These tumors appear like a cyst in neuroimaging studies. Keratin and cholesterol accumulation contributes toward the development of these

tumors which are breakdown products created by the desquamation of epithelial cells. [3] As these tumors have tendency to grow along available cisternal spaces, here is no mass effect for long and remain asymptomatic for many years. [4,5]

## MATERIALS AND METHODS

Ethical clearance was obtained from the ethics committee of Gauhati Medical College and Hospital. Between January 2010 to December 2015, 16 cases of intracranial epidermoid were diagnosed clinically and radiologically by computed tomography (CT) and magnetic resonance imaging (MRI) of brain. Surgical planning was done based upon radiological finding. All of the patients underwent operation in the Department of Neurosurgery, Gauhati Medical College and Hospital. Post operative clinical information, including neurological deficits, seizures, and tumour recurrence were evaluated. All post operative patients were followed-up routinely by clinical examination and neuroimaging. Average follow-up was 24 (range: 11-60) months.

## RESULTS AND OBSERVATIONS

There were 9 (56.25%) males and 7 (43.75%) females in this series of 16 patients. The patients ages range from 17 to 49 years (mean 34.32 years). The interval between onset of symptoms and signs and diagnosis ranged between 6 months to 10 years (mean 3 years). The patients presented with various clinical signs and symptoms as listed in table 1. Headache followed by hearing loss and gait disturbances were the most common presenting symptoms. Involvements of the fifth and eighth cranial nerves were the most common neurological deficit in this series. All patients underwent CT scan and MRI of brain. Clinical data is presented in Table 2.

**Neurosurgical approaches:** In our series, the most appropriate approach according to the tumour location was chosen for surgery. Cerebellopontine angle tumours were excised via a suboccipital retromastoid

approach. Tumours extending supratentorially needed a combine retromastoid and subtemporal approach. However tumours commonly extend into the hiatus and this incisural could be completely removed by a posterior fossa approach. Frontobasal tumours were removed via a frontal craniotomy. Similarly temporoparietal craniotomy for a tumour located in temporoparietal location and a pterional approach for tumours around sylvian fissure were adopted.

**Procedure:** All surgeries were done in a single stage. The aim of the surgical approach was maximal tumour excision with minimal risk to surrounding critical structures. In all cases, the epidermoid's thin membranous capsule was opened early and internal decompression was initially performed. In every case the usual technique of intracapsular tumour removal and extracapsular dissection was done keeping in mind that nerves and vessels are embedded in the mass and may be tenaciously adhered to it. Total resection was achieved in 12 cases and subtotal resection in 4 cases. The capsule was adherent to nerves and vessels and hence was left intact in the latter cases. Irrigation was done with use of cotton pads to reduce spillage of cyst contents in the subarachnoid space. A post operative course of dexamethasone (16-24 mg/day) was given for one week and gradually tapered.

We documented complications in the form of cranial nerve deficits as listed in the table 2. 8 of the 16 cases developed cranial nerve deficits post-operatively. Most common nerves involved were VII and VIII. Only 2 patients developed permanent deficits, both of the VIIIth nerve. The rest were all transient and improved with 3 to 4 weeks.

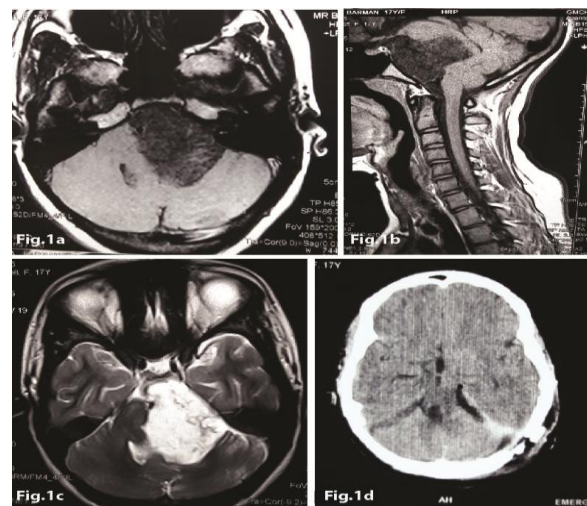
The patients underwent follow-up CT and/or MR imaging within the first 24 hours after surgery to document post operative changes and extent of resection. Patients with complete resection underwent annual MR imaging for three years and then two years thereafter. Patients having

residual tumour were followed up with MR imaging every 6 monthly for two years then annually thereafter.

**Illustrative case 1:** A 17 years old female patient presented with one and half years duration of difficulty in walking and tendency to fall due to imbalance, one year history of gradual loss of hearing over left ear and three months duration of slurring of speech, headache, blurring of vision and difficulty in swallowing. On examination, bilateral cerebellar signs with involvement of left sided 5<sup>th</sup>, 8<sup>th</sup>, 9<sup>th</sup> and 10<sup>th</sup> cranial nerves was found along with right sided spastic lower limb with preserved power of all the four limbs. Sensation and autonomic functions were intact. Visual acuity was 6/9 bilateral with early secondary papilledema. On MRI examination, a lobulated cystic extraaxial mass lesion in the left cerebello-pontine angle cistern was seen, widening the same with base towards the petrous temporal bone. The mass protruded into the internal acoustic canal widening the same (0.4cm). The lesion also protruded into the left hypoglossal canal and meckel's cave. The mass showed T1 hypointense and hyperintense on T2WI. The mass had encased the basilar artery and ipsilateral vertebral artery and trigeminal nerve. The lesion measures approximately (5x5x5.6)cm. The intracanalicular component measures (0.8x 0.4) cm. There was mass effect on the midbrain, pons, cerebellar peduncles, and cerebellar hemisphere and medulla which were displaced to the right. The mass also compressed the 4<sup>th</sup> ventricle with resultant upstream prominence of the ventricular system. The lesion showed diffusion restriction. On post contrast study the lesion did not show any appreciable enhancement.

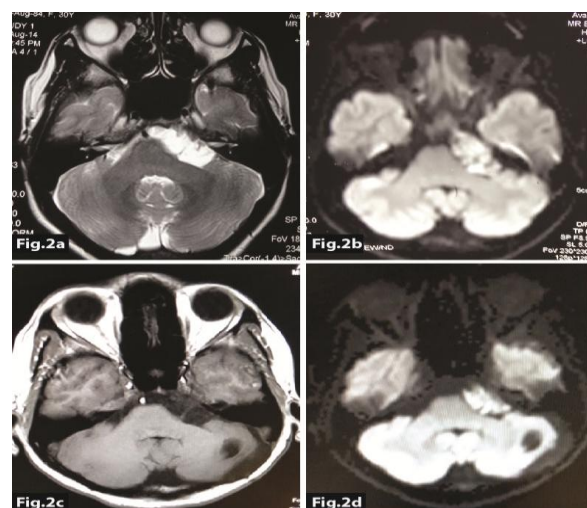
The tumour was approached via a left sided suboccipital retrosigmoid craniotomy. After opening the dura, epidermoid was visualized as a not well vascularised white mass filling the entire cerebello-pontine angle (CPA) cisterns. Cyst removal was done in a lateromedial direction, starting from the bone moving

towards the brainstem because it was easier to identify cranial nerves near the bony or dural entrance where their anatomy was relatively well preserved. Post operatively she developed left sided 6<sup>th</sup> nerve palsy. Her gait improved and post operative CT scan showed minimal residual tumour. She is on follow up with advice of 6 monthly MRI for two years. FIGURE 1



**Figures of illustrative case 1:**

**Fig.1a:** T1 axial image showing a well demarcated hypointense mass in left CP angle cistern compressing the pons and fourth ventricle. **Fig.1b:** T1 sagittal image showing an extraaxial lobulated mass in the CP angle cistern extending to the pre-pontine cistern and abutting the midbrain. **Fig.1c:** T2 axial image showing a well demarcated mass in left CP angle cistern extending to the pre-pontine cistern with hypodense septae within. **Fig.1d:** Post operative plain CT image of the same tumour, done after 24 hours, showing minimal residual tumour.



**Figures of illustrative case 2:**

**Fig 2a:** T2 axial image showing a hyperintense cystic lesion in the left CP angle insinuating the pre-pontine and premedullary cisterns. **Fig.2b:** Diffusion weighted image showing DWI restriction with low ADC values. **Fig 2c:** Post-operative FLAIR (Fluid attenuated Inversion Recovery) image done after 1 year, showing residual tumour with incomplete suppression. **Fig.2d:** Post-operative Diffusion weighted image (DWI) of the same tumour showing restricted diffusion.

**Illustrative case 2:** A 22 years old female patient presented with 7 years history of lancinating pain over left side of her lower face which was gradually increasing in intensity. She was diagnosed with trigeminal neuralgia on clinical examination. Her MRI showed a lobulated T1 hypo and T2 hyperintense cystic lesion showing incomplete suppression in FLAIR sequences noted in the left CP angle insinuating anteroinferiorly to prepontine and premedullary cisterns exerting pressure effect on pons, left middle cerebellar peduncle, flocculus and left cerebellar hemisphere showing DWI restriction with low ADC values. No enhancement noted on post contrast study. Lower pons, medulla and basilar artery were displaced and rotated to the right side with mild flattening and elongation of left middle cerebellar peduncle. Encasement and lateral displacement of left V and VII- VIII nerve complex noted. The lesion also encased the

left SCA without any luminal stenosis. Features were suggestive of epidermoid cyst. FIGURE 2

She was operated with left retromastoid suboccipital craniotomy and excision. The tumour was pearly white that was engulfing the trigeminal nerve. With meticulous microdissection total excision of the tumour could be achieved. Post operatively her pain was relieved substantially although not completely and now she is on regular follow up with MRI Brain every 6 monthly.

**Table 1: Symptoms and signs in 16 cases of intracranial epidermoid.**

| Symptoms and signs   | Percent    |
|----------------------|------------|
| Hearing loss         | 8(50%)     |
| Dizziness            | 6(37.5%)   |
| Gait disturbance     | 8(50%)     |
| Trigeminal neuralgia | 3(18.75%)  |
| Diplopia             | 2(12.5%)   |
| Visual impairment    | 6(37.5%)   |
| Seizure              | 4(25%)     |
| Headache             | 11(68.75%) |

**Table 2: Clinical data**

| SL-no | Age /sex | Location                                | Clinical features  | Operation                               | Complications (cranial nerve deficit) | Last follow up (Yes/No) | Remarks Residual tumour (Yes/ No) |
|-------|----------|---|--|---|---------------------------------------|-------------------------|-----------------------------------|
| 1     | 17 y/F   | Left sylvian fissure                    | Headache, Seizure  | Left pterional craniotomy and excision  | None                                  | Yes                     | No                                |
| 2     | 24y /M   | Right CPA with middle fossa extension   | Headache, hearing loss, gait disturbance, seizure                                  | Right RMSO craniotomy and excision      | VII                                   | Yes                     | No                                |
| 3     | 25y/m    | Left CPA                                | Trigeminal neuralgia   | Left RMSO craniotomy and excision       | V                                     | Yes (symptoms relieved) | No                                |
| 4     | 44y/M    | Right CPA with transtentorial extension | Hearing loss, tinnitus, gait ataxia, headache, vomiting, visual disturbances       | Right RMSO craniotomy and excision      | None                                  | Yes                     | No                                |
| 5     | 25 y/F   | Right sylvian fissure                   | Headache, seizure  | Right pterional craniotomy and excision | None                                  | Yes                     | No                                |
| 6     | 35 y/M   | Parasellar                              | Headache, memory impairment, personality changes                                   | Rt. Frontal craniotomy and excision     | III                                   | Yes                     | No                                |
| 7     | 42y/M    | Right CPA with transtentorial extension | Headache, hearing loss, gait abnormality   | Right RMSO craniotomy and excision      | VII                                   | Yes                     | No                                |
| 8     | 30y/F    | Right CPA and foramen magnum extension  | Hearing loss, headache, vomiting, dizziness, gait abnormality, visual disturbances | Right RMSO craniotomy and excision      | VIII,                                 | Yes                     | Yes                               |
| 9     | 36y/F    | Left CPA                                | Right sided hearing loss, tinnitus, gait abnormality.                              | Left RMSO craniotomy and excision       | VIII                                  | Yes                     | No                                |
| 10    | 42y/M    | Parasellar                              | Lower limb weakness, seizure   | Right Frontal craniotomy and excision   | None                                  | Yes                     | No                                |

**Table 2. Continued...**

|    |         |  |   |  |   |                         |     |
|----|---------|--|---|--|---|-------------------------|-----|
| 11 | 24 y /M | Right CPA and Perimesencephalic with extension to post.third ventricle | Headache, diplopia, hearing loss, facial asymmetry, gait abnormality, swallowing difficulty                                 | Midline suboccipital with supracerebellar infratentorial approach and excision | Died (post operatively due to aspiration pneumonitis and chest infection) |                         | Yes |
| 12 | 49y/F   | Left CPA   | Trigeminal neuralgia  | Left RMSO craniotomy and excision  | None  | Yes (symptoms relieved) | No  |
| 13 | 42y/M   | Parasellar   | Diplopia, headache  | Right frontal craniotomy and tumour excision via subfrontal approach           | VI  | Yes                     | Yes |
| 14 | 45y/F   | Left CPA with foramen magnum extension                                 | Left sided hearing loss, facial asymmetry, tinnitus, slurring of speech, gait abnormality, swallowing difficulty, Headache. | Left RMSO craniotomy and excision  | IX,X  | Yes                     | Yes |
| 15 | 22y/F   | Left CPA   | Trigeminal neuralgia  | Left RMSO craniotomy and excision  | None  | Yes (symptoms relieved) | No  |
| 16 | 47y/M   | Left CPA with transtentorial extension                                 | Headache, hearing loss, gait abnormality  | Left RMSO craniotomy and excision.   | None  | Yes                     | No  |

**Table 3: Location and extension of epidermoid 16 cases of**

| Location of lesion                                | No. of Cases |
|---|--------------|
| CPA alone   | 4            |
| CPA + transtentorial                              | 3            |
| CPA + middle fossa extension                      | 1            |
| CPA + Foramen magnum extension                    | 2            |
| CPA + transtentorial and foramen magnum extension | 1            |
| Sylvian fissure                                   | 2            |
| Parasellar  | 3            |

\*CPA=Cerebellopontine angle

**Table 4: Cranial nerve abnormalities in 16 cases of intracranial epidermoid**

| Cranial nerves | Preoperative nerve deficit (%) | Post operative nerve deficit (%) |
|----------------|--------------------------------|----------------------------------|
| III            | 1(6.25%)                       | 1(6.25%)                         |
| IV             | 0 (0%)                         | 0(0%)                            |
| V              | 10(62.5%)                      | 1(6.25%)                         |
| VI             | 4(25%)                         | 1(6.25%)                         |
| VII            | 5(31.25%)                      | 2(12.5%)                         |
| VIII           | 6(37.5%)                       | 2(12.5%)                         |
| IX             | 4(25%)                         | 1(6.25%)                         |
| X              | 4(25%)                         | 1(6.25%)                         |
| XI             | 0(0%)                          | 0(0%)                            |
| XII            | 1(6.25%)                       | 0(0%)                            |

Mean age: 34.32

Maximum age: 49 years

Minimum age: 17 years

Male: 9

Female: 7

## DISCUSSION

Epidermoids account for 0.5% to 1.8% of all intracranial brain tumours. [1] They are slow growing and grow along the neurovascular and cisternal planes and usually encase the nerves and vessels rather than displacing them. [6] For a very long time they remain asymptomatic and mostly become symptomatic during the third to

fifth decades of life. Epidermoids are seen mostly around the basal cisterns like cerebellopontine angle cistern, suprasellar cistern, cerebellomedullary cistern, other sites being sylvian fissure, pineal region, brainstem, petrous apex, intra-fourth ventricular, interhemispheric location which is rare although cases has been reported. [6] The lesions show symptoms following irritation of the nerves or mass effect. The symptoms may be headache, neuralgias, seizures, ataxia, nystagmus, hemiparesis, hemifacial spasm, hydrocephalus and also varied presentations according to the tumour location. [7,8] Because of the location and extension of the epidermoids through the basal cisterns the clinical signs are diverse.

Pathogenesis of epidermoids is congenital neuroectodermal origin, thought to arise from ectodermal inclusions during neural tube closure in the third to fifth weeks of embryogenesis. At the time of embryogenesis the optic and otic vesicles are formed and this may be the region of frequent occurrence of epidermoid tumours in the cerebellopontine angle cistern and the parasellar region. [7-9] Ectodermal inclusions before the third week account for the occurrence of intracerebral and intraventricular epidermoids.

Clinical features - Signs and symptoms occur due to gradual mass effect. Most

common symptom is headache followed by cranial nerve deficits, cerebellar symptoms, raised intracranial pressure.<sup>[10]</sup> In our series, headache was the commonest symptom (68.75%) followed by hearing loss (50%) and gait disturbance (50%). 37.5% of cases presented with visual impairment due to secondary optic atrophy following raised intracranial pressure.

**Neuroimaging:** The typical Magnetic Resonance (MR) image appearance of epidermoid tumours is hypointense on T1W images, iso- to hyperintense on T2W images, similar to MR imaging appearance of arachnoid cysts.<sup>[11,12]</sup> Fluid Attenuated Inversion Ratio (FLAIR) imaging appears as hyperintense lesion distinguishing it from arachnoid cyst.<sup>[13]</sup> But sometimes epidermoid cyst may appear hypointense on FLAIR images so diffusion weighted images (DWI) are done where epidermoids are bright due to diffusion restriction. Epidermoids appear as hypodense lesion on computed tomography (C.T).

Epidermoids, being histopathologically benign, aim of treatment should be total resection without harm to surrounding vital neuro vascular structures.<sup>[10,14]</sup> Unfortunately only 50-80% of intracranial epidermoids can be completely removed.<sup>[15]</sup> In our series, total resection was achieved in 12 cases(75%) and subtotal resection in 5 cases(25%).Cranial nerve deficits of various forms developed post operatively in 8 patients. 6 of the deficits were transient, with 2 being permanent. Aseptic meningitis is a common complication in patients undergoing subtotal resection and is estimated to occur in 40% of these patients.<sup>[16]</sup> The risk of meningitis can be minimized by avoiding spillage of cyst contents into the subarachnoid space, by removal of the epithelial lining and by perioperative administration of corticosteroids as well as irrigation of the surgical site with hydrocortisone.<sup>[16-18]</sup>

Communicating hydrocephalus generally follows aseptic meningitis and may require CSF diversion,<sup>[17]</sup> as had to be done in 8 out of 42 patients in a previous

study. The same precautions adopted for the prevention of aseptic meningitis also prevent hydrocephalus.<sup>[19]</sup> None of our patients developed hydrocephalus.

Epidermoids are known to recur, especially if removed partially. As these lesions are congenital, the time to symptomatic recurrence following total excision may be estimated as age at time of diagnosis plus 9 months.<sup>[20]</sup> The chance of symptomatic recurrence during one's lifetime following total excision may be negligible or practically absent.<sup>[15,17,19,21]</sup> An overall recurrence rate of 24% has been found in older studies.<sup>[19]</sup> No recurrence was encountered in our series during follow up.

## CONCLUSION

Epidermoids are rare, benign intracranial tumours. Being an indolent tumour, the goal of total resection should be weighed against the risk of potential complications if the tumour is adherent to critical neurovascular structures. Early diagnosis and total or near total excision of the tumour using contemporary microneurosurgical techniques can cure the patient with the expectation of normal life. The disease can be well managed by surgical treatment.

## REFERENCES

1. Bailey, P. (1920). Cruveilhier's 'tumeurs perlees.' Surg. Gynec. Obstet.,31, 390,401.
2. Dandy, W.E. (1945). Surgery of the Brain. Prior: Hagerstown, Md.
3. Abramson RC, Morawetz RB, Schlitt M. Multiple complications from an intracranial epidermoid cyst: case report and literature review. Neurosurgery. 1989 Apr; 24(4):574-8.
4. Alvord EC., Jr Growth rates of epidermoid tumors. Ann Neurol. 1997;2:367-70.
5. Bartal A, Razon N, Avram J, Rockkind S, Doron A. Infratentorial epidermoids. Acta Neurochir (Wien) 1988;42:142-6.
6. Ulrich J. Intracranial epidermoids: a study on their distribution and spread.

- Journal of neurosurgery. 1964 Dec;21 (12):1051-8.
7. Guidetti B, Gagliardi FM. Epidermoid and dermoid cysts. J Neurosurgery 1977;47:12-8.
  8. Kato K, Ujiie H, Higa T, Hayashi M, Kubo O, Okada Y, Hori T. Clinical presentation of intracranial epidermoids: a surgical series of 20 initial and four recurred cases. Asian journal of neurosurgery. 2010 Oct 1;5(1):32.
  9. Kubota H, Kondo A, Iwasaki K. cerebellopontine angle epidermoids presenting with cranial nerve hyperactive dysfunction: Pathogenesis and long-term surgical results in 30 patients. Neurosurgery 2002;50:276-286.
  10. de Souza CE, de Souza R, Da Costa S, Sperling N, Yoon TH, Abel Hamid MM, et al. Cerebellopontine angle epidermoid cysts: A report of 30 cases. J Neurosurg Psychiatry 1989;52:986-90
  11. Gualdi GF, Di Biasi C, Trasimeni G, Pingi A, Vignati A, Maira G. Unusual MR and CT appearance of an epidermoid tumor. AJNR Am J Neuroradiol 1991;12:771-2.
  12. Kallmes DF, provenzale JM, Cloft HJ, McClendon RE. Typical and atypical MR imaging features of intracranial epidermoid tumours. AJR Am Roentgenol 1997;169:883-7.
  13. Karantanas AH. MR imaging of intracranial epidermoid tumors: specific diagnosis with turbo-FLAIR pulse sequence. Comput Med Imaging Graph 2001;25:249-55.
  14. Altschuler EM, Jungreis CA, Sekhar LN, Jannetta PJ, Sheptak PE: Operative treatment of intracranial epidermoid cysts and cholesterol granulomas, report of 21 cases. Neurosurgery 26:604-614, 1990.
  15. Samii M, Tatagiba M, Piquer J, carvalho GA: Surgical treatment of epidermoid cysts of the cerebellopontine angle. J Neurosurgery 84:14-19, 1996.
  16. Yamakawa K, Shitara N, Genka S, Manaka S, Takakura K: Clinical course and surgical prognosis of 33 cases of intracranial epidermoid tumours, Neurosurgery 24:568-53, 1989.
  17. Yarasil MG, Abernathy CD, Sarioglu AC. Microsurgical treatment of intracranial dermoid and epidermoids tumors. Neurosurgery 1989;24:561-7.
  18. Sabin HI, Bordi LT, Simon L: epidermoid cysts and cholesterol granulomas centered on the posterior fossa: twenty years of diagnosis and management, Neurosurgery 2:798-805, 1987.
  19. Akar Z, Tanriover N, Tuzgen S, Kafadar AM, Kuday C. Surgical Treatment of Intracranial Epidermoid Tumors. Neurol Med Chir 2003;4:275-81
  20. Dhananjaya I. Bhat, B. Indira devi, Raghunath A: Interhemispheric epidermoids- An uncommon lesion in an uncommon location: A report of 15 cases; *neuro india* 2011 ;
  21. Alvord EC Jr. Growth rates of epidermoid tumours. *Ann Neurol* 1977;2:367-70

How to cite this article: Baishya BK, Bhuyan M, Dutta D et al. Management of intracranial epidermoid, an experience at a tertiary care centre in North East India. *Int J Health Sci Res.* 2017; 7(4):54-60.

\*\*\*\*\*