

Case Report

# Immature Teratoma with Gliomatosis Peritonei: A Rare Case Report

Dr. Bishal Datta<sup>1</sup>, Dr. Manisa Mohanty<sup>1</sup>, Dr. Ramesh Chandra Mohanty<sup>2</sup>,  
Dr. Raghmani Mohanty<sup>3</sup>

<sup>1</sup>Final Year Postgraduate Student, <sup>2</sup>Professor, <sup>3</sup>Professor & Head of the Department,  
Department of Pathology, Hi-Tech Medical College and Hospital, Bhubaneswar, Odisha,

Corresponding Author: Dr. Manisa Mohanty

Received: 04/02/2017

Revised: 22/02/2017

Accepted: 02/03/2017

## ABSTRACT

The aim of reporting this unusual case is to identify mature glial tissue deposits in the peritoneum in a case of immature teratoma of right ovary; a diagnostic challenge for a neophyte in pathology. We report a case of a 60 year old female with complaints of vague abdominal pain for 1 year. On ultrasonographic examination, the right ovary was found to be enlarged and was followed by salpingo-oophorectomy. Intra-operatively, small papillary excrescences were noticed in the omentum so it was also sent for histopathological examination. Paraffin sections showed features of Grade II *immature teratoma* and immunohistochemistry using GFAP was done for the peritoneal deposits. Immature teratomas accounts for about 20% of all the ovarian tumors and occurs predominantly in children and young women averaging age of 20 years. It is rare phenomenon in postmenopausal women thus making our case a diagnostic challenge. *Gliomatosis peritonei* was confirmed in the omentum, a rare finding about 88 cases have been reported so far worldwide. The first case from India was reported in 1981 by Joshi et al, henceforth, only four cases have been reported.

**Keywords:** Gliomatosis Peritonei (GP), Glial Fibrillary Acidic Protein (GFAP), Immature Teratoma.

## INTRODUCTION

Gliomatosis peritonei (GP) means implantation of neural glial tissue in the omentum. It usually occurs more commonly in a setting of an immature teratoma than mature teratoma. Ovarian teratomas can be classified into immature teratoma, mature teratoma, monodermal teratoma (Neuroectodermal tumors, Struma ovarii and Carcinoid tumor).<sup>[1]</sup> Immature teratoma represents malignant neoplasms of the ovary and it mainly consists of all the three germ cell layers but ectodermal and mesodermal derivatives predominate. In most tumors, a mixture of mature and immature elements is found out of which the immature neuroectodermal tissues are easiest to

recognize. Immature teratomas are histologically graded according to the amount of neuroepithelium present.

## CASE PRESENTATION

A 60 year old female presented to the Gynaecology & Obstetrics department with severe abdominal pain for 15 days but intermittent pain, hirsutism and irregular menses was present since a year. Her other physical findings were normal except for a palpable mass per abdomen. She was advised routine blood tests and an ultrasonography of abdomen. Her blood parameters were normal and ultrasonography revealed right sided heterogeneous ovarian mass measuring

3.8cm X 2.5cm with a cystic lesion within the mass measuring 0.5cm. She was advised to undergo right sided salpingo-oophorectomy. During the operative procedure, small papillary excrescences were noticed in the omentum. The right ovary, fallopian tube and part of the omentum were resected and sent to our Department of Pathology for histopathological examination. Her post-operative recovery was uneventful.

### **PATHOLOGICAL FINDINGS**

The samples were received in two containers. In container labelled as right ovary, a globular mass measuring 4cm X 3cm X 2cm. Outer surface was gray-white and on cut surface a white homogenous mass with a cyst measuring 0.5cm in diameter was present.

In container labelled as omental tissue, an irregular bit of omental tissue measuring 5cm X 3cm was present.

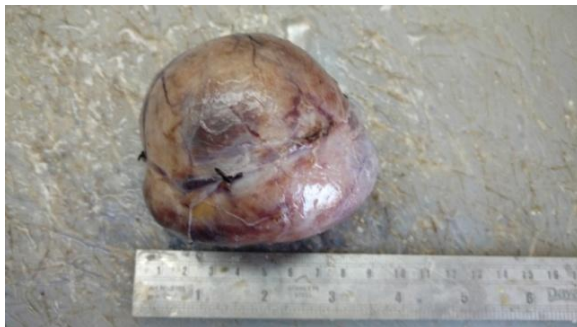

Figure 1. Right ovary

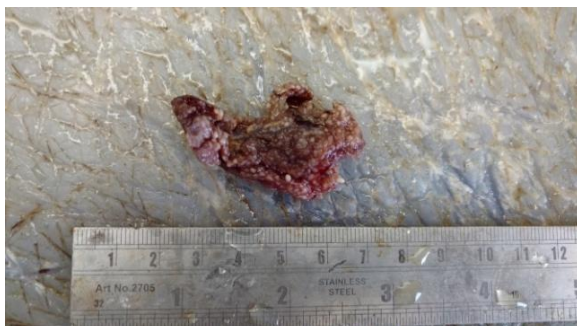

Figure 2. Omental tissue

Histopathological examination of the ovary revealed features of immature teratoma comprising of mature elements like skin, dermal appendages, bony trabeculae, cartilage, salivary glands,

intestinal glands, adipose tissue, smooth muscle. Immature elements mainly consist of primitive neuroectodermal element and glial tissue. There were areas of stellate necrosis within areas of the glial tissue. The neuroectodermal element was present within 3 low power fields (Grade 2).

The omental tissue examination revealed mature (Grade 0) glial tissue deposits which were confirmed by GFAP immunohistochemical stain.

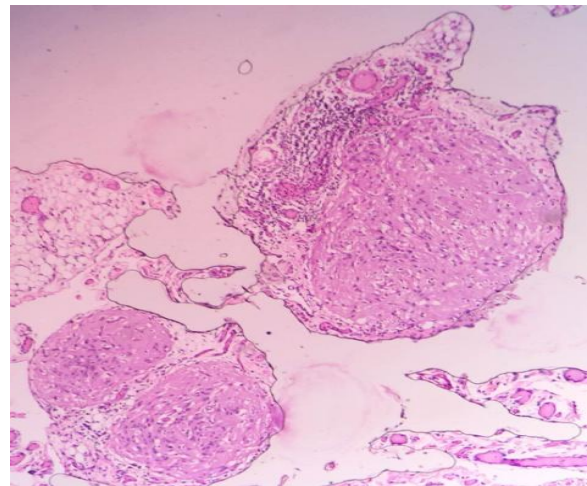


Figure 3. Mature glial implants in omentum

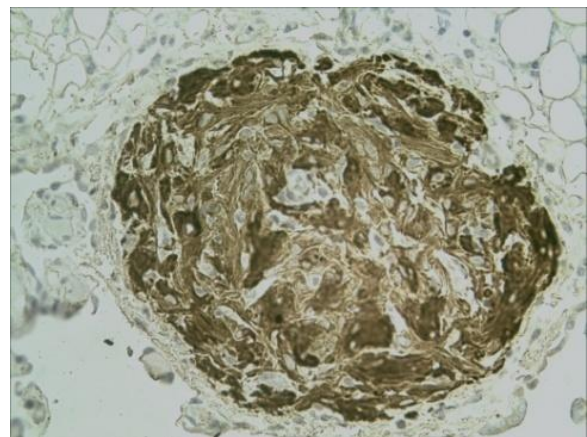


Figure 4. GFAP stain showing glial implants

### **DISCUSSION**

The word teratoma is derived *greek* word 'teras' which means monster. The first description of teratoma was made in 1960 by Thurlbeck and Scully. Teratomas primarily occurs in the ovary and testis. Extragonadal sites are rare but they can arise from thyroid, retroperitoneum, mediastinum, pericardium and brain. Very rarely, teratomas are found in other solid

(e.g. breast, parotid gland, liver) and hollow (e.g. oesophagus, stomach, bladder, uterine cervix) organs. [2]

Immature teratoma accounts for 20% of all ovarian neoplasms and most commonly occurs around 20 years of age and is exceptional in postmenopausal women. [1] The miliary glial deposits in the omentum, i.e. gliomatosis peritonei are a rare phenomenon and only 4 cases have been reported from India so far. [3-7] The first description of gliomatosis peritonei in a case of mature teratoma was given by Joshi et al. in 1981. In literature, a total of 88 cases have been reported till date. [8-10]

The mechanism of gliomatosis peritonei is exactly not known. There are three hypotheses for its origin. Firstly, it may derive from an immature teratoma that undergoes maturation or from cancer stem cells within an immature teratoma. Secondly, it may derive from peritoneal stem cells that differentiate towards the neural lineage induced by factors secreted by the teratoma. Thirdly, it may derive from subperitoneal mesenchymal cells that transdifferentiate into glial cells either directly or through an intermediate stage of induced pluripotent stem-like cells. [11]

Immature teratoma is a malignant condition and it is graded histologically according to the amount of neuroepithelium present. The prognosis of ovarian teratoma is closely associated with tumor grade as proposed by Thurlback and Scully and later modified by Norris et al. Patients with mature glial implants in a case of immature teratoma have a better prognosis if the criteria for diagnosis of gliomatosis peritonei is strictly adhered to.

The criteria to diagnose gliomatosis peritonei as proposed by Thurlback and Scully are:

1) peritoneal surface, omentum and diaphragmatic surface have to be extensively sampled histologically, 2) each of the sampled implants should be composed exclusively or almost exclusively of Grade 0 glial tissue.

The treatment of immature teratoma and gliomatosis peritonei is complete surgical excision. Gliomatosis peritonei has a high recurrence rate and can undergo malignant transformation thus regular monitoring is needed by CT Scan. The prognosis of immature teratoma depends on FIGO staging.

Recent study indicates that Oct4 may serve as a promising biomarker for the diagnosis of highly malignant cases of immature teratoma as the expression of Oct4 has been exclusively detected in immature neuroepithelium of high-grade immature teratomas. [2]

## CONCLUSION

Immature teratoma is a malignant neoplasm mainly affecting first decade of life. Immature teratoma associated with gliomatosis peritonei, surgical removal with combined chemotherapy is recommended. GFAP staining is recommended to demonstrate the glial nature of the peritoneal deposits. One should sample generously the omental tissue to rule out any teratomatous (immature) glial elements wherein the prognosis changes and so does the treatment protocol.

## ACKNOWLEDGEMENT

We are highly privileged to write this column. The committed support from our parents Mr. B N Mohanty, Mrs Prativa Mohanty, Mr. Bipul Datta, Mrs. Lata Datta, has been a constant source for our dynamism.

## REFERENCES

1. Diagnostic Histopathology of Tumor. Charles JZ, Karuna Garg. Tumors of the female genital tract. Part A – Ovary, Fallopian tube, and broad and round ligaments.
2. Ancuta GG, Dana CT. Immature ovarian teratoma with unusual gliomatosis. J Ovarian Res. 2013; 6: 28
3. Joshi JR, Parekh HT, Agrawat HH, Tilak SS. Solid ovarian teratoma with gliomatosis peritonei-a case report. *Indian J Cancer* 1981;18:87-9.
4. Vijayaraghavan M, Kinra G. Gliomatosis peritonei: a rare

- complication of malignant ovarian teratoma. *Indian J Pathol Microbiol* 1987; 30:383-6.
5. Tyagi SP, Maheswari V, Tyagi N, Saxena K, Sharma R, Hameed F. Solid tumors of the ovary. *J Indian Med Assoc* 1993;91:227-30.
  6. Nanda S, Kalra B, Arora B, Singh S. Massive mature solid teratoma of the ovary with gliomatosis peritonei. *Aust N Z J Obstet Gynaecol* 1998;38:329-31.
  7. CJ Das, D Deka. Mature ovarian teratoma with gliomatosis peritonei - A case report. *Indian Journal of Cancer, Vol. 42, No. 3, July-September, 2005, pp. 165-167.*
  8. Sait K, Simpson C. Ovarian teratoma diagnosis and management: case presentations. *J Obstet Gynaecol Can* 2004;26:137-42
  9. Ferry P, de Tayrac R. Peritoneal gliomatosis. A case report and review of the literature *J Gynecol Obstet Biol Reprod* 2003;32:663-7.
  10. Muller AM, Sondgen D, Strunz R, Muller KM. Gliomatosis peritonei: a report of two cases and review of the literature. *Eur J Obstet Gynecol Reprod Biol* 2002;100:213-22.
  11. Liang L, Zhang Y, Malpica A. Gliomatosis peritonei: a clinicopathologic and immunohistochemical study of 21 cases. *Mod Pathol.* 2015 Dec;28(12):1613-20.

How to cite this article: Datta B, Mohanty M, Mohanty RC et al. Immature teratoma with gliomatosis peritonei: a rare case report. *Int J Health Sci Res.* 2017; 7(3):395-398.

\*\*\*\*\*