

Case Report

Optometric Management of Waardenberg Syndrome

Onkar H Pirdankar¹, Dr B Vidyashankar²

¹Research Associate and Faculty, Laxmi Eye Institute, Uran Road, Panvel, 410206

²K. B. H. Bachooali Charitable Ophthalmic and E.N.T. Hospital, Head of Department: Oculoplasty Services, Parel, Mumbai- 400012

Corresponding Author: Onkar H Pirdankar

Received: 20/01/2017

Revised: 10/02/2017

Accepted: 13/02/2017

ABSTRACT

Introduction: Waardenberg syndrome (WS) is rare inherited disorder characterized by varying degree of hearing loss, hair pigmentation, heterochromia iridis, white forelock and facial abnormality.

Case detail: A 21 year old female diagnosed with WS was interested in cosmetic treatment for Heterochromia iridis. Prosthetic contact lens with appropriate color match gives excellent cosmetic appearance in patient with WS especially those who complain of heterochromia of the iris. Here we describe the systematic approach to manage the heterochromia iridis using prosthetic contact lens.

Key-words: Waardenberg syndrome, prosthetic contact lenses, heterochromia iridis

Key Messages: Prosthetic contact lens with proper colour match gives excellent cosmesis in patients with WS who have heterochromia iridis.

INTRODUCTION

Waardenberg syndrome (WS) is a rare, congenital developmental disorder characterized by ocular and non-ocular features. Ocular features include Heterochromia of the iris, normal or hypopigmented fundus, ocular albinism whereas non ocular features include varying degrees of hearing loss, hair pigmentation, white forelock and facial abnormality. [1,2] The prevalence of WS was estimated to be 1 in 42,000. [3] Depending upon the features it is divided into four types WS I – IV. [1] WS I consist of dystopia canthorum and broad nasal root whereas WS II lacks the dystopia canthorum. WS III is a severe form of WS I and is associated with upper limb defects whereas WS IV is characterized by Hirschsprung disease. [1] WS type I, II, III are autosomal dominant

in nature except in type III most of the cases are sporadic in nature and type IV is an autosomal recessive condition. The causes of WS are different for each type and described elsewhere. [1] According to Waardenberg syndrome consortium, [4] individuals should be diagnosed as WS I if they have two major or one major plus two minor criteria from the list in table 1.

Table 1: Diagnostic criteria for Waardenberg syndrome

Major Criteria
Congenital hearing loss
Dystopia canthorum with W index exceeds 1.95
Pigmentary disturbances of the iris
Hair hypopigmentation
Affected first degree relative
Minor Criteria
Congenital leucoderma
Synophreys or medial eyebrow flare
Broad high nasal root
Hypoplasia of alae nasi
Prematurely greying hair

Cosmetic intervention produces positive impact on quality of life in individuals electing to undergo cosmetic

procedures [5] and therefore cosmetic treatment cannot be neglected. We report an optometric management of heterochromia iridis which is seen in rare case of WS.

CASE REPORT

Presenting Signs and Symptoms:

A 21 year old Female, visited our clinic with a complain of difference between the iris color of both her eyes since birth and was interested in prosthetic contact lens in left eye due to cosmetic reason. History of white forelock of hair since birth was noted. Family history was not significant. There was no history of hearing loss, trauma or wearing glasses. Presenting visual acuity was 6/6, N6 in each eye. Color vision was normal. Ocular motility was full, free and painless. Both the pupils were of equal size, round and reacting to light. Detailed evaluation revealed telecanthus and hypertelorism, and heterochromia of iris. Posterior segment was normal. ENT examination was within normal limits. Patient was diagnosed with Waardenberg Syndrome type I. [4] Our case was diagnosed with three major criteria and

included heterochromia of the iris, dystopia canthorum and hypopigmentation of the iris (Figure 1).

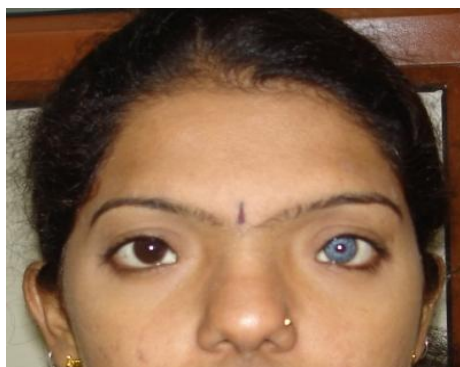


Figure 1. Heterochromia of the iris, telecanthus and hypertelorism

Management:

Pre contact lens evaluation:

Subject underwent pre contact lens evaluation In both eyes which included corneal curvature measurement using keratometer, Horizontal (HVID) and vertical visible iris diameter (VVID), vertical fissure height and pupil diameter measurement using millimeter ruler. Corneal sensitivity was assessed using cotton bud wisp. Table 2 describes the detailed pre contact lens evaluation.

Table 2: Pre contact lens evaluation.

Tests	Right Eye	Left Eye
Keratometry	H: 43.00D X 180 V: 43.50D X 90	H: 43.25D X 180 V: 43.50D X 90
HVID / VVID	13/11mm	13/11mm
Vertical fissure height	11mm	11mm
Iris color observation	Brown	Grey
Pupil diameter	3-4mm	3-4 mm
Corneal sensitivity	Present in all quadrant	Present in all quadrant

Contact lens assessment:

Patient was fitted with two different prosthetic trial contact lenses (Table 3). For each trial corneal coverage, centration, lens movement with blink, lens lag, contact lens

push up test and over refraction was performed. Table 3 describes the contact lens assessment for two different prosthetic contact lenses.

Table 3 Contact lens assessment for two different prosthetic contact lenses.

Assessment	Trial 1 (dark brown iris color with clear pupil 8.6mm base curve, 14.00mm total diameter)	Trial 2 (medium brown iris color with clear pupil 8.8mm base curve, 14.00mm total diameter)
Corneal coverage	360 °	360 °
Centration	Well centered	Well centered
Movement with blink	1-2 mm	2-3 mm
Lens lag	No lens lag	Minimal lens lag
Push up test	50-60%	30-40%
Final comment	Good fit but color was not matching	Slightly flat fit but color was matching
Over refraction (visual acuity)	Plano (6/6, N6)	Plano (6/6, N6)

Final contact lens prescription:

After evaluating both the prosthetic trial lenses for fit and color, the lens parameters were finalized. After giving a thorough knowledge to the patient about the insertion, removal and maintenance the lens was dispensed to the patient. Table 4 describes the final lens parameters. After fitting the

final lens, similar iris color in both eyes was noted (figure 2).

Table 4. Describes the final lens parameters of prosthetic contact lens

Final lens parameters
Base curve : 8.6 mm
Diameter : 14 .00 mm
Power : Plano
Iris color: Medium brown
Pupil: Clear pupil with clear periphery

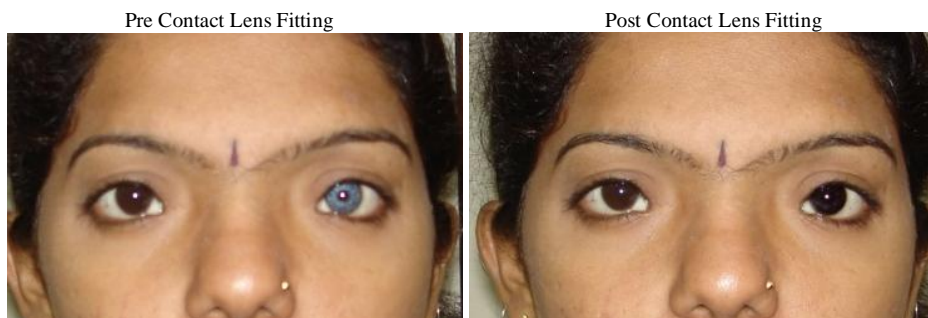


Figure 2 Pre and post prosthetic contact lens

DISCUSSION

We report classic features of rare WS and optometric management of heterochromia iridis. Heterochromia iridis is a major feature that may be observed in WS however none of the studies have reported management for the same. Heterochromia iridis may be segmental or complete. [2] In our case, complete heterochromia was noted unlike the one reported previously where sectoral heterochromia was present. [2,6] Prosthetic contact lens with proper color match gives excellent cosmesis and therefore the best probable option to manage heterochromia iridis in patient of WS.

A distinctive white forelock which is characteristics of WS was also noted in our case however patient did manage it by use of black hair dye for cosmetic reason. The size of the forelock may vary in size from a few hairs to a clump of hair. The site of the forelock is usually in the midline however it may be noted elsewhere. Other features such as dystopia canthorum is also helpful to distinguish type I from others as it is the most common and penetrant feature of WS I. [4] It has the appearance of blepharophimosis and medial fusion of the inner eyelids leading to a reduction in the visibility of medial sclerae. In our case we noted the appearance of blepharophimosis

and fusion of the inner eyelids medially. In this case, patient did not report any hearing loss unlike other cases where varying degrees of hearing loss was observed. [2] Patients with hearing loss can be treated by giving hearing aid.

The patient had normal visual acuity in both eyes and there was no refractive error. However in previously reported cases mild amount of myopia, hyperopia, astigmatism and amblyopia were also observed. Full correction of the refractive error from childhood combined with patching therapy can be considered to treat amblyopia. These cases were managed by patching and refractive error correction. [7] If the patient is complaining of glare then grey tinted lenses can also be prescribed. [7] Corneal parameters were within normal range. Color vision of these patients is normal. [2] We also noted normal color vision in our case.

There is no specific treatment available for WS and may vary depending upon the clinical features and patients needs. Prosthetic contact lens with proper color matching can be considered to treat heterochromia iridis for cosmetic reason. Improved cosmetic appearance could give positive impact on patient’s quality of life.

Conflict interest: None

REFERENCES

1. Read AP, Newton VE. Syndrome of the month Waardenburg syndrome. *J Med Genet.* 1997;34:656–65.
2. Ohno N, Kiyosawa M, Mori H, Wang WF, Takase H, Mochizuki M. Clinical findings in Japanese patients with Waardenburg syndrome type 2. *Jpn J Ophthalmol* [Internet]. 2003;47:77–84.
3. Waardenburg PJ. A New Syndrome Combining Developmental Anomalies of the Eyelids , Eyebrows and Nose Root with Pigmentary Defects of the Iris and Head Hair and with Congenital Deaf- ness. *Am J Hum Genet.* 1951;3.
4. Farrer L a, Grundfast KM, Amos J, Arnos KS, Asher JH, Beighton P, et al. Waardenburg syndrome (WS) type I is caused by defects at multiple loci, one of which is near ALPP on chromosome 2: first report of the WS consortium. *Am J Hum Genet* [Internet]. 1992 May;50:902–13.
5. Demirci GT, Atis G, Altunay IK. Waardenburg Syndrome type 1: A case report. *Dermatol Online J.* 2011;17.
6. Bist J, Adhikari P, Sharma AK. Waardenburg syndrome. *Clin Exp Optom* [Internet]. 2011 Mar [cited 2014 Apr 17];94(2):240–2.
7. Khanal S, Gautam P, Paudel N. Article Waardenburg Syndrome : A Report of Two Familial Case Series. *Optom Vis Perf.* 1992;1:213–6.

How to cite this article: Pirdankar OH, Vidyashankar B. Optometric management of Waardenburg syndrome. *Int J Health Sci Res.* 2017; 7(3):384-387.
