

Case Report

Splenic Lymphoma

B. Ananda Rama Rao¹, P. Sai Kumar², Rama Lakshmi TN²

¹Prof of Surgery; SVS Medical College, Mahabub Nagar TS 500902;

²Resident in Surgery, SVS Medical College, Mahabub Nagar Telangana 500902

Corresponding Author: B. Ananda Rama Rao

Received: 28/12/2016

Revised: 28/02/2017

Accepted: 02/03/2017

ABSTRACT

Splenic lymphoma is an indolent form of mature B-cell neoplasm. It is very rare and overlaps with other lymphomas. The hall mark of clinical presentation is splenomegaly and it usually becomes symptomatic when spleen becomes massive and associated with cytopenia. We discuss here about a 48yr old female with malignant non Hodgkin's lymphoma- spleen. The case is published for its rarity.

Key Words: Splenic lymphoma Non Hodgkin's lymphoma Splenomegaly.

INTRODUCTION

Splenic marginal zone lymphoma accounts for less than 2% of the lymphoid malignancies. Typically, the disease affects elderly or middle aged patients in the sixth decade without any gender predominance.

⁽¹⁾ Clinical presentation is splenomegaly and it usually becomes symptomatic when spleen becomes massive and associated with cytopenia. ⁽²⁻⁴⁾ An increasing number of publications have dealt with multiple aspects of splenic marginal zone lymphoma (SMZL) diagnosis, molecular pathogenesis and treatment ever since the initial description of SMZL was done in 1992. ⁽¹⁾

Marginal zonal lymphomas represent a group of lymphomas whose cells originate from B lymphocytes present in a distant anatomical location of secondary lymphoid follicles. These cells are localized in different organs and depending upon the organs involved, the international lymphoma study group has categorized into three subtypes. ^(5,6) 1) Extra nodal MZL of MALT accounting to 50%-70% of MZL and 7%-8% of all NHL 2) Splenic MZL-20% and < 1% of NHL 3) Nodal MZL-10%. ^(7,8)

We present here a 48yr old female with malignant non Hodgkin's lymphoma-spleen.

CASE REPORT

A 48 years old female within built and moderate nourishment presented to surgical OPD with complaints of pain in left hypochondrium since six months, evening rise of temperature and chills since three months. There was no history of trauma, tuberculosis and no history of malignancies in the family.

On examination: abdomen was soft, non tender and no local rise of temperature. There was no palpable mass in the abdomen, no organomegaly, no palpable lymph nodes.

The routine haematological and biochemical parameters were within normal limits. Upper GI endoscopy was normal. USG abdomen suggested a mass in the spleen. CT scan abdomen and pelvis showed Hypodense peripherally enhancing lesion of 32/29mm(HU-100) in Spleen with right ovarian follicular cyst.(fig1&2)

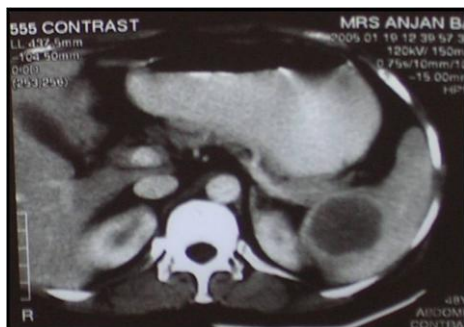


Figure: 1 CT

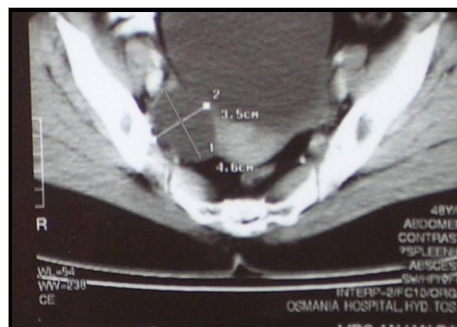


Figure:2 CT

Differential diagnosis of Splenic lymphoma, Hemangioma and Splenic abscess were considered. The plan of management was

splenectomy. Elective splenectomy was done. (Fig 3). The gross specimen on cut section showed growth (Fig 4).

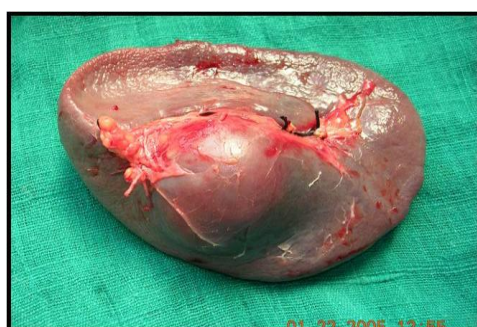

Figure:3 Spleen specimen

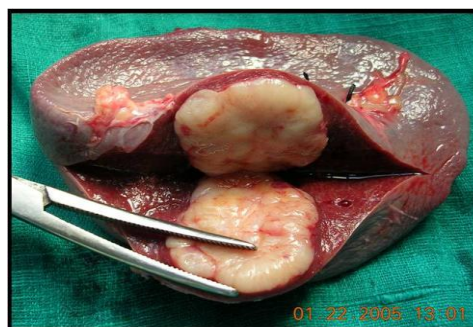

Figure:4 Spleen cut section

Histopathological examination showed highly cellular, dense lymphoid population, Scanty to moderate cytoplasm with large round& oval nuclei. Many lymph globules. Histiocytic cells with vesicular nuclei; focal

areas of fibrosis, hyalinization and ad mixture of small lymphocytes (Figure no 5&6) suggestive of Spleen with malignant non Hodgkin's lymphoma of diffuse large cell cleaved type.

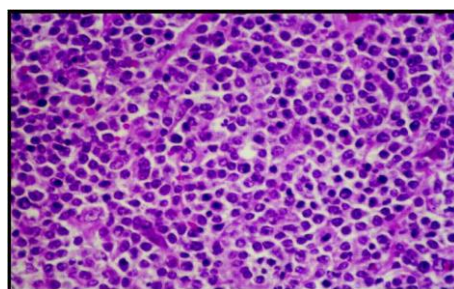


Figure:5 Histology

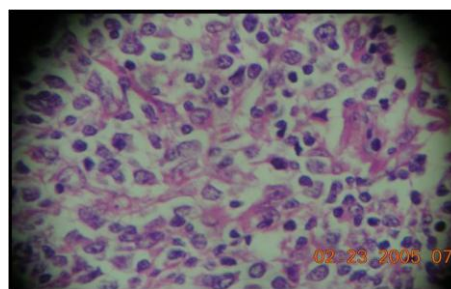


Figure:6 High power

DISCUSSION

Splenic marginal zone lymphoma (SMZL) is an indolent B cell malignancy usually involving spleen, bone marrow and blood presenting as an incidental finding or with symptoms of splenic enlargement or anaemia. Peripheral lymph node involvement is unusual, if it is present, the presentation is usually classified as a disseminated nodal and of splenic subtype.

(4,7) Usually a picture is drawn based on a combination of lymphocyte morphology, immune phenotype, marrow and splenic histology. There is no evidence of genetic role specific for SMZL, but 30-50% of cases show deletions of chromosome 7q. (4)

However, growing evidence indicates that the chronic antigenic stimulation by autoantigens and microbial pathogens, inducing an accumulation of

lymphoid tissue in the typical sites of involvement. Based on epidemiological studies, molecular investigations, and therapeutic success of lymphoma regression with antibiotics, five distinct microbial pathogens have now been identified to be related to MZL. 1) *Helicobacter pylori* associated with gastric MALT lymphoma.⁽⁹⁾ 2) *Borrelia burgdorferi* associated with cutaneous MALT lymphoma.⁽¹⁰⁾ 3) *Campylobacter jejuni*- immune proliferative small intestinal disease (IPSID).⁽¹¹⁾ 4) *Chlamydia psittaci*- ocular adnexal MALT lymphoma⁽¹²⁾ and 5) hepatitis C virus (HCV) associated with MALT, splenic and nodal MZL.^(13,14)

SMZL cells might be mutated or unmutated immunoglobulin variable region genes and probably arise from different subsets of splenic marginal zone B cells. Except for loss of or mutation of the p53 gene the Prognostic factors are poorly defined and are associated very poor outcome.

Previously a definitive diagnosis could only be made after removal of the spleen, but now concept of bone marrow biopsy has evolved for making a conclusive diagnosis because of the peculiar intrasinusoidal Bone Marrow involvement.⁽¹⁵⁾

Prognostic index.

- Haemoglobin level < 12 g/dL
- LDH greater than normal
- Albumin level < 3.5 g/dL

Another index uses Haemoglobin, platelet count, LDH and extrahilar lymphadenopathy to stratify patients prone for risk.⁽¹⁵⁾

THERAPUTIC CHOICES

Conventionally splenectomy is the preferred treatment of choice over chemotherapy. Due to its high efficacy and low toxicity, therapy with Tab RITUXIMAB is likely to be the most beneficial option as a first line therapy. Splenectomy can always be used later if needed.⁽¹⁶⁾

Purine analogues such as Fludarabine have been used with some

success. Though Fludarabine is effective, it is not recommended for its haematologic toxicity.⁽¹⁷⁾ Other purine analogues such as Pentostatin (2-deoxycoformycin), 2-CDA (2-chlorodeoxyadenosine) appear to be showing promising results.

The average survival is 10-13 years and most disease-related deaths are associated with transformation to diffuse large cell lymphoma.

CONCLUSION

WHO classification of lymphoma has provided significant advances in categorizing MZL, but several issues regarding these lymphomas remain unexplained. Collaboration of clinicians and pathologists in diagnosis will help in proper timing of surgical intervention and optimization of the functional, psychological, and aesthetic outcomes. Here we presented a case of 48 year old female with splenic lymphoma surgically treated by splenectomy.

REFERENCES

1. E Matutes, D Oscier, C Montalban, et al. Splenic marginal zone lymphoma proposals for a revision of diagnostic, staging and therapeutic criteria .Nature Publishing Group. 2003; 22, 487–495
2. Mulligan SP, Matutes E, Dearden C, Splenic lymphoma with villous lymphocytes. Natural history and response to therapy in 50 cases. British Journal of Haematology. 1991; 78:206-209.
3. Troussard X, Valensi F, Duchayne E, et al. Splenic lymphoma with villous lymphocytes: clinical presentation, biology and prognostic factors in a series of 100 patients. Groupe Francais' Hematologie Cellulaire (GFHC). Br J Haematol. 1996;93:731-736.
4. Thieblemont C, Felman P, Berger F, et al. Treatment of splenic marginal zone B-cell lymphoma: an analysis of 81 patients. Clin Lymphoma. 2002;3:41-47.
5. Maes B, De Wolf-Peeters C. Marginal zone cell lymphoma— an update on

- recent advances. *Histopathology*. 2002; 40:117-126.
6. Harris NL, Jaffe ES, Stein H, et al. A revised European-American Classification of lymphoid neoplasms. A proposal from the International Lymphoma Study Group. *Blood*. 1994;84:1361-1392.
 7. Jaffe ES, Harris NL, Stein H, Vardiman JW. World Health Organization Classification of Tumours: Pathology and genetics of tumours of haematopoietic and lymphoid tissues. Lyon: IARC; 2001.
 8. Berger F, Felman P, Thieblemont C, et al. Non-MALT marginal zone B-cell lymphomas: a description of clinical presentation and outcome in 124 patients. *Blood*. 2000;95:1950-1956.
 9. Farinha P, Gascoyne R. Helicobacter pylori and MALT Lymphoma. *Gastroenterology*. 2005;128:1579-1605.
 10. Cerroni L, Zochling N, Putz B, Kerl H. Infection by Borrelia burgdorferi and cutaneous B-cell lymphoma. *J Cutan Pathol*. 1997;24:457-461.
 11. Lecuit M, Abachin E, Martin A, et al. Immunoproliferative small intestinal disease associated with Campylobacter jejuni. *N Engl J Med*. 2004;350:239-248.
 12. Ferreri A, Guidoboni M, Ponzoni M, et al. Evidence for an association between Chlamydia psittaci and ocular adnexal lymphomas. *J Natl Cancer Inst*. 2004;96:586-594.
 13. Zucca E, Conconi A, Pedrinis E, et al. Nongastric marginal zone B-cell lymphoma of mucosa-associated lymphoid tissue. *Blood*. 2003;101:2489-2495.
 14. Arcaini L, Paulli M, Boveri E, et al. Splenic and nodal marginal zone lymphomas are indolent disorders at high hepatitis C virus seroprevalence with distinct presenting features but similar morphologic and phenotypic profiles. *Cancer*. 2004;100:107-115.
 15. Carlos montalban, Victor abraira, Luca arcaini et al. Risk stratification for Splenic Marginal Zone Lymphoma based on haemoglobin concentration, platelet count, high lactate dehydrogenase level and extrahilar lymphadenopathy. *British journal of haematology*. 2014;162:864.
 16. Apostolia M, Daniel catovsky, Ellen schlette, et al. Outcomes in Patients With Splenic Marginal Zone Lymphoma and Marginal Zone Lymphoma Treated With Rituximab With or Without Chemotherapy or Chemotherapy Alone. *American Cancer Society*. 2006;107:126
 17. Jennifer R Brown, Jonathan W. Friedberg, Yangfeng et al. A Phase 2 Study of Concurrent Fludarabine and Rituximab for the Treatment of Marginal Zone Lymphomas. *British journal of haematology*. 2009;145(6): 741-748.

How to cite this article: Rao BAR, Kumar PS, Lakshmi TNR. Splenic lymphoma. *Int J Health Sci Res*. 2017; 7(3):376-379.
