

Clinical Profile of Nummular Eczema in a Hilly Population and Associated Xerosis

Renu Rattan¹, Meena Chauhan², Anuj Sharma³, Abhishek Sharma⁴,
Gita Ram Tegta⁵

¹Consultant Dermatologist, Deen Dayal Upadhyay Hospital, Shimla, Himachal Pradesh

²Consultant Dermatologist, Civil Hospital Rohru, Himachal Pradesh,

³Consultant Dermatologist, Regional Hospital Bilaspur, Himachal Pradesh,

⁴Senior resident, Deptt of Dermatology, SLBS Medical College, Ner Chowk, Mandi, Himachal Pradesh,

⁵Professor, Deptt of Dermatology, Indira Gandhi Medical College, Shimla, Himachal Pradesh,

Corresponding Author: Renu Rattan

Received: 27/01/2017

Revised: 16/02/2017

Accepted: 22/02/2017

ABSTRACT

Background: Nummular eczema, a variant of endogenous eczema, is a common dermatoses with a chronic relapsing course. It is often associated with xerosis and impaired skin barrier. This study aimed at evaluating clinical profile of nummular eczema in a hilly population where xerosis of skin is a feature due to dry weather conditions.

Methods: Forty consecutive patients of nummular eczema attending the out- patient department of a tertiary care centre were recruited in the study and their clinical details along with seasonal variation in the course of dermatitis were analysed.

Results: There were 27(67.5%) males and 13(32.5%) females with a mean age of 39.1 ± 19 years. Most commonly involved site was lower limbs (in 72.5% patients), followed by upper limbs (in 50% patients), further followed by trunk (in 45% patients). Winter exacerbation of the dermatitis was seen in 57.5% patients, while 17.5% patients showed summer exacerbation and 25% of patients reported no seasonal variation. No history of atopy was seen in maximum number of patients i.e. 57.5%.

Conclusion: Nummular eczema follows a more chronic and relapsing course in the setting of dry skin conditions. Dry environmental conditions precipitate acute exacerbations of dermatitis.

Key words: Nummular eczema, xerosis, dermatitis.

INTRODUCTION

Nummular eczema is a common type of endogenous eczema first described by Rayer in 1845 with a worldwide prevalence of 0.1% to 9.1%.^[1] It is characterized by coin shaped or oval plaques with a clearly defined border. These lesions are itchy and often overlap with other clinical types of eczema but have no specific histopathological features.^[2] The diagnostic lesion is a coin shaped plaque of closely set, thin walled vesicles on an erythematous base. In the acute phase, the lesions are dull red, oozy, crusted and

highly irritable. They progress towards a less vesicular and more scaly stage, often with central clearing and peripheral extension causing ring shaped or annular lesions. It is very characteristic of this disease that the patches which have become apparently dormant may become active again. Little is known about pathophysiology of nummular eczema, but it is frequently accompanied by xerosis. This study aimed at assessing clinical findings and aggravating factors of nummular dermatitis and to evaluate characteristic pattern of disease in

population of a hilly region related to xerotic skin changes during winter months.

MATERIALS AND METHODS

This study was carried out in out-patient department of Dermatology of Indira Gandhi Medical College Shimla (Himachal Pradesh). Forty consecutive patients diagnosed to have relapsing nummular eczema were recruited in the study. A detailed history coupled with thorough clinical examination was carried out for each of the selected patients. Clinical details regarding age, sex, onset, duration and progression of dermatitis, pattern of distribution of lesions and exacerbation of lesions in relation to season were noted and analysed. Dermatophytic infection was ruled out by doing potassium hydroxide (KOH) mount in all patients.

OBSERVATIONS AND RESULTS

Of the 40 patients of chronic relapsing nummular eczema who participated in this study, there were 27 (67.5%) males and 13 (37.5%) females. The age of the patients ranged between 13 and 75 (mean age- 39.1 ± 19 years). Maximum number of patients i.e. 10 (25%) were in the age group of 10-12 years. Lower limbs was the most commonly involved site i.e. in 29(72.5%) patients, followed by upper limbs in 20 (50%), trunk in 18(45%), hands in 15(37.5%) and feet in 7(17.5%) patients. Thirty three (82.5%) of patients had lesions over more than one site.(Fig. 1 & Fig. 2).

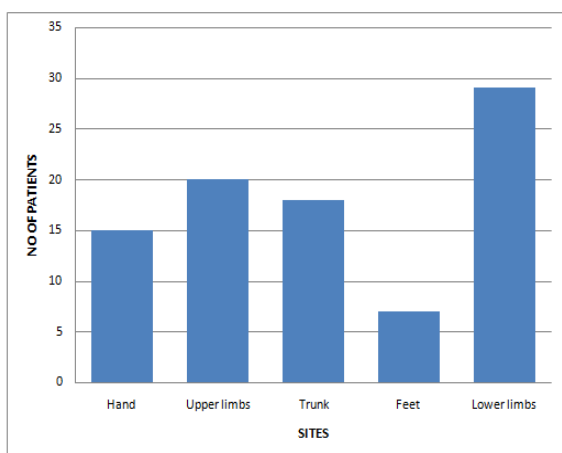


Fig. 1- Sites involved.

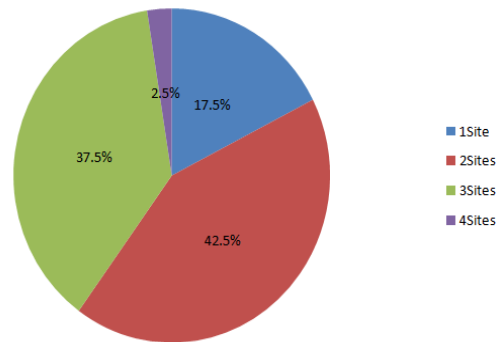


Fig. 2- No. of sites involved

Duration of dermatitis and seasonal variation: The duration of dermatitis varied from nine months to twenty years (mean duration- 66 ± 65.5 months). Twenty three (57.5%) patients presented within five years of developing nummular dermatitis. (Fig 3)

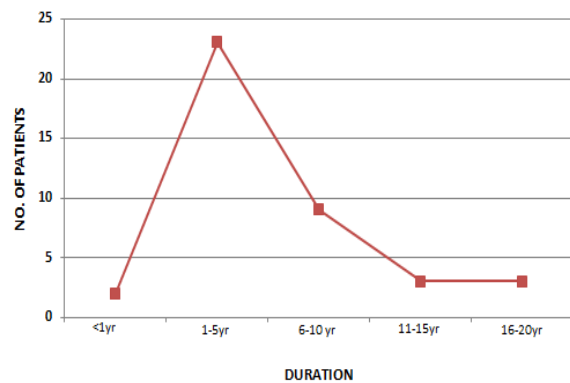


Fig. 3- Duration of Dermatitis

Out of forty patients, 23 patients (57.5%) reported exacerbation of lesions and symptoms in winter season. Seven patients (17.5%) had exacerbation in summer whereas, ten patients (25%) showed no seasonal variation (Fig. 4).

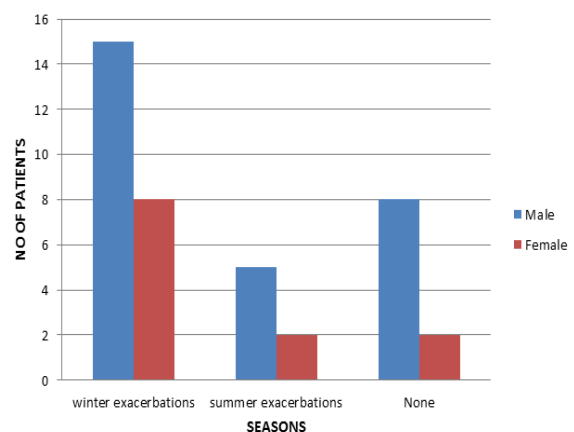


Fig. 4- Seasonal variation

History of atopy: Eight patients (20%) had a positive personal history of atopy, seven patients (17.5%) patients had a positive family history of atopy and two patients(5%) had a positive personal as well as family history of atopy . There was no history of atopy in 23(57.5%) patients. (Fig. 5)

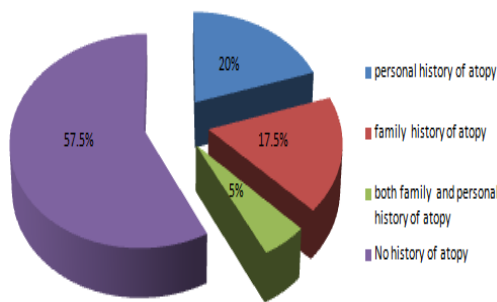


Fig. 5 - History of atopy.

DISCUSSION

The aetiology of nummular eczema is obscure and many aetiological factors have been proposed. Nummular eczema has been reported in all age groups. The lesions can occur over trunk, upper and lower extremities. However, it more commonly involves upper and lower extremities. [3] Incidence of nummular dermatitis is more in males as compared to females and the peak incidence in both males and females is around 50 to 60 years of age. Another peak is seen in female patients at around 15 to 25 years of age. [4]

Forty patients of long standing nummular eczema who participated in the present study were in the age group of 10 to 80 years with mean age of 39.1 ± 19 years. The number of male patients outnumbered the female patients i.e. 67.5% versus 32.5%. The duration of dermatitis varied from nine months to twenty years with mean duration of 66 ± 65.5 months. The median duration of symptoms was six months (range 1-168 months) in a series by Fleming et al [5] and the mean duration of symptoms was 2.5 years in a series by Khurana S et al. [6]

In our study, most commonly involved site was lower limbs i.e. in 72.5% of patients followed by upper limbs, further

followed by trunk. Thirty three (82.5%) patients of the present series had involvement of multiple sites. The most common clinical pattern observed was nummular eczema of limbs and trunk followed by nummular eczema of hands and forearms, and the least common pattern was found to be dry discoid eczema. In a series by DS Krupa Shankar et al dermatitis was present in almost all the sites. In their series, lower limbs were involved in 71.51% and upper limbs in 53.84% patients with lower limbs being the commonest affected site. 57.69% patients had involvement of more than one sites. [7]

The vast majority of patients with nummular dermatitis do not have a personal or family history of atopy. [8] In series of Fleming et al 12% of the patients had atopy defined by the presence of hay fever, asthma or conjunctivitis. [5] Carr R et al found a high incidence of atopy in their patients. [9] In our series 20% of patients had a positive personal history of atopy, 17.5% had a positive family history and 5% of the patients had a positive personal as well as family history of atopy, whereas neither personal nor family history of atopy was there in 57.5% of the patients.

Little is known about pathophysiology of nummular eczema, but is frequently accompanied by xerosis. [10] The xerotic skin of population in a hilly region facilitates the development of cracks and fissures on the skin surface in dry and cold weather. The impairment of cutaneous barrier is further aggravated by inadvertent scratching due to itching allowing various external allergens to permeate through these lesions. Ayoma H et al concluded that nummular eczema is frequently accompanied by xerosis, as the state of hydration of the skin is decreased. Dryness of the skin results in dysfunction of the epidermal bilayer [10,11] and this impaired cutaneous barrier further leads to aggravation of nummular eczema. In series of 100 patients studied by Jiamton S et al. ninety percent of the lesions were located on lower extremities and two third had co-

existing dryness of the skin. [12] In our study mean duration of dermatitis was observed to be 66 ± 65.5 months, pointing towards long duration of the disease. Maximum number of our patients i.e. 22 (57.5%) reported exacerbation of dermatitis in winter season as compared to summer exacerbation seen in 7 (17.5%) patients. There was no clear relationship between age of patients and seasonal variation. Cause of high incidence of patients reporting exacerbation of dermatitis in our study can be explained by cold weather with low humidity in this region leading to decreased hydration of skin resulting in xerosis. This impaired cutaneous barrier in the setting of nummular eczema leads to chronicity and chronically relapsing course of nummular dermatitis.

CONCLUSION

Nummular eczema is common in both sexes with a male preponderance. It is not always associated with history of atopy. Cold weather leading to decreased hydration of skin plays an important role in chronic nature of this dermatitis. Disruption of epidermis secondary to xerosis act as a cause for exacerbations. Maintenance of proper hydration of skin may help in reducing symptoms and acute exacerbations of nummular eczema.

REFERENCES

1. Fritsch O, Reider N. Other Eczematous Eruptions. In: Bologna JL, Jorizzo JL, Rapini RP, editors, *Dermatology*. 2nd edition. Edinburgh : Mosby Elsevier ; 2008. p.203 -204.
2. Lever WF and Lever, editors. *Histopathology of the skin*. 7th ed. Philadelphia: Lippincott; 1989. p. 110.
3. Bonamonte D, Foti C, Vestita M, Ranieri LD, Angelini G. Nummular eczema and contact allergy: a retrospective study. *Dermatitis*. 2012 Jul - Aug. 23(4):153-7.
4. Soter NA. Eczema and lichen simplex chronicus/ prurigo nodularis. In: Freedburg IM, Eisen AZ, Wolff K, Austen KF, Goldsmith LA, Katz SI, editors. *Fitzpatrick's Dermatology in general medicine*. 6th ed. New York: McGraw- Hill; 2003. p. 1194-6.
5. Fleming C, Parry E, Forsyth A, Kemmett D. Patch testing in discoid eczema. *Contact Dermatitis* 1997; 36(5); 261-4.
6. Khurana S, Jain VK, Aggarwal K, Gupta S. Patch testing in discoid eczema. *J Dermatol* 2002; 29: 763-7.
7. Krupa Shankar DS, Shristi Shrestha. Relevance of patch testing in nummular eczema. *IJDVL* 2005; 71(6): 406-408.
8. Cowan MA: Nummular eczema: A review, follow-up and analysis of a series of 325 cases. *Acta Derm Venereol* 41:453-460, 1961.
9. Carr R, Berke M, Becker SW. Incidence of atopy in patients with various neurodermatoses. *Archives of Dermatology* 1964; 89: 20-6.
10. Hiroaki Aoyama, Misako Tanaka, Masahiro Hara, Nobuko Tabata, Hachiro Tagami. Nummular eczema: An addition of senile xerosis and unique cutaneous reactivities to environmental aeroallergens. *Dermatology* 1999; 199(2): 135-139.
11. Ozkaya E. Adult onset atopic dermatitis. *J Am Acad Dermatol* 2005; 52(4): 579-82.
12. Jiamton S, Tangjaturonrusamee C, Kulthanan K. Clinical features and aggravating factors in nummular eczema in Thais. *Asian Pac J Allergy Immunol* 2013 mar; 31(1); 36-42.

How to cite this article: Rattan R, Chauhan M, Sharma A et al. Clinical profile of nummular eczema in a hilly population and associated xerosis. *Int J Health Sci Res*. 2017; 7(3):107-110.
