

Case Report

Carcinoma Erysipeloides: Cutaneous Metastasis Mimicking Benign Disorder

Dr Archit Gupta¹, Dr Shikha Sharma², Dr Mudita Gupta³, Dr Anchana Gulati⁴

¹Postgraduate Student, Department of General Surgery, Indira Gandhi Medical College, Shimla.

²Postgraduate student, ³Assistant Professor,

Department of Dermatology, Venereology and Leprosy, Indira Gandhi Medical College, Shimla

⁴Associate Professor, Department of Pathology, Indira Gandhi Medical College, Shimla

Corresponding Author: Dr Archit Gupta

Received: 29/12/2016

Revised: 13/01/2017

Accepted: 18/01/2017

ABSTRACT

Carcinoma erysipeloïdes (CE) is an uncommon form of cutaneous metastasis which presents as indurated erythematous plaques with raised margins. It is caused by malignant infiltration of dermal lymphatics. CE may be the first manifestation of an unknown primary or may be seen at any other stage of active carcinoma or even after treatment. It mimics many benign conditions hence diagnosis may be delayed. We present two cases of carcinoma breast with CE.

Key words - Carcinoma erysipeloïdes, cutaneous metastasis

INTRODUCTION

Carcinoma erysipeloïdes (CE), sometimes known as inflammatory carcinoma is an uncommon but unique form of cutaneous metastasis. It is most frequently associated with carcinoma of breast but can be associated with other tumors also. ^[1] CE may be primary, when inflammatory changes and malignancy occur at the same time and secondary when erysipeloïdes occurs in a known case of malignancy. ^[2] Primary CE is very rare and if at all seen is usually in breast carcinoma. ^[1] Here we present two cases of CE. Our first case was a 42-year female who presented to us with cutaneous lesions on right side of chest not responding to treatment. Our second case was a 48 year female who was a known case of invasive carcinoma of right breast had undergone breast reconstructive surgery with axillary clearance who presented to us after a year with itchy lesions on right side of chest.

Histopathology of both cases showed CE.

CASE REPORT

Case 1

A 42-year female presented in dermatology clinic with complaints of red raised mildly -itchy, painless, non-oozy lesions over the right side of the chest extending from right axilla to the flank for 3 months. Lesions were initially few in number and rapidly involved right side of the chest and abdomen in a period of 2-3 weeks. She consulted a general practitioner for these lesions where she was suspected to be having contact dermatitis and was prescribed topical super potent steroids. There was slight subsidence of lesions but they did not disappear. No h/o any other systemic complaints were present. General physical examination was within normal limits. On local examination there was diffuse erythema on right side of chest extending from right axilla to right flank –

over the background of diffuse erythema there are multiple erythematous papules coalescing at places to form plaques with whitish fine scaling at places. (Fig.1) Lesions were non-tender but indurated on palpation.

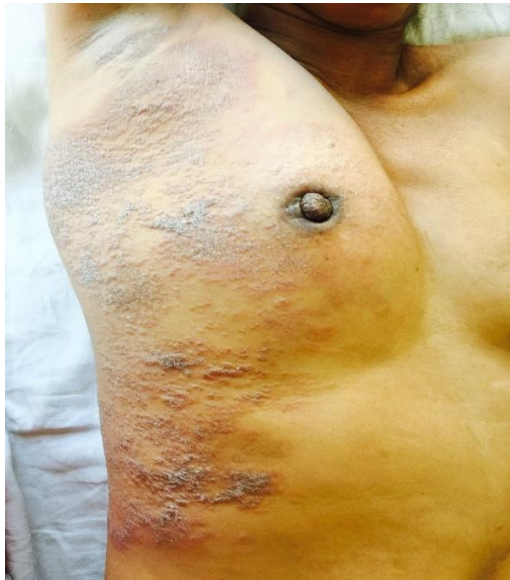

Fig.1 Indurated erythematous papules and plaques

On breast examination a lump was palpable for which she was referred to a surgeon. On inspection symmetry, position, size and shape of right breast appeared to be

normal and similar to left breast. Nipple was retracted. No ulcer or discharge was seen. Palpation revealed a lump of size approx. 4cm X 2cm in upper outer quadrant of breast, non-mobile, not fixed to underlying chest wall or skin. Lymph node examination- A lump of size 1cm X 1cm present in right axilla likely to be the anterior group of lymph nodes (level 1). Supraclavicular or opposite axillary lymph nodes were not palpable. No other abnormality was found on systemic examination

A clinical diagnosis of Carcinoma right breast with? cutaneous metastasis was kept. All routine haematological investigations and chest radiography were within normal limit. Mammography right breast revealed a radiodense mass causing architectural distortion, multiple specks of calcification seen in right upper outer quadrant with minimal nipple retraction and thickening of overlying skin. (Fig.2). Ultrasonography showed hypodense shadow with speculated margins and distortion of breast architecture with thickening and oedema of overlying skin. (Fig.3)

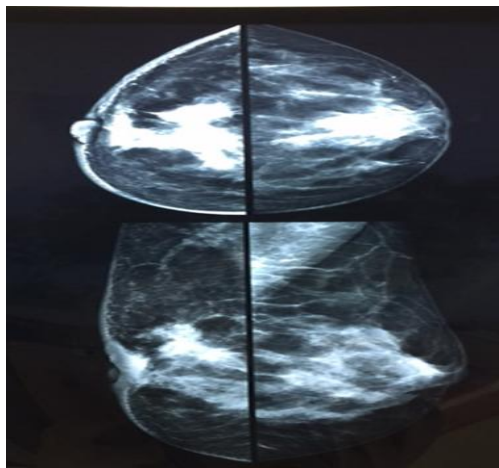


Fig. 2 Mammography findings

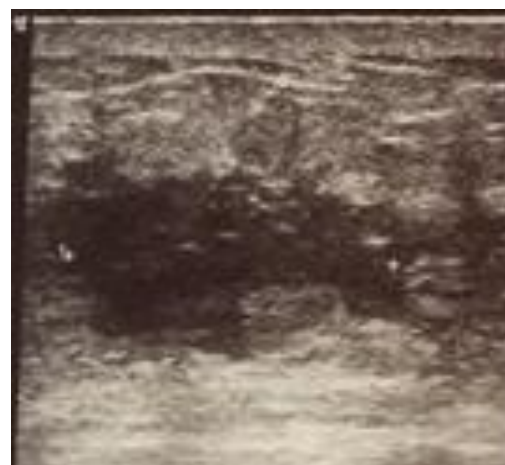


Fig.3 Ultrasound right breast

Histopathology of the skin was consistent with carcinoma erysipeloides showing nests of mitotic cells with central vacuolation (Fig 4). Malignant thrombi are seen in the lymphatics (Fig.5). Breast lump biopsy was consistent with invasive ductal

carcinoma. ER/PR/HER2 neu were negative. Final Diagnosis of Carcinoma right breast with carcinoma erysipeloides was made. Patient underwent breast conservative surgery and was attached to

department of radiation oncology for further treatment in the form of chemo-radiotherapy

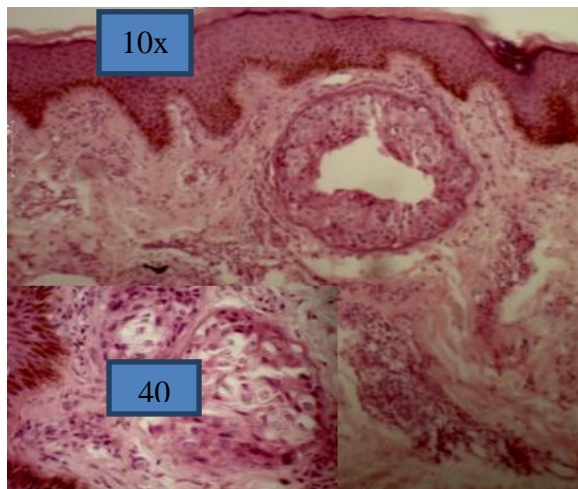


Fig.4HPE of carcinoma erysipeloïdes.

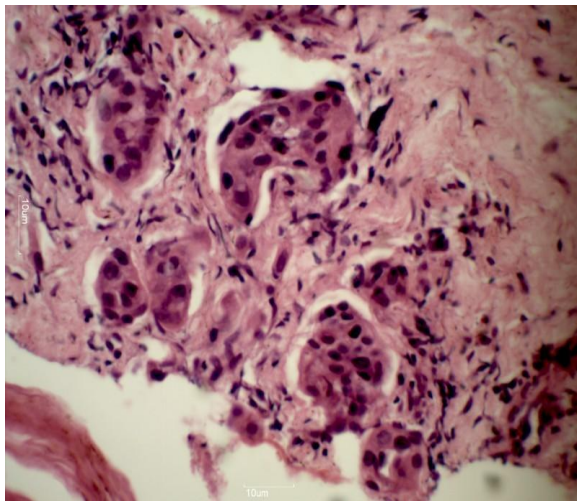


Fig.5malignant thrombus in lymphatics

Case 2

A 48 year female who was a known case of carcinoma breast presented in surgery clinic with history of asymptomatic lesions on right side of chest. Patient had undergone breast conservative surgery on right side with axillary clearance. Biopsy from the surgical specimen showed infiltrating duct carcinoma breast. She was given neoadjuvant chemotherapy for 4 months. She was referred to dermatology clinic one year after the surgery with itchy erythematous lesions over the right side of the chest for the past 2 months for which she had taken multiple courses of antibiotics and topical steroids. On examination she was found to have multi pleerythematous,

indurated papules and plaques extending from axilla to flank on the right side (Fig.6). There was no increased local temperature or tenderness. On examination of the breasts no lump was felt. Histopathology of the cutaneous lesion was consistent with Carcinoma erysipeloïdes. So the final diagnosis of operated case of carcinoma right breast with CE was made and patient was referred to oncology for chemo-radiotherapy.

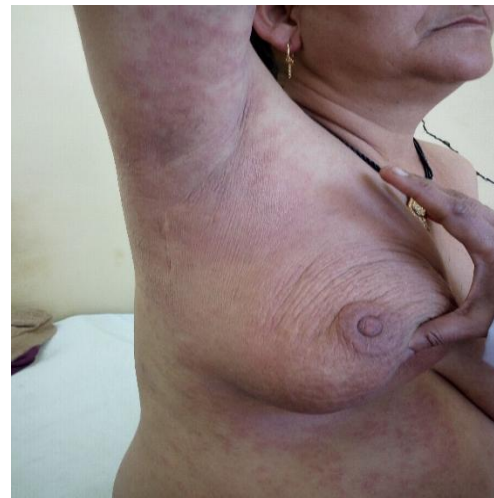

Fig 6 Erythematous indurated plaque

DISCUSSION

Cutaneous metastasis is an uncommon clinical entity with an overall incidence of 0.7% to 10%.^[3] In women, it occurs most commonly from breast with an incidence as high as 26.5%.^[3] Cutaneous metastasis from the breast carcinoma may present with different morphology including nodule, plaque, annular, ulcerative, vesicular, keloidal, sclerodermoid, zosteriform, pigmented melanoma-like, cicatricial, carcinoma en curasse, pagetoid, telangiectatic, and carcinoma erysipeloïdes.^[4,5]

Carcinoma erysipeloïdes (CE) is a rare form of cutaneous metastasis seen in approximately 1% of all cases of malignant breast disease.^[6] In addition to breast CE can be seen in metastasis from carcinoma of parotid gland, thyroid, larynx, lung, fallopian tube, cervix, ovary, colon, prostate, pancreas and stomach.^[7] It was first described in 1924 in a review of 28

cases of breast cancers associated with inflammatory skin changes. These lesions were red indurated plaques with white distinctly margined borders and were associated with malignancies. [8] In 1931 Rasch named them as “carcinoma erysipelatoides” for their similarity to the infectious skin condition erysipelas.

In 2-5 % cases CE may be the first manifestation of unknown primary in breast. [9] Breast cancer patients can present with metastatic cutaneous manifestations at the time of their initial diagnosis as in our first patient or more often they present well after the initial diagnosis and treatment of the breast disease (excision or radiotherapy) as seen in our second case. There is involvement of dermal lymphatic vessels caused by spread from the affected lymph nodes. Malignant thrombi-induced lymphatic obstructions causes the erysipeloid induration, warmth and tenderness and is the diagnostic criteria for CE. [10] There is no acute inflammatory cells in spite of the red and inflamed morphology of the lesion. The median duration of inflammatory skin changes is about 10 weeks after which malignancy is diagnosed. Cutaneous metastatic breast tumour markers like gross cystic disease fluid protein-15 (GCDFP-15) and estrogen receptor protein (ERP) may be helpful. [11]

CE may be misdiagnosed as cellulitis, erysipelas, radiation dermatitis, eczema, herpes zoster, etc. [12] Patients are often treated with course of antibiotics, anti-inflammatory drugs and topical steroids which may show some falsely interpreted improvement due to anti-inflammatory response. As incidence of cutaneous metastasis with breast malignancies is high awareness about this condition can help in early diagnosis of unknown primary malignancy or recurrence of disease. CE is a poor prognostic factor and the average life expectancy is 2 years from the time of diagnosis. Poorer prognostic factors are axillary nodal involvement, younger age at diagnosis, African-American ethnicity, and negative hormone receptor status. [1] Also

early diagnosed CE can be surgically excised beyond margins. [5] Palliative treatment with chemo-radiotherapy may cause regression of disease.

We present this case to highlight the importance of suspecting this condition in a case of known malignancy or in a benign looking dermatosis or other inflammatory conditions not responding to anti-inflammatory treatment. Because of the high incidence of cutaneous metastasis surgeons treating breast carcinoma should examine skin properly at every follow up visit.

REFERENCES

1. Chow HT, Tran K, Ewan K, Millar A, Lynch J, et al. “Diverse Presentations of Carcinoma Erysipelatoides from a Teaching Hospital in Australia,” Case Reports in Dermatological Medicine 2012, Article ID 134938, 5 pages. doi:10.1155/2012/134938
2. Jaiyesimi IA, Buzdar AU, Hortobagyi G, “Inflammatory breast cancer: a review,” Journal of Clinical Oncology 1992; 10: 1014–24.
3. Spencer PS, Helm TN. Skin metastases in cancer patients. *Cutis* 1987;39:119–21.
4. Guillermina Nava, Kenneth Greer, James Patterson, Kant Y Lin. Metastatic cutaneous breast carcinoma: A case report and review of the literature. *Can J Plast Surg* 2009 ; 17: 25–7.
5. Bhattacharyya A, Gangopadhyay M, Ghosh K, Ray P. Wolf in sheep’s clothing: a case of carcinoma erysipeloides. *Oxford Medical Case Reports*. 2016;4:97-100.
6. Gugle A, Malpathak V, Zavar V, Deshmukh M, Kote R. Carcinoma erysipeloides: an unusual presentation mimicking radiation dermatitis. *Dermatol Online J* 2008;14:26-7.
7. Canpolat F, Akpınar H, Eskioglu F, Genel N, Oktay M. A case of inflammatory breast carcinoma: Carcinoma erysipeloides. *Indian J Dermatol Venereol Leprol* 2010;76:215-17.
8. Lee BJ, Tannenbaum NE. Inflammatory carcinoma of the breast: A report of twenty-eight cases from the breast clinic

- of the Memorial Hospital. Surg Gynecol Obstet. 1924;39:580-82.
9. Nambi R, Tharakaram S. Carcinoma erysipeloides as a presenting feature of breast carcinoma. Int J Dermatol 1999; 38:367-8.
 10. Cox SE, Cruz PD. A spectrum of inflammatory metastasis to skin via lymphatics: three cases of carcinoma erysipeloides. J Am Acad Dermatol 1994;30:304-8
 11. Ormsby AH, Snow JL, Su WP, Goellner JR. Diagnostic immunohistochemistry of cutaneous metastatic breast carcinoma: a statistical analysis of the utility of gross cystic disease fluid protein-15 and estrogen receptor protein. J Am Acad Dermatol 1995;32:711-6.
 12. AmeerAA, Imran M, Kaliyadan F, Chopra R. Carcinoma erysipeloides as a presenting feature of breast carcinoma: A case report and brief review of literature. Ind Dermatol Online Jour 2015; 6: 396–8.

How to cite this article: Gupta A, Sharma S, Gupta M et al. Carcinoma erysipeloides: cutaneous metastasis mimicking benign disorder. Int J Health Sci Res. 2017; 7(2):353-357.
