

Case Report

Extensive Acanthosis Nigricans: A Clue to an Asymptomatic, Undiagnosed Malignancy

Dr. Ghanshyam Kumar Verma¹, Dr. Aditi Prasher², Dr. Ajay Kumar²,
Dr. Ranu Rattan³, Dr. Gita Ram Tegta⁴, Dr. Madan Kaushik⁵

¹Associate Professor Dermatology, Venereology & Leprosy,

²Ex Resident, ³Ex Sr. Resident, ⁴Professor Dermatology, Venereology & Leprosy,
Indira Gandhi Medical College, Shimla, HP

⁵Associate Professor, Department of Medicine, Indira Gandhi Medical College, Shimla, HP.

Corresponding Author: Dr. Ghanshyam Kumar Verma

Received: 11/01/2017

Revised: 23/01/2017

Accepted: 24/01/2017

ABSTRACT

Acanthosis Nigricans (AN) is a symmetrical, hyper pigmented velvety cutaneous thickening that can occur on any part of the body, but characteristically affects the axillae, nape and side of the neck, groin, antecubital and popliteal surfaces and umbilical area. Acanthosis nigricans is associated with both benign and malignant conditions. The majority (80%) are either idiopathic or associated with benign conditions such as obesity, insulin resistance, and congenital syndromes. Different tumors have been described with malignant acanthosis nigricans with adenocarcinoma being the commonest type, of which 70-90% is intra-abdominal out of which 55-61% are gastric adenocarcinomas. Malignant AN secondary to an internal malignancy is of sudden onset and rapidly progressive and pruritic, but is otherwise clinically indistinguishable from benign AN. We report a case of extensive acanthosis nigricans with an asymptomatic, undiagnosed adenocarcinoma stomach.

Key Words: Malignant Acanthosis Nigricans, Adenocarcinoma Stomach, Tripe Palm, Paraneoplastic.

INTRODUCTION

Acanthosis Nigricans (AN) is a symmetrical, hyper pigmented velvety cutaneous thickening that can occur on any part of the body, but characteristically affects the axillae, nape and side of the neck, groin, antecubital and popliteal surfaces and umbilical area. [1] It was first described by Pollitzer [2] and Janovsky [3] independently in 1890. It is classified into 4 types : (a) Malignant AN (Type I) - a cutaneous paraneoplastic syndrome associated with adenocarcinoma (b) Pseudo - AN (Type III) - associated with several syndromes in which obesity and endocrinopathies, especially the insulin resistant state coexist (c) True benign AN (Type II) - familial, present at birth or

beginning in childhood and (d) Drug induced AN (Type IV). [1]

Acanthosis nigricans is associated with both benign and malignant conditions. The majority (80%) are either idiopathic or associated with benign conditions such as obesity, insulin resistance, and congenital syndromes. [4]

CASE REPORT

We report a 55 year old female who presented to us with the chief complaint of increased thickness of skin over both palms from the past 3 months. This was followed by progressive brownish discoloration over the bilateral knuckles, axillae, infra mammary area, nape of neck, groin, perianal and perioral region. There was

history of loss of appetite and weight from the past 1 month. There was no history of epigastric pain, vomiting, altered bowel habits, lump abdomen or blood in stools. No history of cough, chest pain, shortness of breath or blood in urine.

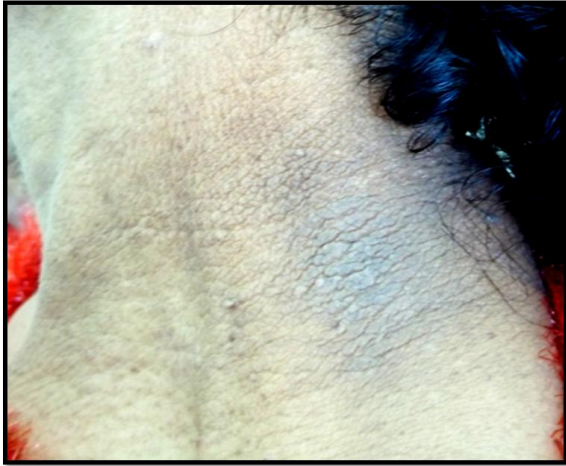

Figure 1.

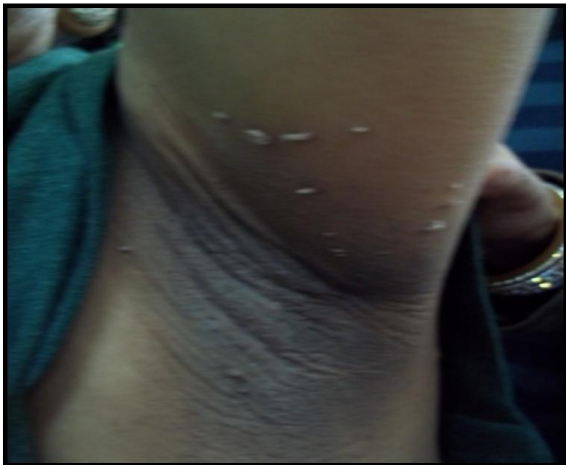

Figure 2.

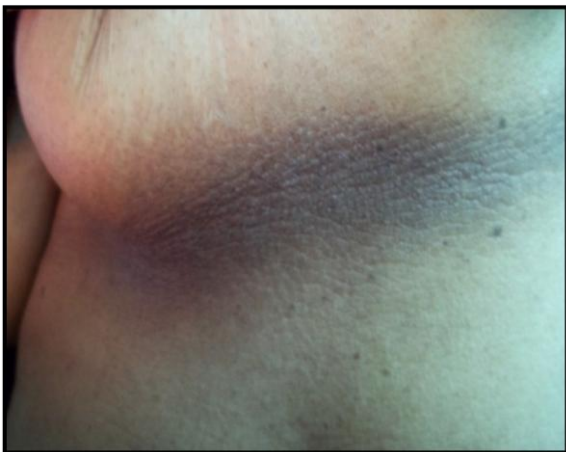

Figure3.

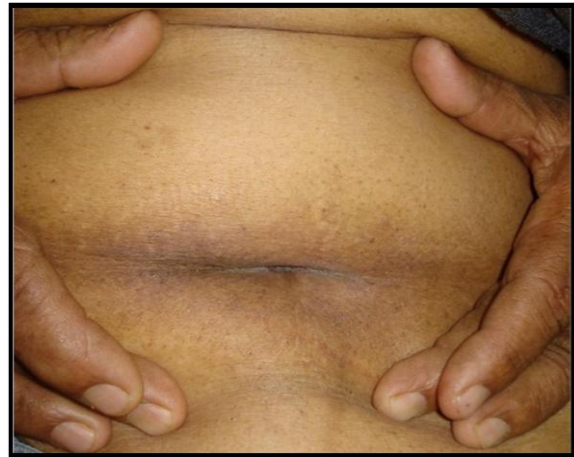

Figure 4.

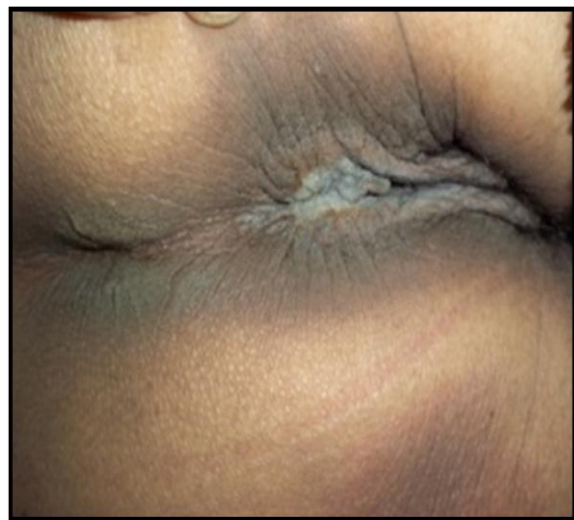

Figure5

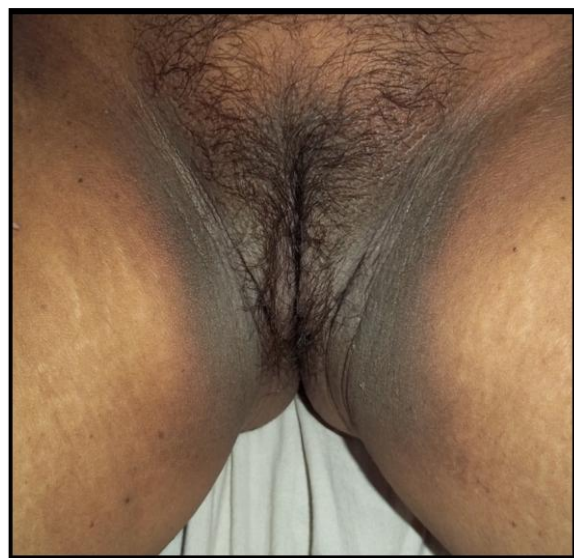


Figure6

Figure1,2,3,4,5 and figure 6 reveals marked acanthosis nigricans over body folds (neck, axilla , infra mammary region, abdominal crease, groin including perianal area with genital and anal mucosal involvement) .

On mucocutaneous examination palmar aspect of both hands showed evidence of tripe palms, there was hyperkeratosis of the palms and soles. Thickening of the skin with a dark brown pigmentation and a velvety texture was seen

over sides and nape of neck, bilateral axillae, infra mammary region, groin, perianal and perioral regions. Few papillomatosis lesions were found over axillary skin. Oral, ocular, genital and anal mucosa showed acanthotic changes.

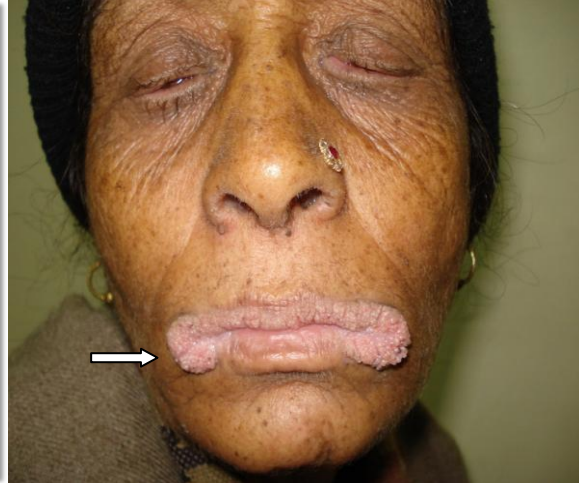
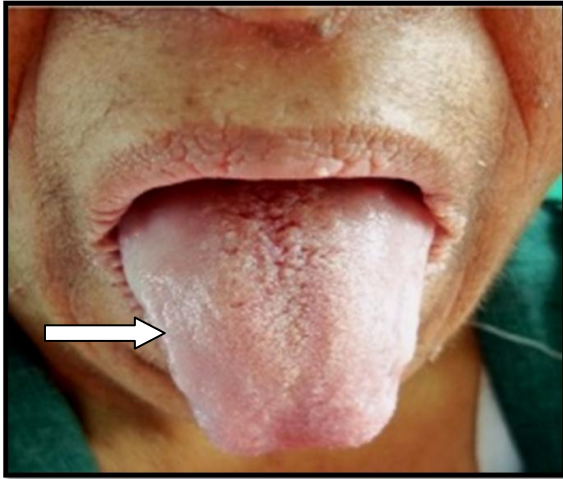
Figure 7 and figure 8 reveals mucosal involvement. (Tongue, labial mucosa and eye lid mucosa).

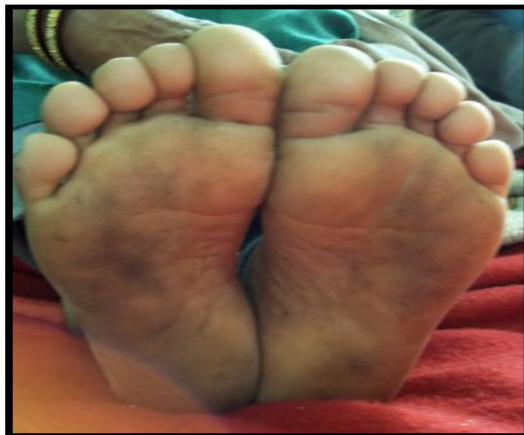
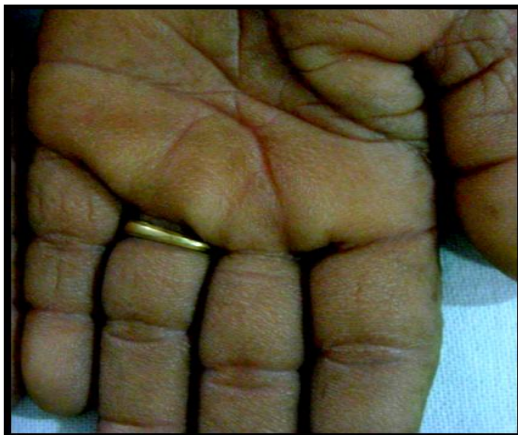
Figure 9,10. Tripe palm and hyperkeratosis of soles.

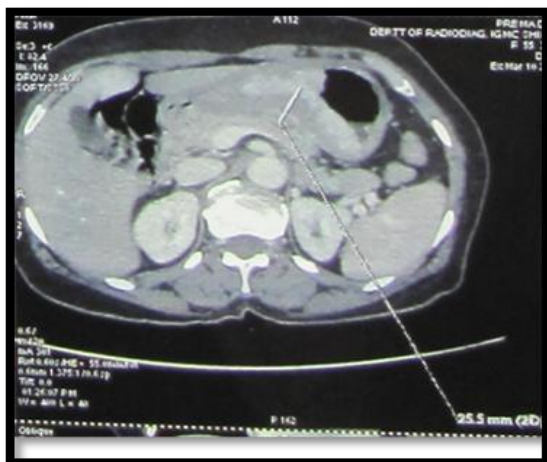

Figure 11. CT Scan revealed smooth homogenous thickening of the stomach wall along the lesser curvature, pyloric and antral region.

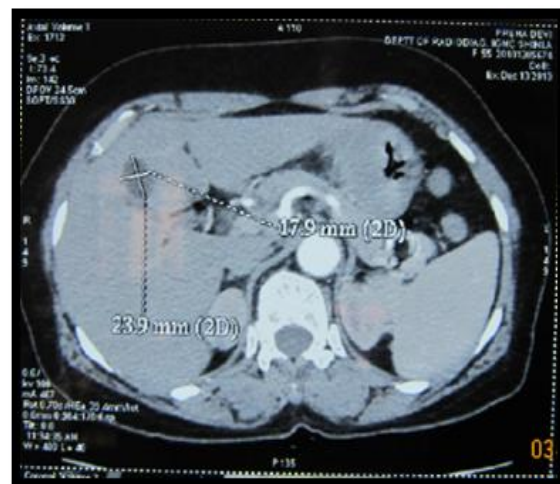


Figure 12. CT Scan revealed hypo dense lesion in segment IV of liver with abdominal lymphadenopathy.

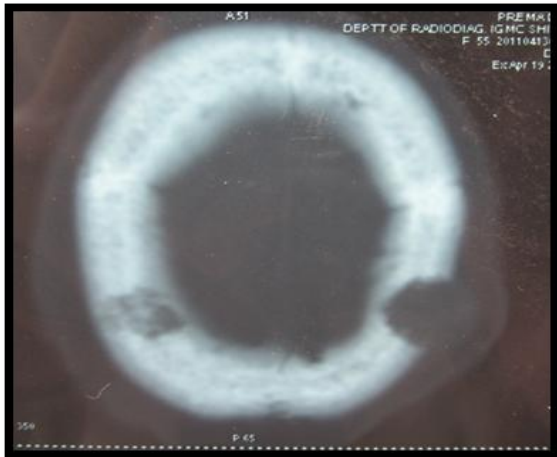


Figure 13. CT Scan revealed multiple lytic lesions in the skull with destruction of the left parietal bone along with invasion of underlying brain parenchyma and overlying soft tissue of scalp.

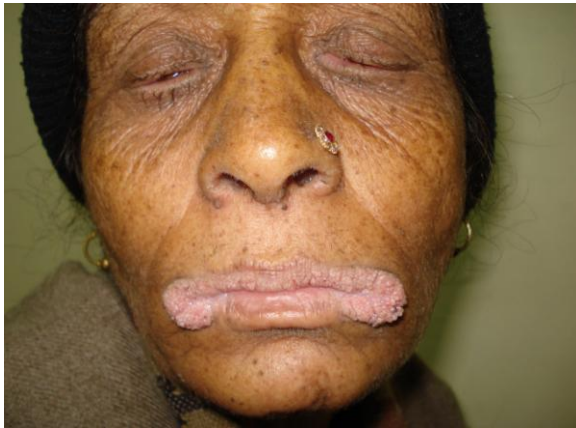

Figure 14. (a) Clinical picture at presentation.

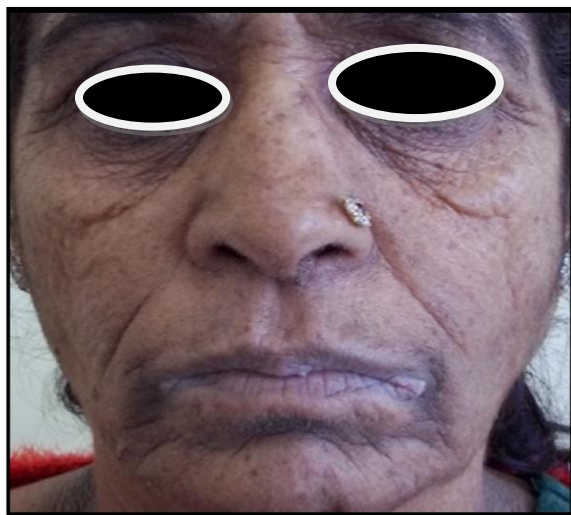

Figure 14. (b) Clinical picture after treatment (chemotherapy and surgery).

On investigation no evidence of diabetes, obesity, drug use such as nicotinic acid, estrogen, or corticosteroid common causes of benign acanthosis nigricans were

found. Keeping in view the above findings diagnostic possibility of malignant acanthosis nigricans was kept and the patient investigated accordingly. Her hemoglobin was 10.5 mg%. Rest of the hemogram and biochemistry profile was within normal range. Stool for occult blood was negative. Histopathology reveals a thickened stratum corneum with minimal involvement of the dermis except for thickened and elongated dermal projections (papillomatosis). Chest X-Ray revealed increased lung markings both sides. Ultrasound abdomen showed abdominal lymphadenopathy with fatty liver. CT abdomen showed smooth homogenous thickening of stomach wall along the lesser curvature, pyloric and antral region. There was hypodense lesion in segment IV of liver with abdominal lymphadenopathy. Gastrointestinal endoscopy revealed large polypoidal ulcer on the lesser curvature on proximal part of body of the stomach. Biopsy of the same confirmed it to be adenocarcinoma of the stomach. Final diagnosis was paraneoplastic acanthosis nigricans secondary to adenocarcinoma stomach with lymphatic and haematogenous metastasis (liver, brain). The patient was started on neoadjuvant chemotherapy that comprised of docetaxel (100 mg), cisplatin (50 mg) and 5-fluorouracil (1 g), four cycles at an interval of 21 days. Repeat C.T abdomen revealed asymmetric wall thickening at body and antrum of stomach with abdominal lymphadenopathy. The patient was planned for surgery and total gastrectomy was done.

DISCUSSION

More than 26 different tumors have been described with malignant acanthosis nigricans with adenocarcinoma being the commonest type, of which 70-90% are intra-abdominal out of which 55-61% are gastric adenocarcinomas. [4]

A plethora of other malignancies including lung, liver, uterus, breast, ovary, lymphomas and mycosis fungoides, [4] have been associated with malignant AN. Malignant AN secondary to an internal

malignancy is of sudden onset and rapidly progressive and pruritic, but is otherwise clinically indistinguishable from benign AN. It however often coexists with three other markers of internal malignancy: the sign of Leser Trelat, florid cutaneous papillomatosis and hyperkeratosis of the palms and soles. Warning flags that should trigger a careful evaluation for malignancy in patients presenting with acanthosis nigricans include unintentional weight loss and rapid onset of extensive AN. Mucosal involvement is more common in patients who have AN in association with a malignancy.^[4] Some malignancies may be associated with insulin receptor antibodies, as in one reported case of metastatic pheochromocytoma; however, no insulin resistance is described for most cases of paraneoplastic AN.^[5]

Malignancy-associated AN might be explained by elevated levels of growth factors such as transforming growth factor (TGF- α), which exerts effects on epidermal tissue via the epidermal growth factor receptor (EGFR).^[6] Decrease in urinary TGF- α and improvement of AN after resection of a melanoma have been noted.^[6] Malignant acanthosis nigricans accounts for 20% of all AN cases. It develops as a result of expression of the transforming growth factor alpha (TGF α) of tumor cells, melanocyte stimulating hormone α , and peptides causing cellular proliferation including insulin-like growth factor 1.^[7]

Malignant acanthosis nigricans is observed with a frequency of 70–92% of all abdominal neoplasms.^[8,9] Acanthosis nigricans can precede the malignancy by several months and hence the recognition of the condition may help in early detection and better chance of cure of the malignancy. Sharon J et al described a patient with malignant acanthosis nigricans diagnosed 2.5 years before the diagnosis of endometrioid adenocarcinoma of the parametrium, which was discovered only after an extensive search for malignancy.^[10]

In the present case patient was asymptomatic as far as stomach malignancy

was concerned. Instead she was worried about thickened and pigmented cutaneous changes; on further investigations her asymptomatic malignancy was diagnosed. She passed away due to the fatal adenocarcinoma stomach after 11 months of diagnosis.

CONCLUSION

Acanthosis nigricans rarely occurs as a paraneoplastic disorder. Abdominal adenocarcinomas, particularly gastric, is the major cause of AN-associated tumors. AN can be an early clue to an asymptomatic malignant disease. Timely diagnosis of the underlying disease can alter the course of the disease. Thus, if a patient comes with a sudden onset of severe AN, we must carefully investigate the patient to determine any underlying malignancy.

REFERENCES

1. Curth HO. Classification of acanthosis nigricans. *Int J Dermatol* 1976; 15(8): 592-593.
2. Pollitzer S. Acanthosis nigricans. In: Unna PG, editor. *International atlas of rare skin diseases. Part 4.* London: HK Lewis and Co; 1890. p. 6.
3. Janovsky V. Acanthosis nigricans. In: Unna PG, editor. *International atlas of rare skin diseases. Part 1.* London: HK Lewis and Co; 1890. p. 1.
4. Schwartz RA. Acanthosis nigricans. *J Am Acad Dermatol* 1994; 31:1-19.
5. Matsuoka LY, Goldman J, Wortsman J, Kleinsmith D, Kupchella CE. Antibodies against the insulin receptor in paraneoplastic acanthosis nigricans. *Am J Med* 1987; 82:1253-6.
6. Ellis DL, Kafka SP, Chow JC, Nanney LB, Inman WH, Mc Cadden ME, et al. Melanoma, growth factors, acanthosis nigricans, the sign of Leser-Trelat, and multiple acrochordons. A possible role for alpha-transforming growth factor in cutaneous paraneoplastic syndromes. *New Engl J Med* 1987; 317:1582-1587.
7. Krawczyk M, Mykała-Cieśla J, Kołodziej-Jaskuła A. "Acanthosis nigricans as a paraneoplastic syndrome: case reports and review of literature." *Polskie Archiwum Medycyny*

- Wewnetrznej 2009; 119(3): 180–183.
8. Yeh JSM, Munn SE, Plunkett TA, Harper PG, Hopster DJ and Du Vivier AW. “Coexistence of acanthosis nigricans and the sign of Leser-trelat in a patient with gastric adenocarcinoma: a case report and literature review.” *J Am Acad Dermatol* 2000; 42(2): 357–362.
 9. Sabir S, James WD and Schuchter L M. “Cutaneous manifestations of cancer”.
10. Longshore S J, Taylor J S, Kennedy A, and Nurko S. Malignant acanthosis nigricans and endometrioid adenocarcinoma of the parametrium: The search for malignancy. *J Am Acad Dermatol* 2003; 49:541-543.

How to cite this article: Verma GK, Prasher A, Kumar A et al. Extensive acanthosis nigricans: a clue to an asymptomatic, undiagnosed malignancy. *Int J Health Sci Res.* 2017; 7(2):342-347.
