

Case Report

Varied Clinical Presentations of Meckel's Diverticulum

Venita Kapur¹, Shreedevi K.N², Bhupinder Singh Walia³

¹Professor, ²Resident, ³Assistant Professor,
Department of Surgery, Guru Nanak Dev Hospital/ Government Medical College, Amritsar.

Corresponding Author: Shreedevi K.N

Received: 15/12/2016

Revised: 02/01/2017

Accepted: 07/01/2017

ABSTRACT

Meckel's diverticulum is a common congenital anomaly of the gastrointestinal tract. They are largely asymptomatic; complications are rare and include diverticulitis, bleeding and obstruction. This is a report on three cases; two cases of gangrenous Meckel's diverticulum in male patients aged nine and thirty-five, presenting to the emergency with features suggestive of acute appendicitis, and one case of incidental finding of Meckel's diverticulum in a twenty-two year old female undergoing routine elective LSCS (lower segment Caesarian section). Diverticulectomy was performed in both male patients; whereas the diverticulum in the female patient was left in-situ as there were no signs of bleeding, inflammation, or obstruction.

Keywords: Meckel's diverticulum, appendicitis, diverticulectomy

INTRODUCTION

Meckel's diverticulum is present in 2% of the population; it is situated on the anti-mesenteric border of the small intestine, commonly 60 cm from the ileocaecal valve, and is usually 3–5 cm long. 3:2 male-to-female prevalence ratio has been reported. [1] Meckel's diverticula are designated true diverticula because their walls contain all of the layers found in normal small intestine. Their location varies among individual patients, but they are usually found in the ileum within 100 cm of the ileocaecal valve. It represents the patent intestinal end of the vitellointestinal duct. An aphorism attributed to Dr Charles Mayo is: 'a Meckel's diverticulum is frequently suspected, often sought and seldom found'. Meckel's diverticula are asymptomatic unless associated complications arise. The lifetime incidence rate of complications arising in patients with Meckel's diverticula

has been estimated to be approximately 4 to 6%. [1] The complications caused by Meckel's diverticulum include acute hemorrhage, intussusception, and intestinal obstruction in adults. Diverticulitis, present in 20% of patients with symptomatic Meckel's diverticula, is associated with a clinical syndrome that is indistinguishable from acute appendicitis. [1]

MATERIALS AND METHODS

A nine year old boy presented to the emergency with acute pain abdomen and vomiting since one day; ultrasonographic imaging demonstrated resolving acute appendicitis. Patient was taken up for emergency open appendicectomy. On exploration, a normal appendix was found, and a gangrenous Meckel's diverticulum present about 60 centimeters proximal to the ileocaecal junction. A diverticulectomy was

performed followed by primary closure of ileum and abdomen closed over a drain.

Two weeks later, a thirty-five year old man presented with acute pain abdomen since one day, more around the umbilical region, with ultrasonographic imaging showing a fluid filled tubular structure present in right iliac fossa and lumbar region suggestive of acute appendicitis. Patient was taken up for emergency open appendicectomy. A normal appendix was found, and on further exploration a tubular (2X10 cms) gangrenous Meckel's diverticulum was found approximately 60 centimeters proximal to ileocaecal junction. Meckel's diverticulectomy was done followed by primary closure of ileum.

A twenty-two year old female, primigravida, undergoing a routine LSCS (lower segment Caesarian section), with incidental finding of Meckel's diverticulum seen at 50 centimeters proximal to ileocaecal junction. No surgical intervention was done at the time as the diverticulum was wide mouthed and showed no signs of disease or inflammation.

RESULT

Post-operative period was uneventful for both patients. On follow up after three months, patients remained symptom free. Female patient was followed up post-operatively for six months and remained asymptomatic.

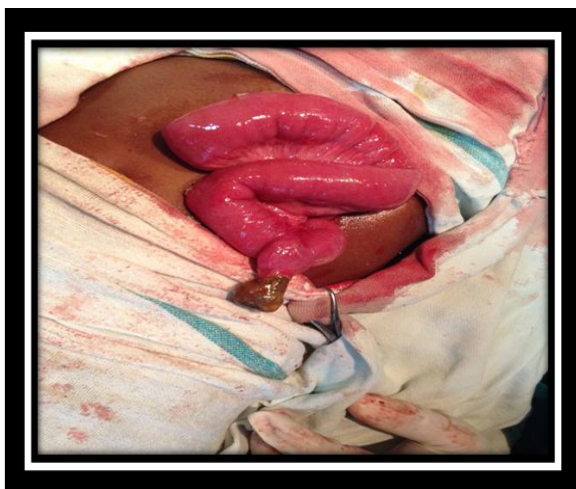

Figure 1: Meckel's diverticulum in a nine year old boy.

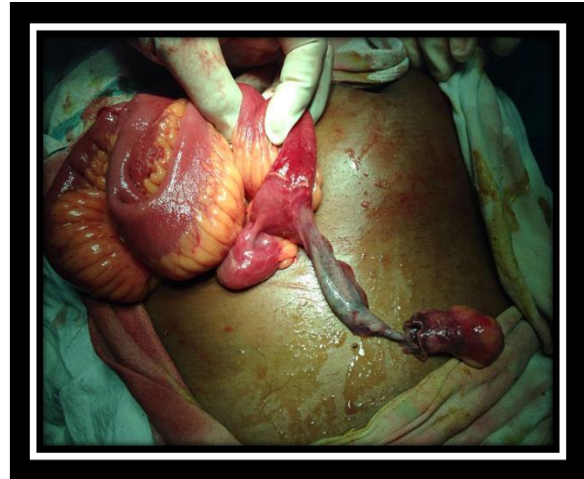


Figure 2: Gangrenous Meckel's diverticulum in a thirty-five year old man.

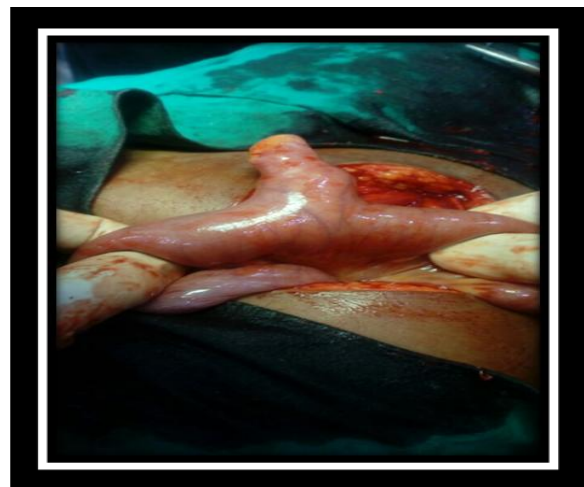

Figure 3: Incidental finding of Meckel's diverticulum in a twenty-two year old woman.

DISCUSSION

Meckel's diverticulum was first described in a paper published in 1809 by the German anatomist, Johann Friedrich Meckel, the younger (1781–1833), who described it as a remnant of the omphalo-mesenteric duct, although such an abnormality had been mentioned quite early by Fabricius Hildanus in 1598 and in 1671 by Lavater (who did not recognize its embryological origin).^[2] Meckel's diverticulum is lined mainly by the typical ileal mucosa as in the adjacent small bowel. However, ectopic gastric, duodenal, colonic, pancreatic, Brunner's glands, hepatobiliary tissue and endometrial mucosa may be found, usually near the tip.^[3] Meckel's diverticulum occurs in 2% of patients, is usually 2 inches (5 cm) in length and is situated 2 feet (60 cm) from the ileocaecal

valve. In children, it may be impossible to clinically distinguish Meckel's diverticulitis from acute appendicitis. The pain is similar; however, signs may be central or left sided. Occasionally, there is a history of antecedent abdominal pain or intermittent lower gastrointestinal bleeding. It should be sought when a normal appendix is found at surgery for suspected appendicitis. Bleeding from Meckel's diverticulum can cause iron deficiency anaemia. [4] If a silent Meckel's is found incidentally during the course of an operation, it can be left alone provided it is wide mouthed and not thickened. [5] When a diverticulum perforates, the symptoms may simulate those of a perforated duodenal ulcer. At operation, an inflamed diverticulum should be sought as soon as it has been demonstrated that the appendix and fallopian tubes are not at fault. Rare complications include inversion of Meckel's diverticulum, torsion, volvulus of ileum around Meckel's diverticulum or fibrous cord and perforation-spontaneously or by foreign body such as fish bone. [6-9] A total of 722 surgical cases of Meckel's diverticulum were encountered at the Mayo Clinic from 1906 through 1960. In 560 cases it was an incidental finding in the course of other surgical procedures, while in 162 cases the diverticulum was the specific cause for surgical intervention. For this reason, Meckel's diverticulum must be considered as a possible cause of any intra-abdominal condition which cannot be readily diagnosed. [10] The treatment of choice for the symptomatic Meckel's diverticulum is surgical resection. This can be achieved either by the diverticulectomy or by the segmental bowel resection and anastomosis.

CONCLUSION

The diagnosis of Meckel's diverticulitis was ultimately made by exploratory laparotomy. A Meckel's diverticulum usually remains symptomless throughout life and is found only at necropsy. These cases demonstrated that a high degree of clinical suspicion is required for the diagnosis of Meckel's diverticulum. Exploration of the abdomen has a pivotal role in the diagnosis and treatment of Meckel's diverticulum.

REFERENCES

1. Hunt KK, Newman LA, Copeland EM, Bland KI. The Breast. Shwartz Principles of surgery. 9th ed. McGraw Hill International Book Company; 2009. p1937-9
2. Meckel JF. Uber die divertikel am darmkanal. Arch Physiol 1809; 9:421-53
3. Stone PA, Hofeldt MJ, Lohan JA, Kessel JW, Flaherty SK. A rare case of massive gastrointestinal hemorrhage caused by Meckel's diverticulum in a 53-year-old man. W V Med J2005;101:64-6504
4. Al Onaizi I, Al Awadi F, Al Dawood AL. Iron deficiency anaemia: an unusual complication of Meckel's diverticulum. Med PrincPract 2002; 11:214-17
5. Norman SW, Christopher JKB, P. Ronan O'Connell. Bailey and Love's short practice of surgery ;25th edition;1158-59
6. Heinicke JM, Tedaldi R, Muller C. An unusual manifestation of Meckel's diverticulum: bleeding and perforation—a case report. Swiss Surg 1997;3:97-9
7. Wong JH, Suhaili DN, Kok KY. Fish bone perforation of Meckel's diverticulum: a rare event? Asian J Surg 2005;28:295-6
8. Tan YM, Zheng ZX. Recurrent torsion of a giant Meckel's diverticulum. Dig Dis Sci 2005;50:1285-7
9. Puligandla PS, Becker L, Driman D, Prokopiw I, Taves D, Davies ET. Inverted Meckel's diverticulum presenting as chronic anemia: case report and literature review. Can J Surg 2001;44:458-9
10. Weinstein EC, Cain JC and Remine WH. Meckel's diverticulum: 55 year of clinical and surgical experience. JAMA 1962; 182:251.

How to cite this article: Kapur V, Shreedevi KN, Walia BS. Varied clinical presentations of meckel's diverticulum. Int J Health Sci Res. 2017; 7(2):331-333.
