

Case Report

Maxillary Sinus Lift, PRF and Simultaneous Implant Placement

Seema Sajood Mufti¹, Achyut Sinha², Tanu Mahajan³, Ravi Shankar Yadav⁴

¹Consultant Prosthodontist at Family Health Dental Centre Srinagar

²P.G Scholar Dept. of Prosthodontics Rama Dental College, Kanpur, Uttar Pradesh,

³Professor Dept. of Prosthodontics Rama Dental College Kanpur, Uttar Pradesh,

⁴Consultant Prosthodontist at Clove Dental Centre New Delhi.

Corresponding Author: Seema Sajood Mufti

Received: 26/12/2016

Revised: 23/01/2017

Accepted: 30/01/2017

ABSTRACT

Implant dentistry has emerged as an excellent treatment modality ever since its ingress into the field of modern dentistry. However, the first and the foremost requirement for the placement of an implant is the presence of an adequate alveolar bone. By adequate bone, is meant that both the quality and the quantity of the bone have to be sufficient for implant placement. Posterior maxilla often presents with insufficiently available bone for the placement of implants due to the presence of antrum of maxillary sinus most commonly known as the maxillary sinus. This jeopardises the successful implementation of implant dentistry in such situations. The present article is aimed at throwing some light on how to deal with the problem of resorbed ridges and a pneumatized sinus through the process of sinus lift and PRF placement in order to facilitate implant placement.

Key words: Sinus lift, PRF, implant placement.

INTRODUCTION

An adequate quality and quantity of bone is essential for successful implant placement. Posterior maxilla presents several challenges to an implantologist that is unique to this region. ^[1]

Most important of these is the presence of a maxillary sinus.

Lining mucosa of the maxillary sinus is the Schneiderian membrane.

The structures that lie beneath the sinus are the alveolar bone and the posterior teeth.

As the edentulous span continues to atrophy, there is continuous loss of bone height and density and pneumatization of sinus.

When implant is inserted in this area, the initial implant stability is poor coupled with inadequate bone height for the implant

length. This results in implant failure either initially or during loading.

The procedure of choice to restore this anatomic deficiency is the maxillary sinus lift.

SINUS LIFT

Sinus Lift is a procedure in which the maxillary sinus membrane is elevated and subantral augmentation is performed with bone graft placement. ^[2] The end result being an improved bone height in the posterior maxilla which is more favourable for implant placement.

Two approaches:

1. The direct approach
2. The indirect approach

SURGICAL TECHNIQUES

Carl Misch subcategorized the implant treatment planning into four approaches based on bone height in the posterior area:

SUBANTRAL OPTION 1 (SA1)

Conventional implant placement:

There is sufficient available bone height, usually greater than 12mm to permit the placement of an endosteal implant.

No sinus lift is required in this category as implant can be placed normally. Bone graft may be used only to augment the bone width.

SUBANTRAL OPTION 2 (SA2)

This technique was developed by Tatum in mid 1970s.

Sinus lift and simultaneous implant placement with osteotome lift technique:

Selected when there is 10-12mm of available bone height. Thus the available bone is only 0 -2 mm insufficient of the ideal implant length which according to numerous studies (Hurztler et al) is 13mm or more.

Osteotome lift technique is used where the implant is tapped to produce a green stick fracture on the sinus floor. Bone graft can be added.

SUBANTRAL OPTION 3 (SA3)

Sinus membrane elevation with subantral augmentation and delayed implant placement.

Advised when atleast 5mm bone height of sufficient width is present.

A Tatum lateral wall approach is performed just superior to the residual alveolar bone.

A Green stick fracture is introduced in the access window as it is rotating inward and upward and serves as the floor of the implant.

A mixture of autogenous bone and/or allograft material is placed.

Implant is then placed from the top of the ridge.

SUBANTRAL OPTION 4 (SA4)

Sinus membrane elevation and subantral augmentation with extended delay of implant placement:

There is 5mm or less of bone height and thus there is not enough surface area for anchorage and stabilization of the implant.

In this case, Tatum lateral wall approach is performed.

A mixture of autogenous bone and/or allograft material is placed.

Implant will be placed at 8 to 12 months later as the new bone is allowed to migrate, differentiate, and mature.

PRP & PRF

Reconstructive dental surgeons are constantly looking for an edge that will jump starts the healing process to maximize predictability as well as the volume of regenerated bone. [3]

PRP (PLATELET RICH PLASMA)

Several studies have shown that bone regenerative procedures may be enhanced by the addition of specific growth factors.

Platelet-rich plasma (PRP) was proposed as a method of introducing concentrated growth factors PDGF, TGF- β , and IGF-1 to the surgical site, enriching the natural blood clot in order to expedite wound healing and stimulate bone regeneration. A natural human blood clot contains 95% red blood cells (RBCs), 5% platelets, less than 1% white blood cells (WBCs), and numerous amounts of fibrin strands.

A PRP blood clot, on the other hand, contains 4% RBCs, 95% platelets, and 1% WBCs.

PRF (PLATELET RICH FIBRIN)

PRF is a matrix of autologous fibrin, in which are embedded a large quantity of platelet and leukocyte cytokines during centrifugation.

Platelet-rich fibrin (PRF) was first developed in France by Choukroun et al in 2001. [4] It represents a new step in the platelet gel therapeutic concept with simplified processing, minus artificial biochemical modification.

Unlike other platelet concentrates, this technique requires neither anticoagulants nor bovine thrombin (nor any other gelifying agent), making it no more than centrifuged natural blood without additives.

This second generation platelet concentrate is widely used to accelerate soft and hard tissue healing.

PRF is in the form of a platelet gel and can be used in conjunction with a bone graft which offers several advantages like:

PREPARATION OF PRF

PRF preparation requires an adequate amount of whole blood, a table centrifuge, a collection kit including a 24 gauge butterfly needle and a 10ml blood collection tube.

The required quantity of blood is drawn into 10 ml test tubes without an anti coagulant and centrifuged immediately.

Blood is centrifuged for 12mins at 2700 rpm.

Because of the absence of anticoagulant, blood begins to coagulate as soon as it comes in contact with the glass surface.

Therefore for successful preparation of PRF, a speedy blood collection and immediate centrifugation, before the clotting cascade is initiated is absolutely essential.

The resultant product consists of following three layers:

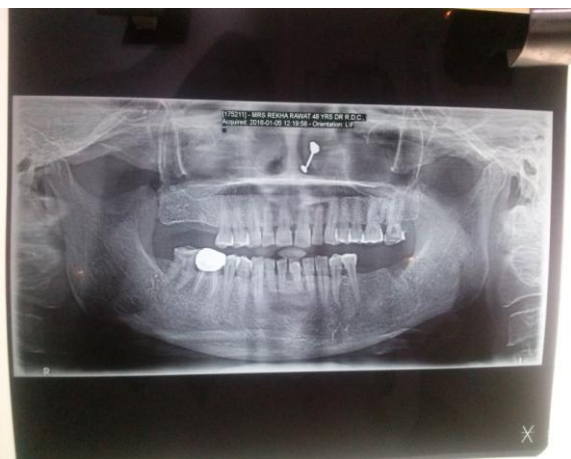
Topmost layer consisting of acellular PPP

PRF clot in middle

RBC's at bottom.

CASE REPORT

A 48 year old female patient reported, to the department of Prosthodontics, Rama Dental College, with the chief complaint of difficulty in chewing on the right side due to missing teeth in the right upper back tooth region.



(Fig. 1) Radiographic examination showing the implant site

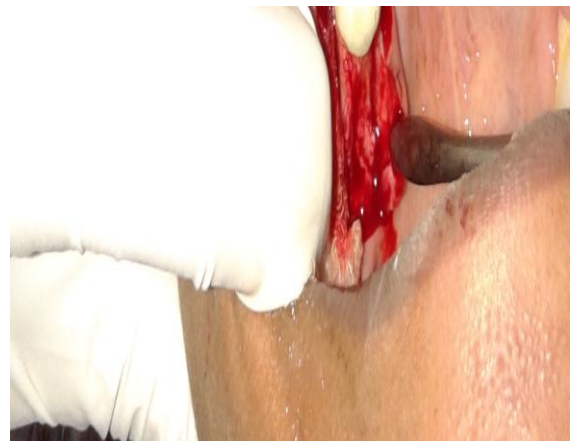On oral examination it was found that the right maxillary first and second molars were missing.

On radiographic examination (Fig.1) the available bone height in this molar region (16 region) was found to be approximately 10mm from the maxillary sinus lining.

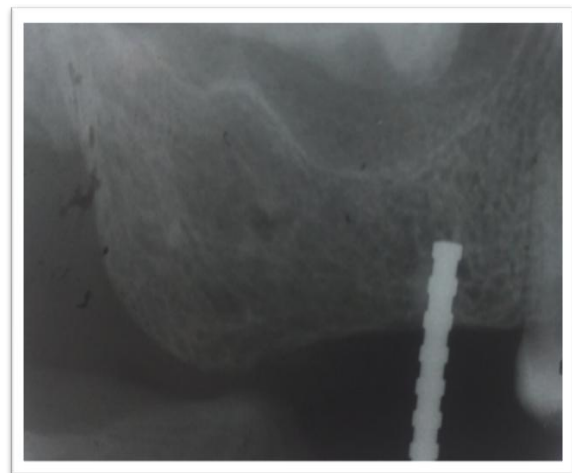
After a thorough oral and radiographic examination, two stage surgeries was planned.

It was decided to lift the sinus lining with an indirect approach through alveolar crest and simultaneous implant placement.

An endosteal implant of 10mm length and 5mm diameter was selected. After performing the incision and raising a full thickness flap, (Fig. 2) the indirect approach begins with a pilot drill to mark the implant site.



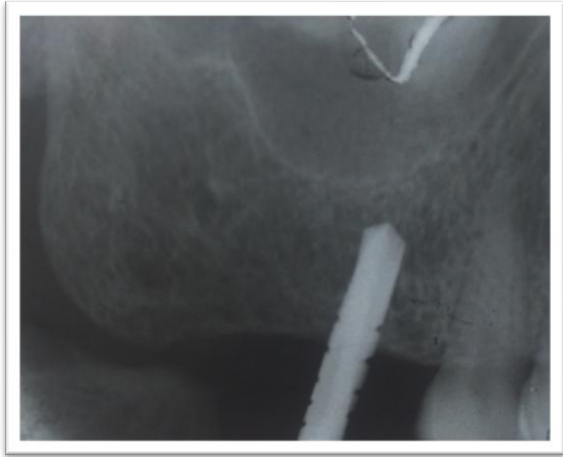
(Fig.2) Incision and full thickness flap



(Fig. 3) Radiograph showing paralleling pin at implant site.

First the site was prepared upto 5mm. A paralleling pin was placed and an IOPA

radiograph taken (Fig.3). Since there was still ample amount of bone, the preparation was extended further upto 8 mm with the twist drill

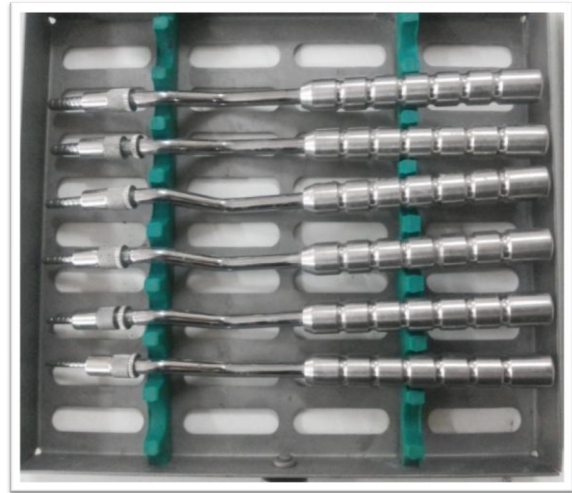

(Fig .4) Radiograph showing remaining space of 1 to 2 mm between osteotomy and maxillary sinus floor.

Now after drilling 8mm the bone remaining between the osteotomy and the sinus floor was about 1 to 2 mm. (Fig. 4)

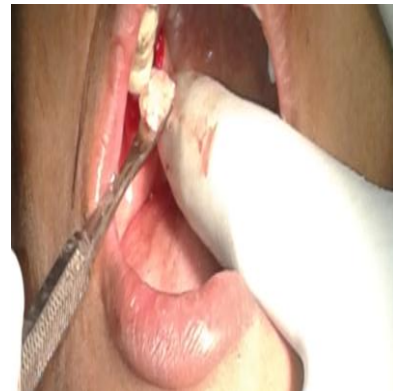Further drilling for 2 to 3 mm for placing the implant slightly subcrestal would have resulted in perforation of the sinus floor. So

it was decided to achieve the remaining height with the help of osteotomes. (Fig.5)

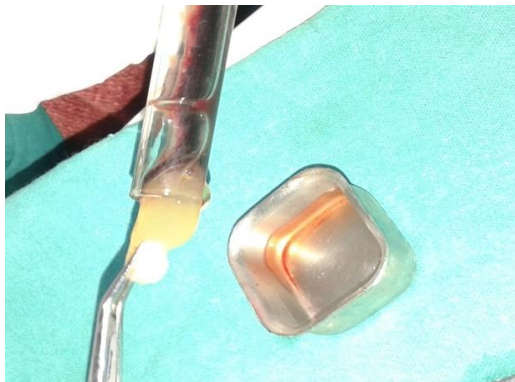


(Fig. 5) Osteotomes used to lift the sinus floor

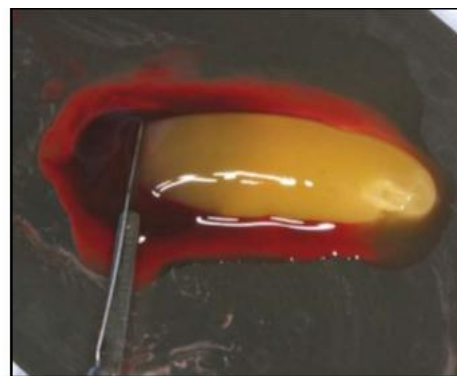
Before using the osteotome a small amount of alloplastic bone graft material (Fig. 6) was placed into the implant site. This material also acts as a shock absorber when tapping of osteotome is done with the mallet.



(Fig. 6) Alloplastic graft material placed at the implant site.

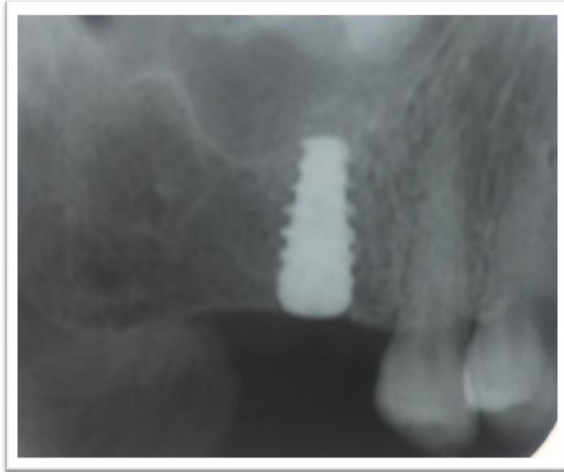


(Fig. 7) PRF being pulled out of the test tube



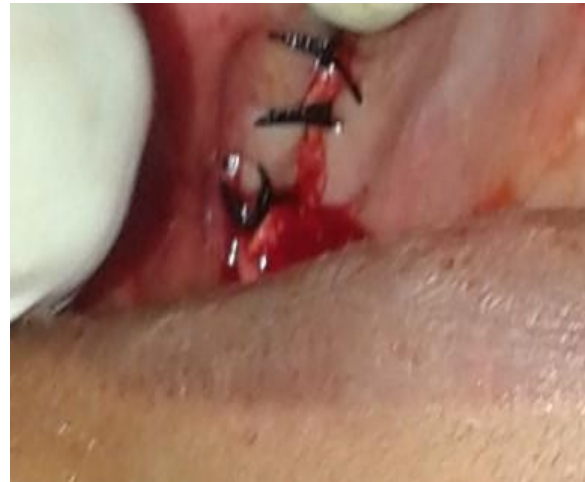(Fig. 8) Remaining RBC's being scrapped off from the PRF

Once the required bone height of 10 mm was obtained by osteotomes, the PRF was pulled out of the test tube (Fig.7), the remaining RBC's were scrapped off (Fig. 8) and the PRF was placed at the prepared osteotomy site.



(Fig. 9) Radiograph showing endosteal implant secured at the implant site

Next the endosteal implant was gently placed in the prepared site.(Fig. 9) This further pushed and secured the PRF upwards.



(Fig. 10) Implant site covered with flap and secured with sutures.

The primary stability of the implant was checked, cover screws placed, implants were covered with mucosa and sutures were placed. (Fig. 10)

DISCUSSION

It has been observed that many surgical techniques exist that can help to overcome the expected anatomical difficulties encountered during implantation. However, it is important to remember the desired treatment outcome and to explore all the possible solutions.

A good evaluation of both the patient's desires and the available possibilities and by choosing a suitable technique, keeping the technique as simple and as predictable as possible, the likelihood of success increases greatly even in compromised situations.

REFERENCES

1. Garg A. Augmentation grafting of the maxillary sinus for the placement of dental implants: Anatomy, physiology and procedure. *Implant Dent* 1999;8 (1): 36-6.
2. Small SA, Zinner ID, Panno FV et al. Augmentation of the maxillary sinus for implants:- Report of 27 patients. *Int J Oral Maxillofac Implants* 1993;8 (1): 523-8.
3. Long term effects of vertical bone augmentation: a systemic review. *J Appl Oral Sci* 2016; 24 (1): 3-17.
4. Toffler M, Toscano N, Holtzclaw D, Corso MD, Ehrenfest DD. Introducing Choukron's Platelet Rich Fibrin(PRF)to Reconstructive Surgery Milieu. *Journal of implant and advanced clinical dentistry* 2009; 1(6): 21-30.

How to cite this article: Mufti SS, Sinha A, Mahajan T et al. Maxillary sinus lift, PRF and simultaneous implant placement. *Int J Health Sci Res.* 2017; 7(2):322-326.
