

# Pulmonary Hydatidosis, Clinical Facts, Radiologic Features and Mitigation of Parasitosis

Dr Ajaz Nabi Koul<sup>1</sup>, Dr Abdul Wahid Bhat<sup>2</sup>, Dr Ridwana Ahad<sup>3</sup>

<sup>1</sup>Associate Professor of Medicine & Infectious Diseases, SKIMS, Kashmir

<sup>2</sup>Associate Professor of Emergency Medicine, SKIMS, Kashmir

<sup>3</sup>RMO, SKIMS, Kashmir

Corresponding Author: Dr Ajaz Nabi Koul

Received: 02/12/2016

Revised: 31/12/2016

Accepted: 03/01/2017

## ABSTRACT

Pulmonary hydatid disease continues to haunt clinicians for diagnosis as well as management. We conducted present study in Infectious Diseases Department of Sher-i-Kashmir Institute of Medical Sciences, Kashmir for three years. We diagnosed 22 cases of pulmonary hydatid disease by clinical presentation, serology and CT chest. 92% had solitary pulmonary cyst, 3% had bilateral lung cysts and 5% had multiple organ involvement. CT scan was appropriate modality of diagnosis and surgery was the effective line of management. Patients were followed for varying intervals for recurrences which were documented in none.

**Key words:** pulmonary, Hydatid disease

## INTRODUCTION

Hydatid disease is caused by infection with the metacestode stage of the tapeworm *Echinococcus*, family Taeniidae. *Echinococcus* produce infection in humans in form of cystic disease of various organs of body commonly liver followed by lungs but can virtually involve any organ of the body. *E. granulosus* and *E. multilocularis* are the commonest species causing hydatidosis. The two other species, *E. vogeli* and *E. oligarthrus* rarely cause the disease and *Echinococcus orteppi*, *Echinococcus equines*, and *E. shiquicus* are not known to cause human parasitosis.

## MATERIALS AND METHODS

The study was conducted in infectious disease unit of internal medicine, were suspected cases of Hydatid disease were subjected to CT scan of chest. The patients were evaluated and were operated

by CVTS department. They were followed for any recurrence or complication in our department.

## OBSERVATION AND RESULTS

22 patients presented to our department, who fulfilled the criteria inclusive for pulmonary hydatidosis. Chief complaint of these patients were cough (82%), fever (14%), chest discomfort (8%), blood tinged sputum (8%). Around (14%) patients were asymptomatic and were evaluated with chest xray for other reasons. Such patients were diagnosed as pulmonary Hydatid disease on work up for lung lesion. Clinical examination was unremarkable while CxR revealed homogenous opacity in 72% cases, air fluid level in 5% cases, pleural effusion in 2%, in homogenous opacity in 10% cases and consolidated lung in 10% cases. CBC was normal while eosinophilia was documented in 4% cases

(mean AEC 160). ESR was raised in 40% cases (mean ESR 38 mm). KFT, LFT, uric acid, LDH were within normal range. USG chest was done in all patients which revealed cystic swelling in chest in 48% cases, consolidated lung in 3% cases, pleural effusion with internal septations in 3% cases and inconclusive in rest of cases. USG abdomen was done in all cases which revealed cystic lesions of liver in 5% cases commensurate with hepatic hydatidosis having concomitant lung hydatid disease.

Hydatid serology was done in all patients and was positive in 40% of cases and sputum for Hydatid membranes or scolices was detected in none. Casoni intradermal test was positive in 30% cases.

CT chest was done in all cases with upper abdominal cuts where ever applicable to rule out liver involvement. Total of 26 cysts were imaged in 22 patients. The size of cysts varied from 1.5 cms to 13 cms. HU density varied from 2 HU to 130 HU depending on adjacent pericystic infection. (fig1). The commonest site of location was right lower lobe. The cyst wall was smooth in most of cases and thickness varied from 2mm to 12 mm.(fig2) 3 cysts were near pleura with concomitant pleural effusion.. 3 cysts had bronchial rupture. It was demonstrated on bronchoscopy which revealed glistening white membranes pouching out of left upper lobe bronchus. All the three ruptured cysts were located in left upper lobe. BAL of these 3 cysts showed evidence of hooklets. Crescent sign was seen in 3 patients, water lily sign was seen in 2 patients. Cachexia was seen in 1 patient who had multiple organ involvement and lung Hydatid was complicated by rupture into pleural cavity.(fig3,4 5,6). The patient needed chest tube placement which drained murky fluid which was positive for scolices.

All the patients were put on tab albendazole 400 mgm bd for 2 weeks along with praziquantal 600 mgm daily for 2 weeks before subjecting them to surgery.

All the patients except one patient were operated successfully with no

mortality. The surgery was done by CTVS surgeon and general surgeon was involved in 3 cases with concomitant liver Hydatid. One patient who had multiple Hydatid cysts of lung, liver, peritoneum, spleen etc was not operated considering his clinical status. He is on follow up with chemotherapy. (fig7)

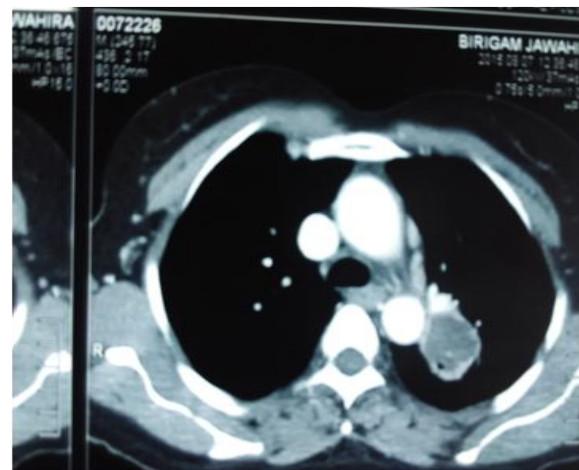


Fig 1

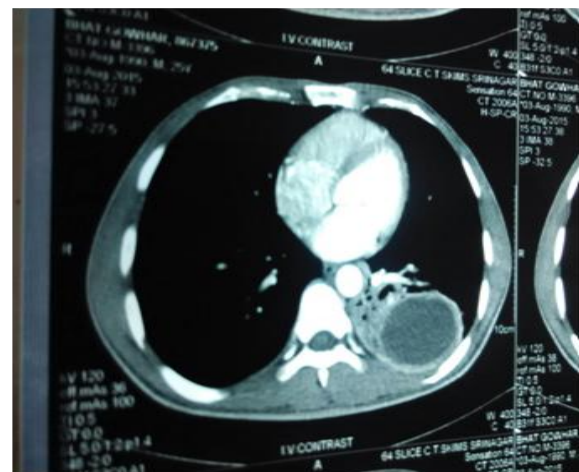


Fig 2

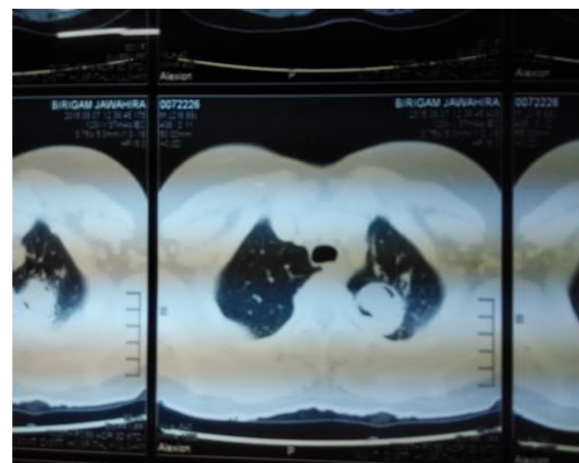


Fig 3

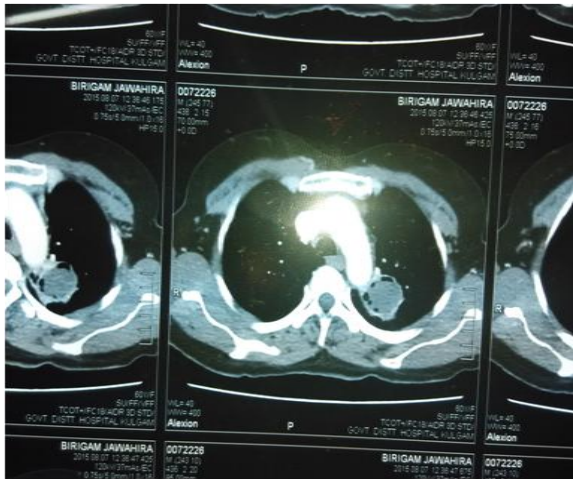


Fig 4

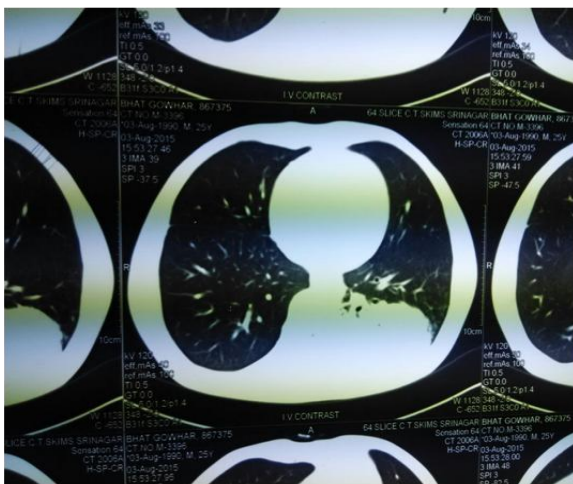


Fig 5

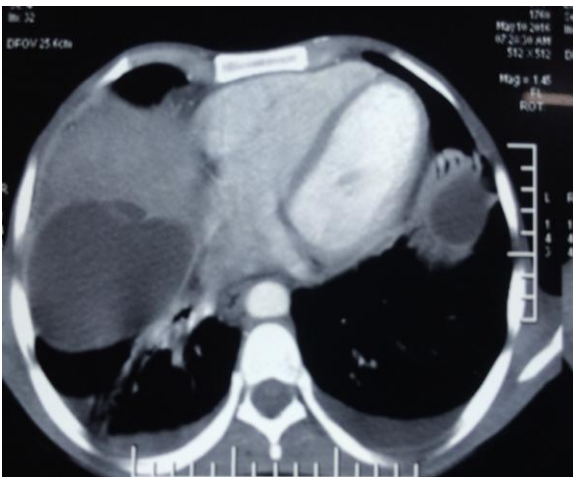


Fig 6

## DISCUSSION

Hydatid disease is caused by infection with the metacestode stage of the tapeworm *Echinococcus*, which belongs to the family Taeniidae. *Echinococcus granulosus* and *Echinococcus multilocularis* are the most common causing hydatidosis.

The two other species, *E. vogeli* and *E. oligarthrus* rarely cause human infection.

Hydatid disease usually is innocuous and about 50% remain undiagnosed till late but pulmonary Hydatid disease is relatively picked early due to higher chances of rupture with mechanics of respiration. In lung Hydatid usually there is no pericystic reaction, no calcification making cyst wall amenable to rupture. In addition in lungs probability of superadded infection and development of consolidation is more. All these factors make pulmonary Hydatid to be diagnosed earlier as compared to Hydatid liver or any other site. (1)

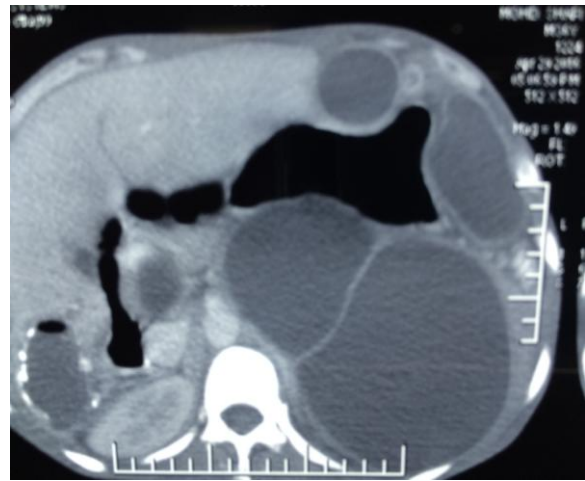


Fig 7

Still in our series 14% were routinely diagnosed and were asymptomatic. Rest of the patients had cough as predominant symptom consistent with other series. The right lung was commonly involved in our series as in other studies. Concomitant liver was involved in 10% cases as against 20 to 25% as mentioned in literature. (1-3)

The investigative profile of such patients is usually normal. Our series showed mild rise in absolute eosinophilic count, consistent with the literature. The Hydatid serology was positive in 30% patients only, such a investigation though widely sought of but cannot be relied upon. Chest x ray is first important investigation in pulmonary Hydatid disease. The regular outline of homogenous opacity is reliably suspicious of pulmonary Hydatid disease.



As the cyst ruptures the architecture and configuration of the cyst wall is lost and differential diagnosis widens on chest x ray. The superadded infection make it more hazy to label as Hydatid and sometimes it turns out to be lung abscess.

Ultrasound usually detects Hydatid fluid, scolices or daughter cysts especially if cyst is located near pleura. Deep seated cysts are missed on USG but complications like pleural effusion, rupture into pleural space, consolidation or lung abscess may be detected. <sup>(4)</sup>

Bronchoscopy detected intrabronchial rupture in three of our cases, but we do not have expertise or resources to have perbronchial removal of Hydatid cysts. It may not be ethically correct also to undertake such a procedure due to trans bronchial spread of scolices or allergic reactions during such a maneuver.

CT scan of the chest is the modality of choice for diagnosis of pulmonary Hydatid disease. The advantages being the exact localization of cysts, detection of number, site, density, architecture, daughter cysts, rupture, etc is precisely delineated. In addition it allows you to suspect underlying Hydatid cyst in lung abscess or consolidated lung. <sup>(5,6)</sup>

CT scan allows surgeon to have road map for detection and execution of surgical procedure without spillage of the contents. <sup>(7)</sup>

## CONCLUSION

Pulmonary hydatid disease continued to be health care related lung

infection in our community were sheep rearing and consumption of sheep meat is very high. CxR remains initial modality of investigation but CT chest is mandatory to differentiate between lung cancer, other cystic lesions of lung and hydatid disease. It also guides the surgeon for the precision of surgery and timely mitigation of complications like rupture, pleural effusion, or superadded cystic infection.

## REFERENCES

1. Vijayan, VK. How to diagnose and manage common parasitic pneumonias. *Curr Opin Pulm Med* 2007; 13:218.
2. Bhatia, G. Echinococcus. *Semin Respir Infect* 1997; 12:171.
3. Baden, LR, Elliott, DD. Case records of the Massachusetts General Hospital. Weekly Clinicopathological exercises. Case 4-2003. A 42-year-old woman with cough, fever, and abnormalities on thoracoabdominal computed tomography. *N Engl J Med* 2003; 348:447.
4. Pant, CS, Gupta, RK. Diagnostic value of ultrasonography in hydatid disease in abdomen and chest. *Acta Radiol* 1987; 28:743.
5. Kervancioglu, R, Bayram, M, Elbeyli, L. CT findings in pulmonary hydatid disease. *Acta Radiol* 1999; 40:510.
6. von Sinner, WN, Rifai, A, Te Strake, L, Sieck, J. Magnetic resonance imaging of thoracic hydatid disease. Correlation with clinical findings, radiography, ultrasonography, CT and pathology. *Acta Radiol* 1990; 31:59.
7. Koul P, Koul AN, Wahid A. CT appearances in pulmonary Hydatid disease. *Chest* 2000; 4(16); 154-9

How to cite this article: Koul AN, Bhat AW, Ahad R. Pulmonary hydatidosis, clinical facts, radiologic features and mitigation of parasitosis. *Int J Health Sci Res.* 2017; 7(2):64-67.

\*\*\*\*\*